

# Different Designs of Skin Closure of Spina Bifida Aperta: An Institutional Experience of Case Series

**Mohamed E Elsebaey, MD., Ahmed KA Elhady, MD., Alaa M Elkasrawy, MD., Mohamed Okasha, MD., Mohamed Abd Aziz Almlegi, MD., Wael M Elkholy, MD. Yasser M Elkhwaka, MD.**

*Neurosurgery Department, Damanhour Medical National Institute, Damanhour City, El Beheira, Egypt.*

## ABSTRACT

**Background Data:** Failure of closure of the caudal end of the neural tube is believed to be the embryological cause of spina bifida. Surgical repair is the ultimate solution and consists of multiple steps. Skin closure is the final and main step and is essential for a successful repair. We focused on different types of skin closure in the current study.

**Purpose:** To set predictive factors for selecting different types of skin closure in the closure of spina bifida aperta.

**Study Design:** A retrospective case study.

**Patients and Methods:** Between April 2016 and April 2017, 30 patients (16 males and 14 females) who underwent surgical intervention for spina bifida aperta were reported. Twenty-four patients (80%) had myelomeningocele, 3 patients (10%) meningocele, and 3 patients (10%) myeloschisis. The types of skin closure designs were recorded and evaluated. Moreover, the factors that can affect designing the skin closure presented in this study were reported and evaluated retrospectively.

**Results:** In this series, 60% (N = 18) of the patients underwent primary closure, 13.3% (N = 4) closure by using double transpositional skin flaps, and 26.6% (N = 8) skin closure using double rotational skin flaps.

**Conclusion:** The data of this study may suggest that, in patients with spina bifida aperta, selection of the primary direct skin closure and skin flap closure is a significant predictor of the final outcome. The presence of a pedicle and the size of the mass in relation to the back were significant outcome factors, while the shape of the defect was not a significant outcome factor. (2020ESJ207)

**Keywords:** Spina bifida aperta; Myelomeningocele; Meningocele; Myeloschisis; Neural tube defects; Skin flap

Address correspondence and reprint requests: Mohamed E Elsebaey, MD.

Neurosurgery Department, Damanhour Medical National Institute, Damanhour city, El Beheira, Egypt. - Email: mohamed.elsayed@med.suez.edu.eg

Submitted: January 13<sup>th</sup>, 2020.

Accepted: March 20<sup>th</sup>, 2020.

Published: April 2020.

The article does not contain information about medical device(s)/drug(s).

No funds were received in support of this work.

The authors report no conflict of interest.

## INTRODUCTION

Neural tube defects (NTDs) are the second most common type of human congenital anomalies.<sup>3</sup> Failure of the neurulation process during embryogenesis, 3-4 weeks after conception, causes NTDs, which is characterized by the absence of skin covering those defects. NTDs are classified into cranial and spinal. Spinal defects are classified into aperta and occulta according to the skin integrity covering the NTD.<sup>20</sup> Myelocele, meningocele, myelomeningocele, and myeloschisis are forms of the spina bifida aperta.<sup>10</sup> Skin is a complex organ and is comprised of epidermal, dermal, and subcutaneous layers.<sup>18</sup> It is responsible for protection, sensation, and thermoregulation. Closure of skin defects requires the usage of cutaneous flaps from the surrounding skin to produce an aesthetically pleasing result. Flap mobilization causes tissue stresses that may have a significant impact on the survival of the flaps. The presence of additional bony humps in the lumbosacral regions may add a lot of stress on the mobilized cutaneous flaps. The vascular anatomy of the skin is extraordinarily complex.<sup>18</sup> It receives contributions of highly interconnected vascular plexuses at differing levels within the architecture of the skin. There are 3 main regional conduits of blood flow to the skin: (1) musculocutaneous arteries, (2) direct cutaneous arteries, and (3) septocutaneous arteries. In more detail, the vascular plexal networks include dermal, subdermal, subcutaneous, prefascial, and subfascial networks. This redundancy of flow provides not only the thermoregulatory mechanism but also the nutrient flow allowing the flap survival and healing.<sup>22</sup> In 1587, Pieter Foreest was the first who described the NTDs.<sup>3</sup> In 2006, Sarry El-Din et al.<sup>23</sup> reported that the genetic clinic of the National Research Centre considered NTDs to be major congenital malformations in Egypt. The first surgical intervention for those abnormalities was in 1610 when Pieterszoon described those abnormalities as “spina bifida”

and mentioned that its treatment was dissection of the sac and ligation of its pedicle.<sup>2</sup> The main goal of surgical intervention is to achieve defect repair with avoiding the occurrence of any type of CNS infection. Adequate skin healing grants this goal; hence, it is important to discuss the designs of skin closure. Skin closure has different designs as it is dependent on some factors such as skin condition, size of the defect diameter, associated underlying vertebral anomalies, and status of dural closure.<sup>18</sup> This retrospective descriptive study aims to present our centre’s experience in the technique of skin closure among the spina bifida aperta patients and how to select the type of skin flap and design wound closure.

## PATIENTS AND METHODS

This study was conducted between April 2016 and April 2017 on infants who were operated upon for repair of spina bifida aperta in the Neurosurgery Department, Damanhour Medical National Institute, Damanhour, El Beheira, Egypt.

Thirty infants with spina bifida aperta including 16 males and 14 females with a mean age of 6 (range, 4–8) weeks were retrospectively recruited for this study. We reviewed our hospital medical records for cases that were operated on for spina bifida aperta during this period. We were able to trace 34 patients with this diagnosis who had a surgical repair. Only 30 infants of those 34 had full operative and pre- and postoperative clinical and radiological data. In this study, we included spina bifida patients with skin defects who were managed surgically and excluded infants who were referred to us with wound dehiscence following surgical repair outside our institution or those with incomplete data.

We regularly assessed the general condition of the patients (including lung, heart, and exclusion of any associated congenital anomaly) and the neurological status (level of consciousness, OFC (occipitofrontal circumference), anterior fontanelle, and lower limbs movement).

Additionally, we evaluated the spina bifida skin defect (size, shape, amount of healthy skin in the cyst, CSF leak, and presence of neural tissue). Radiological investigations were conducted including a spine X-ray, brain CT, and spine MRI to determine the plan of management of the defect and associated conditions (hydrocephalus, Chiari malformation, tethering of the spinal cord, kyphosis, or kyphoscoliosis).

The following items were evaluated to determine the type of skin closure: the shape of the defect, the presence of a meningocele pedicle; the ratio of the defect diameter to the surface diameter of the back.

#### **Statistical Analysis**

Analysis of the data was done using the Statistical Package for the Social Sciences (SPSS) program version 20. The Chi-square test was used for the analysis of nonparametric data and  $p < 0.05$  was considered to be significant.

#### **Surgical Technique**

The following steps were considered basic steps and were followed in all patients as follows.<sup>5</sup> (1) Marking was made along the margin of the healthy skin over the sac just parallel to the exposed placode as much as possible, and an incision was made along the marked margin in a steady meticulous fashion (Figures 1, 2, 3, and 5). (2) Meticulous trimming of the placode was conducted (Figure 2). (3) The placode was repositioned back into the spinal canal. (4) A combination of blunt and sharp dissection of the dura from the surrounding tissues was required. (5) Hemostasis was handled meticulously with attention to avoid traumatic or thermal injury to the neural elements. (6) Dura was closed into the midline and sutured in watertight fashion using 5-0 polypropylene (Figures 2 and 5). (7) In some cases, the lumbar fascia was used as a second layer to support the watertight closure of the dura (Figure 5). (8) Any skin particles were removed from the spinal cord to prevent the risk of developing inclusion dermoid. (9) Upward and downward lysis of any dural adhesions was done to relieve the spinal canal to avoid tethering. (10) Paraspinal muscles were dissected around

the laminar defect and fashioned to reinforce the closure (if required) followed by skin closure.

**Skin Closure.** We tailored the skin closure technique preoperatively for each patient so as to close the skin in primary fashion. (Figure 1, 2 and 3). In patients where the skin edges could not be well coapted primary well, we tried to perform transpositional flaps or rotational flaps for adequately coapted skin closure (Figures 4, 5, and 6).

## **RESULTS**

In our study, 80% (N = 24) patients had myelomeningocele, while 10% (N = 3) had meningocele and 10% (N = 3) had myeloschisis. Twelve patients presented with intact motor power of both lower limbs, while eighteen patients had motor deficits at different levels. Twenty-two patients had the back defect at the lumbar region, while 2 patients at the thoracic region, 3 patients at the thoracolumbar, and 3 patients at the sacral regions. The mean operative time was  $45 \pm 28$  (range, 40–50) minutes. The mean intraoperative blood loss was  $60 \pm 23$  (range, 40–80) ml. No added neurological deficits were recorded postoperatively.

Generally, according to the design of skin closure, 60% (N = 18) of the patients underwent primary closure. Primary skin closure was transversely or longitudinally. While 13.3% (N = 4) underwent skin closure by using double transpositional skin flaps, 26.6% (N = 8) underwent skin closure by using double rotational skin flaps. No CSF leak was observed in the postoperative follow-up. The wound healing was good in all patients, except in 3 cases. One patient died intraoperatively because of hypothermia, and two patients showed wound dehiscence in the central parts of the wound, one of these two had double transpositional skin flaps and the other one had a primary skin closure. Both infants with wound dehiscence were managed conservatively by daily topical dressing and antibiotics until optimum healing occurred.

The overall results of this study (as shown in Tables 1, 2, and 3) demonstrate that the following three factors were found to affect the accuracy and selection of the type of skin closure:

A) **The Shape of the Back Defect.** We found that 53.8% (N = 7) of the patients with oval-shaped back defect had undergone primary skin closure, while 64.6% (N = 11) of patients with round-shaped back defect had undergone skin closure using skin flaps. Thus, the surgical selection of the type of skin closure (primary direct skin closure versus skin flaps) is not significantly related to the shape of the back defect ( $p = 0.834$ ).

B) **The Presence of Pedicle.** We found that 68.3% (N = 13) of the patients with pedicled back swelling had undergone primary skin closure, while 54.5% (N = 6) with nonpedicled back swelling had undergone skin closure using skin flaps.  $p < 0.05$

was statistically significant. Therefore, the surgical selection of the type of skin closure (primary direct skin closure versus skin flaps) is significantly related to the presence of pedicle in back swellings ( $p = 0.018$ ).

C) **The Defect Diameter Relative to the Back Diameter.** We found that 57.1% (N = 12) of the patients whose defect's diameter was more than 50% of the back diameter had undergone skin closure using skin flaps, while 100% of patients whose defect's diameter was less than 50% of the back diameter had undergone primary skin closure;  $p < 0.05$  was statistically significant. Thus, the surgical selection of the type of skin closure (primary direct skin closure versus skin flaps) is significantly related to defect diameter relative to the back diameter ( $p = 0.014$ ).

**Table 1.** Types of skin closure according to the shape of the back defect.

Parameters	Oval	Round	Total	X <sup>2</sup>	p value
Primary direct skin closure	7 (53.8%)	11 (64.7%)	18 (60%)	0.362	0.834
Double transpositional flap	2 (15.4%)	2 (11.8%)	4 (13.3%)		
Double rotational flap	4 (30.7%)	4 (23.5%)	8 (26.7%)		
Total	13 (100%)	17 (100%)	30 (100%)		

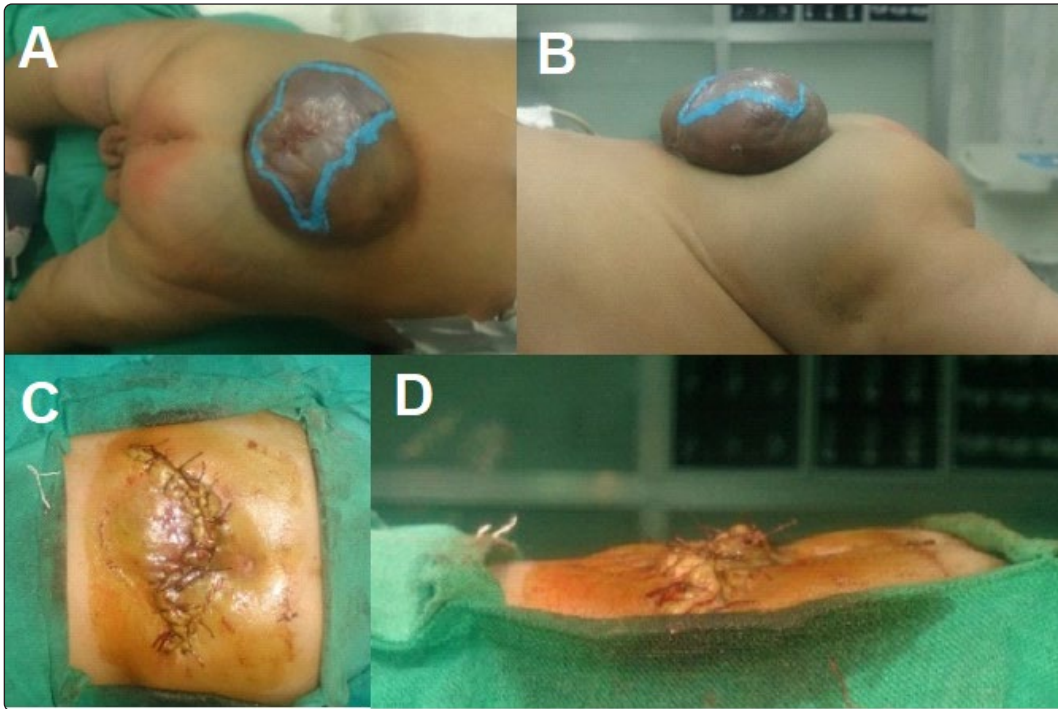
**Table 2.** Types of skin closure according to the presence of pedicle of back swelling.

Parameters	With pedicle	Nonpedicled	Total	X <sup>2</sup>	p value
Primary direct skin closure	13 (68.4%)	5 (45.5%)	18 (60%)	7.986	0.018*
Double transpositional flap	4 (21.1%)	0 (0%)	4 (13.3%)		
Double rotational flap	2 (10.5%)	6 (54.5%)	8 (26.7%)		
Total	19 (100%)	11 (100%)	30 (100%)		

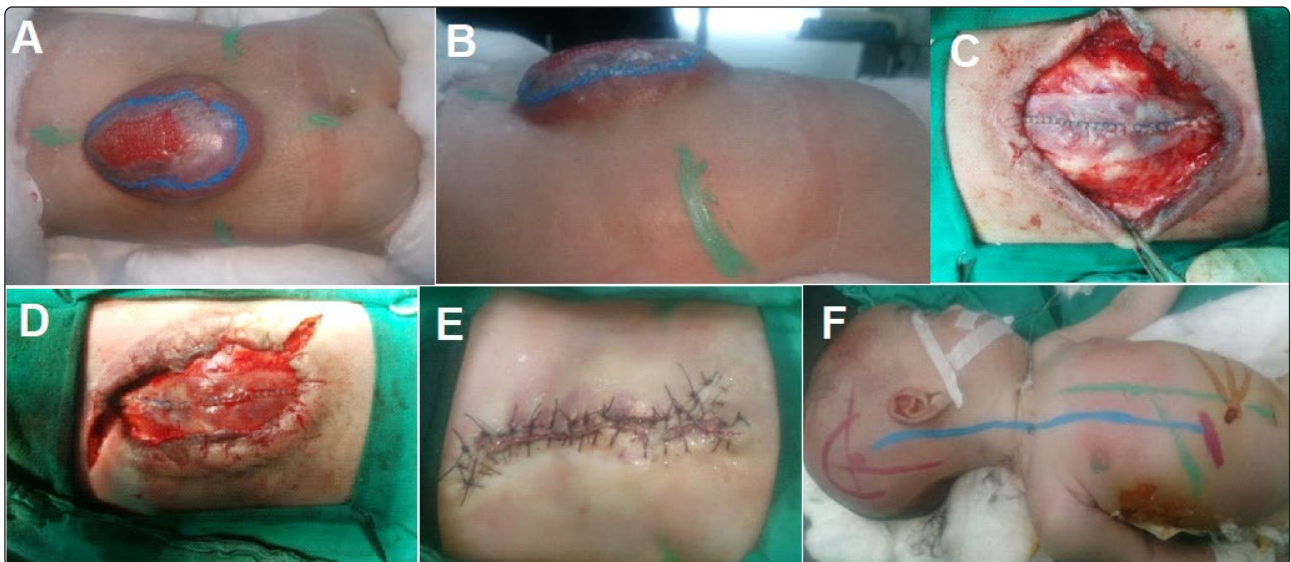
**Table 3.** Types of skin closure according to the percentage between the largest diameter of the defect and the transverse back diameter.

Parameters	More than 50%	Less than 50%	Total	X <sup>2</sup>	p value
Primary direct skin closure	9 (43%)	9 (100%)	18 (60%)	8.573	0.014*
Double transpositional flap	4 (19%)	0 (0%)	4 (13.3%)		
Double rotational flap	8 (38%)	0 (0%)	8 (26.7%)		
Total	21 (100%)	9 (100%)	30 (100%)		

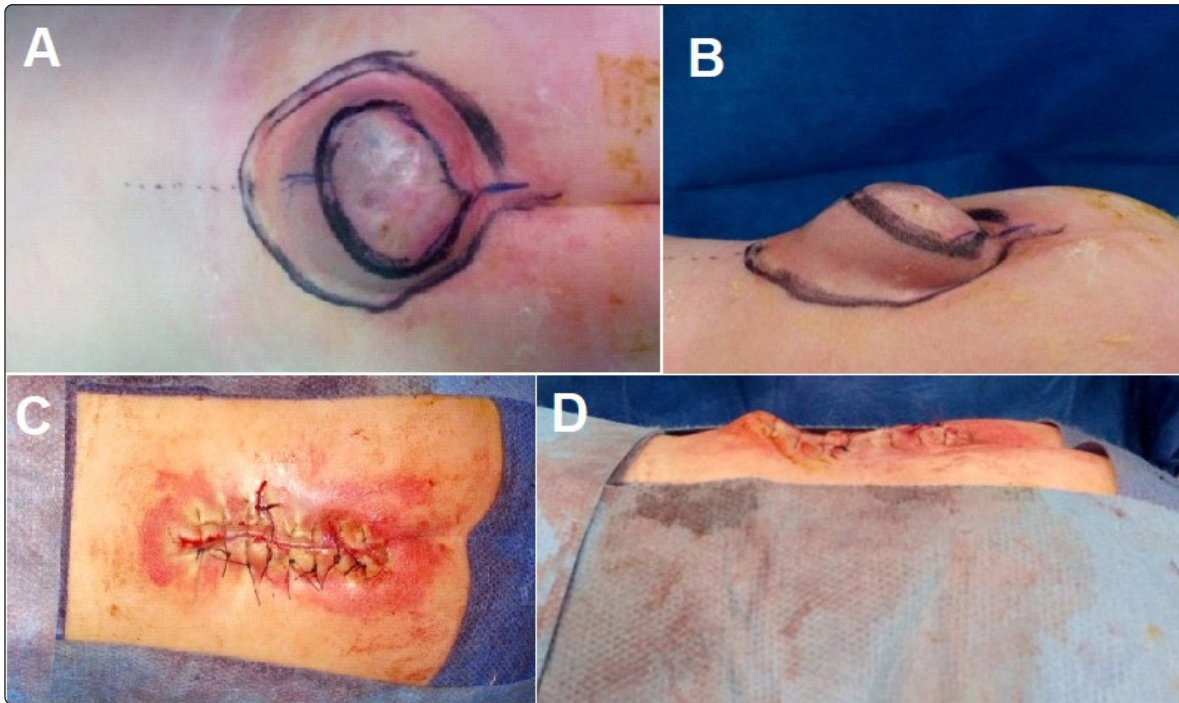




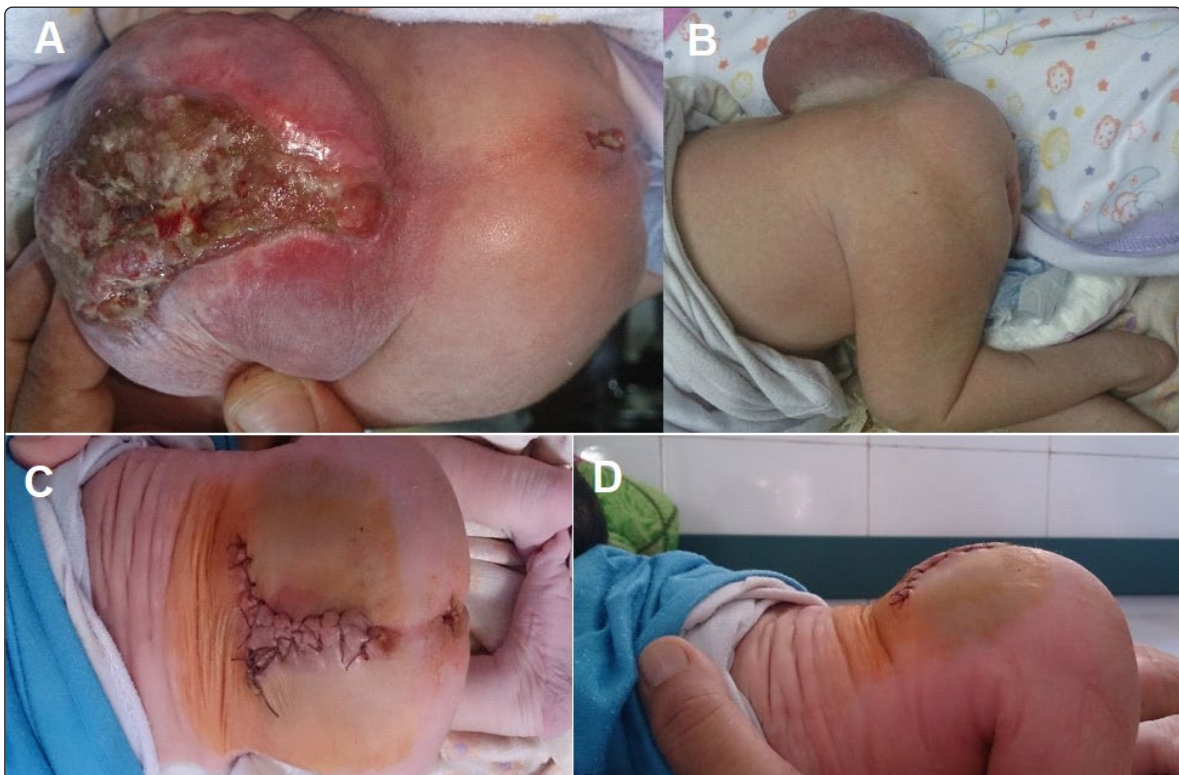
**Figure 1.** Intraoperative views of large lumbar myelomeningocele. (A, B) Overhead and lateral views showing preoperative marking over margins of the placode and boundaries of healthy skin covering. (C, D) Overhead and lateral views showing primary direct closure of the skin defect in the transverse direction.



**Figure 2.** Intraoperative views of thoracolumbar myelomeningocele. (A) Overhead view showing the relative diameter between the back defect (dotted line) and the back diameter (arrows). (B) Lateral view showing preoperative incision marking. (C) Intraoperative view showing the watertight continuous closure of the dura. (D) Performing primary direct longitudinal skin closure with lazy-S design. (E) Postoperative view showing closure of the skin. (F) Markings and preparation for VP shunt insertion at the same session.

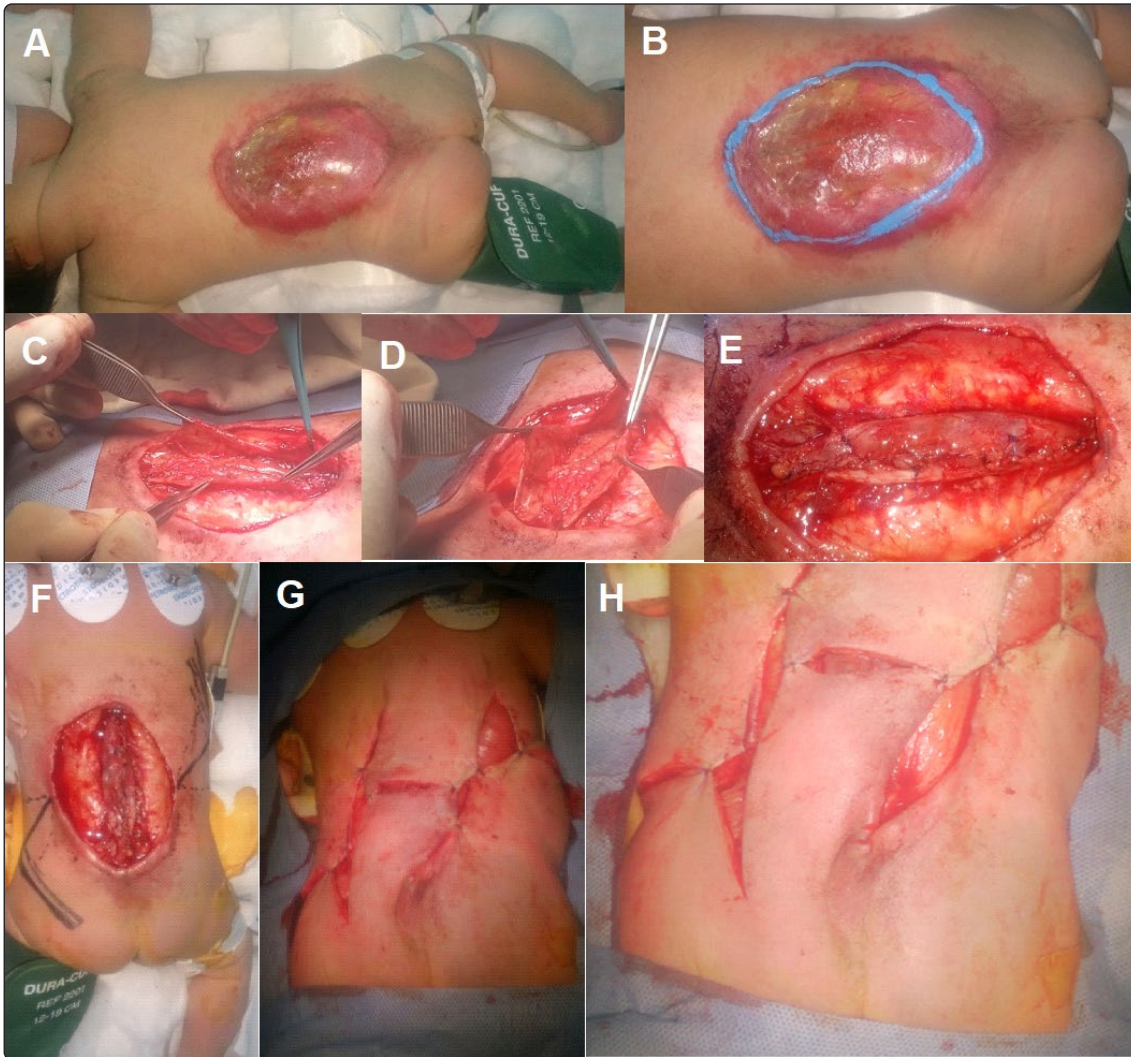


**Figure 3.** Intraoperative views of lumbar meningocele. (A, B) Overhead and lateral views showing preoperative marking over margins of the placode and periphery of the hyperpigmented skin. (C, D) Overhead and lateral views showing postoperative primary direct longitudinal skin closure.

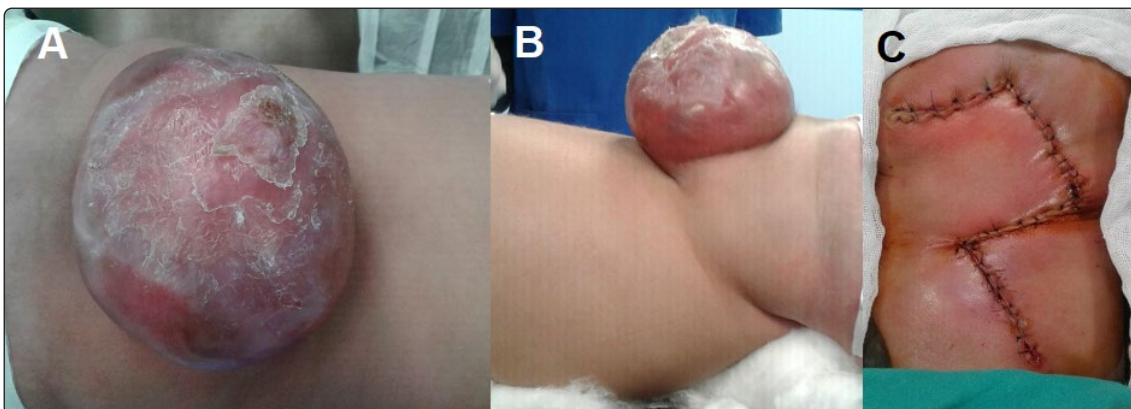

**Figure 4.** Intraoperative views of large ruptured lumbosacral myelomeningocele. (A, B) Overhead and lateral views showing a preoperative large myelomeningocele with an unhealthy placode. (C, D) Overhead and lateral views showing postoperative skin closure in bilateral transposed skin flap design.





**Figure 5.** Intraoperative views of large leaking myeloschisis. (A, B) Overhead views showing the preoperative large back defect. (C, D) The dural edges after complete dissection were ready for repair. (E) Closure of the dura in a watertight fashion. (F) Plastic surgeons marked the skin in black color lines for the preparation of harvesting flaps. (G, H) Covering the back defect using the bilateral rotational flaps.



**Figure 6.** Intraoperative views of large meningocele. (A) Overhead and (B) lateral views showing a preoperative large back swelling with big skin defect. (C) Covering the back defect using the bilateral rotational flaps.

## DISCUSSION

Management of spina bifida aperta is concerned with preserving the existing neurological status and preventing further expected neurological complications.<sup>4</sup> Surgical closure of the back defect within the first 24–48 hours after birth is the basic rule.<sup>16</sup> In this study, all patients underwent surgery after 4 weeks because of some factors (ignorance of some parents, associated medical insults in the cardiopulmonary system and blood coagulation, and the availability of postoperative incubators). Avoiding CSF leak and CNS infection and further neurological affection are the main points in the perioperative period.<sup>5</sup> Lateral recumbent position and daily dressing with saline and moistened gauze and using latex-free gloves are recommended to avoid rupture of the cyst roof and preservation of the neuronal elements and the healthy skin. Surgical procedures for repair of the spina bifida aperta are numerous and different techniques are advocated by different authors in the literature.<sup>17</sup> Most of the literature data are concerned with the different surgical procedures in the repair of the spina bifida defect including the neural elements, dura, sac, muscles, fascia, and skin.<sup>15</sup> In the present study, the skin closure is discussed: plastic surgeons preferred the complex rotational skin flaps, while neurosurgeons preferred the simple procedures even when using rotational skin flaps.<sup>8</sup> The physiologic changes that occur within the skin and the surrounding soft tissue during flap elevation are as follows: the significant reduction in blood flow to the involved skin because of the partial transection of the vascular supply, sympathetic denervation, local inflammatory changes, and neovascularization of the flap within its recipient bed.<sup>18,22</sup> When a cutaneous flap is elevated, a vascular compromise could occur due to the interruption of the most direct blood flow to that segment of the skin.<sup>18</sup> The long distance from the base of the flap and disruption of the blood flow also cause a drop in the perfusion pressure of the involved

skin. Once the perfusion pressure falls below the critical closing pressures of the arterioles within the dermal-subdermal plexus, nutrient flow to the distal tissues stops causing necrosis of the distal portion of the flap.<sup>18</sup> The vascular delay phenomenon, when a portion of the vascular supply of the flap is divided before elevation and transfer, results in improved viability and survival of the skin flaps.<sup>18</sup> Flap creation causes sympathetic skin denervation. Loss of sympathetic tone causes loss of the vasoconstrictive substances and the axial reorientation and dilation of the vascular channels within the flap.<sup>18</sup> This loss of the sympathetic tone causes vasodilation of the vascular networks supplying the created flap. This rebound vasodilation after the sympathectomy is one of the mechanisms thought to enhance the flap viability.<sup>18</sup>

When a skin flap is elevated, an inflammatory response is enhanced. This response is mediated by extracellular mediators such as histamine, serotonin, and kinins. These mediators cause an increase in microvascular permeability. Thus, inflammation has positive effects on the overall viability of the cutaneous flaps.<sup>18,22</sup>

Before the surgery, we used the following criteria to predict the type of skin closure: the shape of the back swelling (round or oval), pedicled back swelling or not, and the ratio between the horizontal diameter of the defect to the horizontal surface of the back (less or more than 50%). Planning the expected design for skin closure was done before the start of surgery. Primary simple direct closure after fusiform skin incision was used in small skin defects. The exploration into the neck of the pedicle was the direct way of identifying the spinal defect.<sup>11</sup> We reported two patients who showed wound ischemia; both underwent daily dressing twice and showed complete wound healing later on. Close observation was mandatory for the possibility of occurrence of CSF leak from the wound and/or occurrence of hydrocephalus till achieving complete healing of the back wound. Several studies described different designs of skin flap closure in infants with spina bifida. In 1979,



Ohtsuka et al.<sup>21</sup> described modified Limberg type repair flap in round and oval moderate-to-large lumbosacral defects. In 1983, Cruz et al.<sup>9</sup> reported the concept of using double-Z rhomboid flaps in repairing large myelomeningoceles. In 1983, WR Cheek<sup>8</sup> demonstrated a surgical procedure based on the identification of the junctional zone and mobilizing the skin and subcutaneous tissue from the lumbar fascia. Tension sutures and relaxing incisions were used to approximate the skin edges. In 1991, Hayashi et al.<sup>13</sup> reported using bilateral latissimus dorsi musculocutaneous flaps for repairing large myelomeningocele. They advocated that this improved blood supply to the flap, provided adequate soft tissue pad over the dura, and promoted more healing. In 1993, Lanigan<sup>17</sup> suggested that the skin closure should be conducted in the following order: primary closure, wide undermining of the skin, cutaneous flaps (Limberg flap), cutaneous flaps with split skin grafting, transposed muscle flaps, musculocutaneous flaps with split skin grafting, and bone and muscle flaps. In 1994, McCullough's<sup>19</sup> skin closure procedure was as follows: primary simple closure after undermining the skin from the lumbodorsal fascia and in a cephalad caudal fashion, then closure with the aid of relaxing incisions, rotational flaps, myocutaneous flaps, skin flaps, tension prosthesis, primary kyphectomy, and osteotomy if needed. In 1996, Fiala et al.<sup>12</sup> reported the subjective estimation of skin closure. After marking an elliptical-shaped incision around the sac and at the end of the repair, the skin edges are held by toothed forceps, and the base of the skin flaps is stitched with heavy silk approximating sutures, and finally, tension sutures might be needed or even skin grafts added in case of skin shortage. In 2004, Campobasso et al.<sup>7</sup> suggested that skin closure using the Limberg flaps had advantages in patients with large round or oval lumbosacral myelomeningoceles offering a minimally invasive approach, shorter hospitalization time, and a better cosmetic shape. They advocated that avoidance

of usage of back muscles have two merits: first is maintaining trunk posture in better building and strength and second allowing effective urinary bladder emptying during the Valsalva maneuver.<sup>4</sup> In 2012, Khaled Ali<sup>1</sup> published and described in situ skin tailoring for myelomeningocele repair. He preferred to postpone the skin trimming until the skin edges are opposed at the end of the procedure and minimal undermining was used if needed for primary direct repair. Thus, skin shortage, skin grafting, and skin undercutting were not required. In this study, we tried to perform primary skin closure in all patients because it is a simple, familial, and less time-consuming procedure where there is less blood loss. If skin edges were not coapted well, the plastic surgeon performed either transpositional or rotational skin flaps for adequate skin closure. From our results, we concluded that selecting the primary direct skin closure in the patients with spina bifida aperta was significantly related to the presence of a pedicle of the mass and a defect diameter of less than 50% relative to the back diameter. This study has some limitations which may affect the generalization of the results and mandate further future studies. Association with other congenital anomalies, the relation between wound closure and CSF diversion device, skin closure in relation to prominence of sacrum, and skin closure in relation to each age group were not included in the study.

## CONCLUSION

The data of this study may suggest that, in patients with spina bifida aperta, selection of the primary direct skin closure and skin flap closure are significant predictors of the final outcome. The presence of a pedicle and the size of the mass in relation to the back were significant outcome factors, while the shape of the defect was not a significant outcome factor.

## REFERENCES

1. Ali KB: In situ tailoring for myelomeningocele repair. *Egy Spine J* 1:65–68, 2012
2. Ali S, Azeemi AA, Shoukat S: The prevalence of spina bifida occulta in Pakistani population: a study of dry human sacra. *Anaesth, Pain and Intensive Care* 18:157–161, 2014
3. Al-Gazali L, Hamamy H, Al-Arrayad S: Genetic disorders in the Arab world. *BMJ* 333:831–834, 2006
4. Al-Hazmi HH, Trbay MS, Gomba A, Elderwy AA, Khatab AJ, Neel KF: Urological outcomes of patients with neural tube defects. *Saudi Med J* 35:S64–S67, 2014
5. Bao N, Lazareff J: How I do it: management of spina bifida in a hospital in the People's Republic of China. *Surg Neurol Int* 6:337–345, 2015
6. Bowman RM, McLone DG: Neurosurgical management of spina bifida: research issues. *Dev Disabil Res Rev* 16:82–87, 2010
7. Campobasso P, Pesce C, Costa L, Cimaglia ML: The use of the limberg skin flap for closure of large lumbosacral myelomeningoceles. *Pediatr Surg Int* 20:144–147, 2004
8. Cheek WR, Laurent JP, Cech DA: Operative repair of lumbosacral myelomeningocele. *J Neurosurgery*. 59:718–722, 1983
9. Cruz NI, Ariyan S, Duncan CC, Cuono CB: Repair of lumbosacral myelomeningoceles with double Z-rhomboid flaps. Technical note. *J Neurosurg* 59:714–717, 1983
10. Dicianno BE, Karmarkar A, Houtrow A, Crytzer TM, Cushman KM, McCoy A, et al: Factors associated with mobility outcomes in a national spina bifida patient registry. *Am J Phys Med Rehabil*, 94(12):1015–1025, 2015
11. Emsen IM: Closure of large myelomeningocele defects using the O-S flap technique. *Journal of Craniofacial Surgery* 26(7):2167–2170, 2015
12. Fiala TGS, Buchman SR, Muraszko KM: Use of lumbar periosteal turnover flaps in myelomeningocele closure. *Neurosurgery* 39:522–525, 1996
13. Hayashi A, Maruyama Y: Bilateral latissimus dorsi VY musculocutaneous flap for closure of a large meningomyelocele. *Plast Reconstr Surg* 88:520–522, 1991
14. Januschek E, Rohrig A, Kunze S, Fremerey C, Wiebe B, Junger MM: Myelomeningocele—a single institute analysis of the years 2007 to 2015. *Childs Nerv Syst* 32:1281–1287, 2016
15. Johnson MP, Bennett KA, Rand L, Burrows PK, Thom EA, Howell, et al: The management of myelomeningocele study: obstetrical outcomes and risk factors for obstetrical complications following prenatal surgery. *Am Obstet Gynecol* 215(6):778.E1–778.E9, 2016
16. Kural C, Solmaz I, Tehli O, Temiz C, Kutlay M, Daneyemez MK, et al: Evaluation and management of lumbosacral myelomeningoceles in children. *Eurasian J Med* 47:174–178, 2015
17. Lanigan MW: Surgical repair of myelomeningocele. *Ann Plast Surg* 31:514–521, 1993
18. Lucas JB: The physiology and biomechanics of skin flaps. *Facial Plast Surg Clin N Am* 25(3):303–311, 2017
19. McCullough DC, Johnson DL: Myelomeningocele repair: technical considerations and complications. *Pediatr Neurosurg* 21:83–90, 1994
20. Nauman N, Jalali SS, Aslamshami S, Akhtar N: Consanguinity and neural tube defects. *Journal of Rawalpindi Medical college* 20:120–123, 2016
21. Ohtsuka H, Shioya N, Yada K: Modified limberg flap for lumbosacral meningomyelocele defects. *Ann Plast Surg* 3:114–117, 1979

22. Pearl RM, Johnson D: The vascular supply to the skin: an anatomical and physiological reappraisal. Annals of Plastic Surgery.11(3):196–205, 1983

23. Sarry El-Din AM, Elbanna RA: Congenital anomalies of the vertebral column: A case study on ancient and modern Egypt. Int. J. Osteoarchaeol. 16:200–207, 2006

## الملخص العربى

**التصميمات المختلفة لاغلاق الجلد لمرضى فتق العمود الفقرى المفتوح: خبرة معهدية لحالات متعددة.**  
**البيانات الخلفية:** مرض فتق العمود الفقرى من أكثر أمراض العمود الفقرى شيوعا منذ زمن طويل. و تفسره النظريات العلمية بسبب خلل فى النطور الجنينى للقناة العصبية. توجد أشكال كثيرة منه مثل الفتق المغلق والفتق المفتوح و الفتق المصاحب للقيلة المائية. نسبة كثيرة من تلك الأنواع تكون مصاحبة لعيوب خلقية اخرى فى الجهاز العصبى (من أبرزها وجود استسقاء بالمخ, خذل أو فقدان للقوة الحركية بالطرفين السفليين), وبالأجهزة الأخرى مثل أمراض بالقلب وأشهرها ثقبوب بجدران القلب.

**الغرض:** وضع معايير تمكن الطاقم الجراحى اختيار التصميم المناسب لاغلاق الجلد لحالات فتق العمود الفقرى المفتوح

**نوع الدراسة:** وصفية تراجعية

**المرضى و الطرق:** الدراسة تمت لعدد ثلاثين مريض ما بين فترة أبريل 2016 الى أبريل 2017 فى المعهد الطبى القومى بدمنهوور بمحافظة البحيرة. و كل الحالات تم لها العلاج الجراحى مع اخذ البيانات بالتفصيل من الأبوين ومرجعتها وتقييمها.

**النتائج:** شملت الدراسة ست عشر ذكرا و اربعة عشر أنثى. كل الحالات تم لها جراحة اصلاح العيب الخلقى بالعمود الفقرى و تم استخدام تصميمات مختلفة لاغلاق الجلد مثل الغلق المباشر للجلد أو استخدام نقل لنسيج الجلد لغلق الفتق.

**الاستنتاج:** الدراسة تقدم بيانات ومعايير لكيفية اختيار التصميم المناسب مثل (شكل الفتق, الفتق مصاحب لعنق أم لا, قطر الفتق بالنسبة الى قطر الظهر) لاغلاق الجلد لمرضى فتق العمود الفقرى المفتوح كخطوة من ضمن الخطوات العديدة فى الاسلوب الجراحى لاصلاح الفتق ككل.