

Results of Surgical Fixation of Occipitocervical Instability Using Polyaxial Plate/Rod System. Report of 14 Cases.

Mohamed Sawan, Ashraf Moharam

Neurosurgery department, Orthopedic department, Cairo University, Cairo

Abstract

Background Data: Occipitocervical junction instability has always been a challenging surgical problem owing to the unique anatomical and biomechanical characteristics of this region.

Purpose: To detect the safety, efficacy and related complications using polyaxial screw-based constructs with rod / plate system for occipitocervical instability.

Study design: This is a retrospective study for 14 patients underwent occipitocervical fusion for instability using polyaxial screw-based constructs with rod / plate system during the period from January 2007 to September 2011 in Cairo University Hospitals and Nasser Institute Hospital.

Methods: Our study reviewed the surgical technique, the variety of instrumentation, the postoperative outcome, various complications and fusion rates related to this technique.

Results: The 14 patients were 8 males and 6 females with a mean age of 44.9 years. Patients were operated upon with an average operative time of 91 minutes, and with average blood loss of 660 ml. The mean number of levels fused was 3.3 levels. The mean follow up period was 18 months. Clinical improvement occurred in 12 patients. Stability was evident in all the cases (100%), however bony fusion was reported in 12 patients (86%). Post operatively one case had infection at the operative bed which improved after 2 months.

Conclusion: Surgical fusion and fixation of the occipitocervical junction using the new instrumentation system inspite technically demanding have proven clinical success and high fusion rate as well as biomechanical stability, with a very low rate of complications related to this procedure.

(2012ESJ004)

Key Words: Fusion, Instability, Instrumentation, Occipitocervical.

Introduction

Occipitocervical instability is a rare condition that may be traumatic or non-traumatic in origin⁵ Instability at the occipitocervical junction can lead to severe neurological morbidity or mortality if left untreated.¹⁵ The unique anatomy and function of the region, the perceived high risk of vascular and neurological complications, and the anatomical variations make occipitocervical fusion a challenging procedure.²² The goals of internal

fixation are to achieve anatomic alignment, to protect the neural elements, to stabilize the spine while preserving the motion of normal elements and to produce a "functional decompression".⁹ In the recent years, the evolution of new fixation constructs meeting the difficulties in surgical anatomy of the occipitocervical junction has markedly increased the surgical success rates. The new polyaxial screw heads facilitates rod / plate system attachment. We retrospectively reviewed 14 patients underwent occipitocervical

fusion for instability using polyaxial screw-based constructs with rod / plate system during the period from January 2007 to August 2011 in Cairo University Hospital evaluating the clinical outcome, complications, and fusion rate.

Materials and methods

During the period from January 2007 to September 2011, 14 patients underwent occipitocervical fusion for instability using screw-based constructs with rod / plate system in Cairo University Hospital and Nasser

Institute Hospital. We retrospectively reviewed the data collection including the medical records, office notes, radiological investigations (during hospital stay and follow up periods), and operative notes for the 14 patients. They were 8 males and 6 females. The age at the time of operation ranged (from 19-66 years) with a mean age of 44.3 years. The follow up period had a mean of 18 months, and ranged (from 7-32 months). The Instability of the occipitocervical junction in our study resulted from different causes as shown in Table (1).

No.	Age/ Sex	Pathology	Operation	Follow-up/ mo
1	43/M	Basilar impression/ spinal compression	Posterior decompression with occipito-cervical (0-3) arthrodesis and fixation	32
2	19/F	Traumatic atlanto-occipital dissociation with dens fracture	Open reduction with occipito-cervical (0-3) arthrodesis and fixation	24
3	51/M	Traumatic atlanto-occipital dissociation	Occipito-cervical (0-2) arthrodesis and fixation	12
4	46/M	Traumatic atlanto-occipital dissociation with fracture of CC2 TV process, posterior arch of CV1	Occipito-cervical (0-3) arthrodesis and fixation	17
5	54/F	Traumatic Hangman fracture	Occipito-cervical (0-2) arthrodesis and fixation	24
6	42/M	Neurofibromatosis with dysplastic CV1, CV2 and CV1/2 subluxation	Occipito-cervical (0, 3-4) arthrodesis and fixation with allograft	12
7	66/M	Rheumatoid arthritis with atlanto-axial subluxation and atlanto-occipital joint destruction	Occipito-cervical (0-4) arthrodesis and fixation with allograft	18
8	52/F	Traumatic Jefferson fracture	Occipito-cervical (0, 2-3) arthrodesis and fixation with iliac graft	16
9	47/M	Traumatic atlanto-occipital dislocation	Occipito-cervical (0, 2-4) arthrodesis and fixation with iliac graft	11
10	61/F	traumatic atlanto-occipital dislocation	Occipito-cervical (0-2) arthrodesis and fixation with iliac graft	14
11	53/M	Traumatic atlanto-occipital dislocation	Occipito-cervical (0-2) arthrodesis and fixation with allograft	28
12	37/F	Osodontadium with atlantoaxial subluxation and bifid posterior arch CV1	Occipito-cervical (0, 2-4) arthrodesis and fixation with allograft	22
13	22/M	Traumatic Hangman fracture	Occipito-cervical (0, 2-3) arthrodesis and fixation with iliac graft	7
14	28/F	Rheumatoid arthritis with atlanto-axial subluxation and atlanto-occipital joint destruction	Occipito-cervical (0-1) arthrodesis and fixation with allograft	15

Table 1. Data of our 14 cases showing distribution of (sex, age, underlying cause, pathology, operation done, levels involved, follow up period) among the patients.

Clinical assessment:

All the patients preoperatively underwent a full neurological examination, and were graded before and after the surgery according to the Frankel grading system.¹¹ The distribution of patients among the Frankel grading system can be shown in table 2. The presenting symptoms for the patients preoperatively included neck pain, occipital headaches, torticollis, parasthesias, weakness and

dysphagia, Figure (1). Patients were assessed using Frankel grading system at discharge, after 1 month and 6 months postoperatively in the outpatient clinic. As a routine we did clinical assessment till the most recent follow up visit. All patients had severe pain preoperatively measured using Visual Analogue Pain scale (VAS) with an average score preoperatively of 9.

Frankel Grade	Number of patients
Frankel A	0
Frankel B	1
Frankel C	2
Frankel D	1
Frankel E	10

Table 2. Preoperative clinical scoring on Frankel grading system.

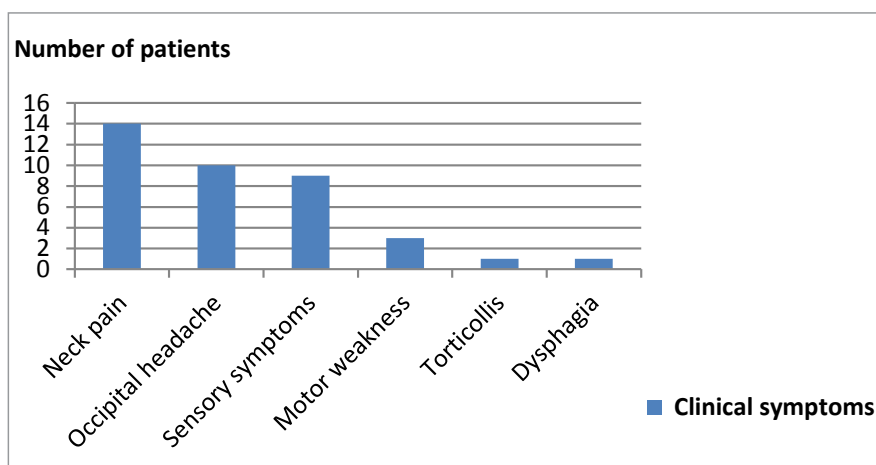


Figure 1. The distribution of presenting symptoms among the 14 patients.

Radiological assessment:

All patients underwent preoperative radiological assessment including: A) X-ray (lateral cervical spine views, dynamic views and open mouth views). B) CT scan fine-cuts 2mm high-resolution with coronal and sagittal reconstructions incorporating the craniovertebral junction and the entire cervical spine using a helical scanning protocol. Special attention was paid to the anatomical course of the vertebral arteries and the thickness of the keel of the occipital bone. C) MRI of the occipitocervical region and the entire cervical spine. The dynamic views (lateral views–flexion/extension) were avoided only in severely traumatized patients to avoid further neurological deterioration. The presence of shift by 3 mm or more in the atlantodental

interval was diagnostic of instability on performing dynamic X-ray. The presence of pathological movement with a neurological deficit denoted instability. X-rays (Anteroposterior-lateral views with flexion/ extension–lateral flexion-rotation) were performed immediately after surgery and at (3, 6 months postoperatively) on follow up visits. CT scan was done at least once in the postoperative period to evaluate the screws position and the fusion rate evidenced by absence of pathological movement between the fused vertebral motion segments, and by the presence of fusion mass between the graft and bone on dynamic cervical X-ray radiography. For assessment of the range of motion, lateral photographs were obtained while the patient standing upright and maximally

flexing and extending their neck. All photographs were obtained by the same person using the same camera and included the same vertical reference (door edge). Pictures were obtained preoperatively and repeated immediately after surgery and at 3, 6 months postoperatively. All images were scanned into a computer and the patient's range of motion was assessed by summing the extent to which they could flex and extend their heads relative to a vertical line. The range of movement preoperatively ranged from 30 to 60 degrees (flexion / extension), 25 to 30 degrees (rotation). 20 to 25 degrees (lateral flexion).

Treatment Plan:

Many contributing factors were considered prior to decision of the best treatment plan for the patient including:

- A) Patient's general medical status.
- B) Neurological status.
- C) Nature, severity and location of the pathology (nature of pathology in table 1).
- D) Degree of instability.
- E) Presence or absence of spinal cord compression (anterior or posterior).

Indications for Surgery:

The indication for surgical intervention in the study was the presence of radiological evidence of instability of the occipitocervical junction. All the patients in our study had no anterior compression of the spinal cord as evidenced preoperatively on MRI films and hence there was no need for anterior approach to decompress the spinal cord. All the patients had a posterior surgical approach. In 5 cases (one case with metastatic tumor and 4 case of motor vehicle access MVA trauma) the spinal cord was posteriorly compressed, the posterior decompression was done with the fusion procedure at the same surgery

Surgical technique:

The patients were positioned prone in a Mayfield pin headrest, while care is taken to avoid overdistracted of occipitocervical junction. Under umbrella of antibiotics given 45 minutes preoperatively, the hair is shaved around the planned skin incision site, from the external occipital protuberance down to the hairline. Intraoperative fluoroscopy was used to detect the exact targeted level, and to make sure there is good vertebral alignment in the neutral position, and in 9 cases the patients needed reduction using Gardner Wells skull traction tongs to reach proper alignment. The skin is marked, infiltrated with (1%)

lidocaine mixed with epinephrine (1:100 000) to aid in hemostasis Skin is opened sharply, dissection of the subcutaneous tissues from the underlying fascial layer, to facilitate later proper fascial closure after having the procedure done. The fascia is opened by monopolar, the paraspinal muscles is then dissected from the midline following the avascular raphe until the spinous processes and laminae are exposed to the lateral borders of the lateral masses, and from occiput in the midline to the medial edge of the mastoids laterally. Extreme care is taken while performing bipolar and sharp dissection to avoid vertebral artery injury. Soft tissues are dissected carefully between CV1 and the occiput again with having a clear imagination of the anatomical course of the vertebral artery to avoid the risk of injury, as well as around the edge of the foramen magnum. The soft tissues between CV1 and CV2 are removed with a similar technique. Blunt dissectors and curettes are used to separate the ligamentum flavum from its bony attachments. The dura is then identified. Venous bleeding encountered can be easily controlled with Gelfoam and gentle compression. In cases when CV2 is to be involved in the fixation, the CV2 pars have to be carefully exposed. In cases when CV1 is to be involved in the fixation, we start by identification of the medial surface of the CV1 lamina, and with the aid of dissectors and curettes, we reach ventrally to the CV1 lateral mass. All the screws were inserted under the aid of X-ray image intensifier in lateral projection. The screws entry points are marked. When Cv1, or CV2 or both had to be involved in the fixation, we preferred to place CV1 lateral mass and CV2 pedicle screws. For CV1 lateral mass screw, a pilot hole reaching through the anterior cortical bone, was made with a 2.5 mm drill, followed by either a straight or slightly convergent trajectory in an anterior-posterior direction parallel to the plane of the posterior arch of CV1 in the sagittal plane. A 3.5 mm thickness polyaxial heads screws, were inserted into the lateral mass of CV1. The entry point for CV2 pedicle screw was first marked with an awl at specific point of intersection (2 mm from the medial border and 5 mm from the caudal border of the C2 articular process). Under an X-ray imaging in lateral projection, a hole was drilled at an angle of 20 to 30 degrees cranially, up to and through the anterior cortical bone. The screws were inserted in a convergent direction at an angle of 20 to 25 degrees. We used pedicle screws in the cervical levels involved below the level of CV2. The

occipital bone screw site is preferred to be close to the midline to gain benefit of the anatomical depth of the occiput in the midline and eventually a stronger contact between the occipital bone and the occipital screws. The anatomical irregularities in the occipital bone in the area of the plate to be placed are smoothed by a high speed drill. The plate is placed firmly, followed by placement of 4.5-mm-diameter blunt cortical screws of a length matching the entire length of the tapped holes. Rods are then fashioned to adapt fitly in both the screw heads either for CV1 lateral mass or cervical vertebrae pedicles in the lower levels (figure 2). Intraoperative C-Arm imaging at the end of the screws insertion was taken to verify the screws trajectories was properly done. The key principle

is that the internal fixation only functions as an internal splint while the bone graft incorporates. We used either harvested tricortical iliac crest bone graft or tricortical fibular graft for all cases. Grafts are fashioned to fit precisely with the original bone after all contact points between the graft and the original bone are being decorticated by a high speed burr. The wound is then inspected for any cerebrospinal fluid leakage, or any bleeding point. Proper hemostasis and wound irrigation with antibiotics. Muscles are closed in layers followed by closure of the fascia tightly with (Vicryl 1) suture. Subcutaneous layer and skin are then closed. Drain is left under the fascia as a routine in all the cases. Patients were instructed to have a hard cervical collar worn for 3 months postoperatively.

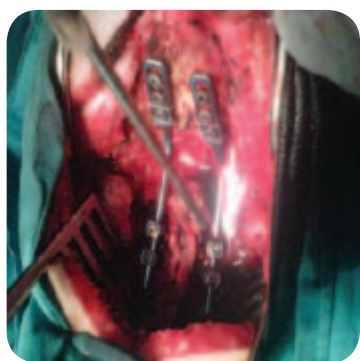

Figure 2. Intraoperative picture showing application of the construct (vertex system-occiput-CV2-CV3). Note the capacious space for bone graft application.

Results

Twenty-two patients underwent posterior occipitocervical fusion. There were 8 males (57%) and 6 females (43%). The age ranged (from 19-66 years) with a mean age of 44.3 years. Operative time ranged from (55-155 minutes), with an average of (91 minutes). Intra-operative blood loss ranged from (50-1600 ml.), with an average of (660 ml.). The intraoperative X-ray image intensifier was used for a period of (0.6-3.2 minutes), with an average of (1.1 minute). The patients were followed up for a period ranging from (7-31 months) with a mean of (18 months). Preoperatively neck pain was present

in all the 14 cases (100%), occipital headache occurred in 10 patients (71%), sensory symptoms occurred in 9 patients (64%), and myelopathy occurred in 3 patients (21%). Neck pain improved in all the patients (100%) postoperatively by at least 3 points on the Visual Analogue Scale for pain, Figure (3). The occipital headache improved in 9 patients (90%) postoperatively. Figure (4) compares the improvement in the preoperative clinical status compared to the postoperative clinical status according to Frankel Classification system. The mean number of levels fused was 3.3 (range 2-5 levels), Table (1).

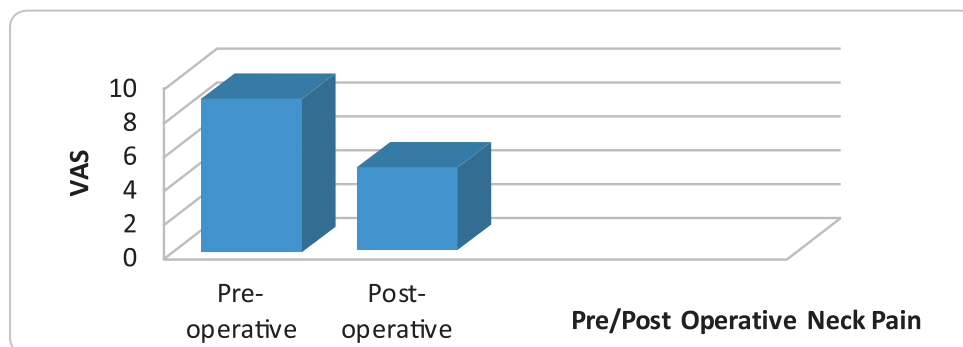


Figure 3. The difference between pre/post operative neck pain measured by VAS.

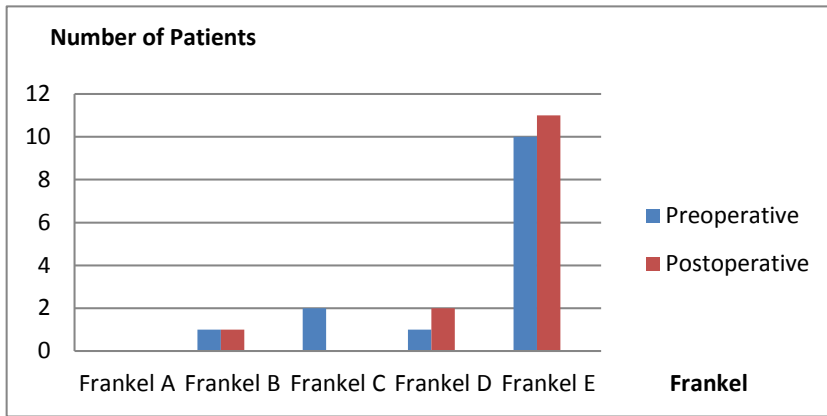


Figure 4. The difference between (pre/post) operative clinical conditions measured by Frankel classification system.

The range of movement postoperatively ranged from 10 to 30 degrees (flexion / extension), 10 to 25 degrees (rotation). 10 to 15 degrees (lateral flexion). This new limitation in movement was annoying to the patient, but they adapted the new range of movement over the next 3 months.

X-rays (Anteroposterior and lateral views) were performed immediately after surgery and at 3 months then at 6 months interval postoperatively. Follow up images have shown restoration of the bony alignment in all the patients. We did not find a case of instrument breakage or loosening, and

we concluded proper instrument fixation in all the patients. On serial follow up X-rays, we confirmed no change in instruments position compared to the first films taken immediately postoperatively. CT scan was done at least once in the postoperative period proved proper screws position for all the patients. X-rays and CT scans done postoperatively showed overall bony fusion in 12 patients (86%) evidenced by absence of pathological movement between the fused vertebral motion segments, and by the presence of fusion mass between the graft and bone, Figures (5,6).

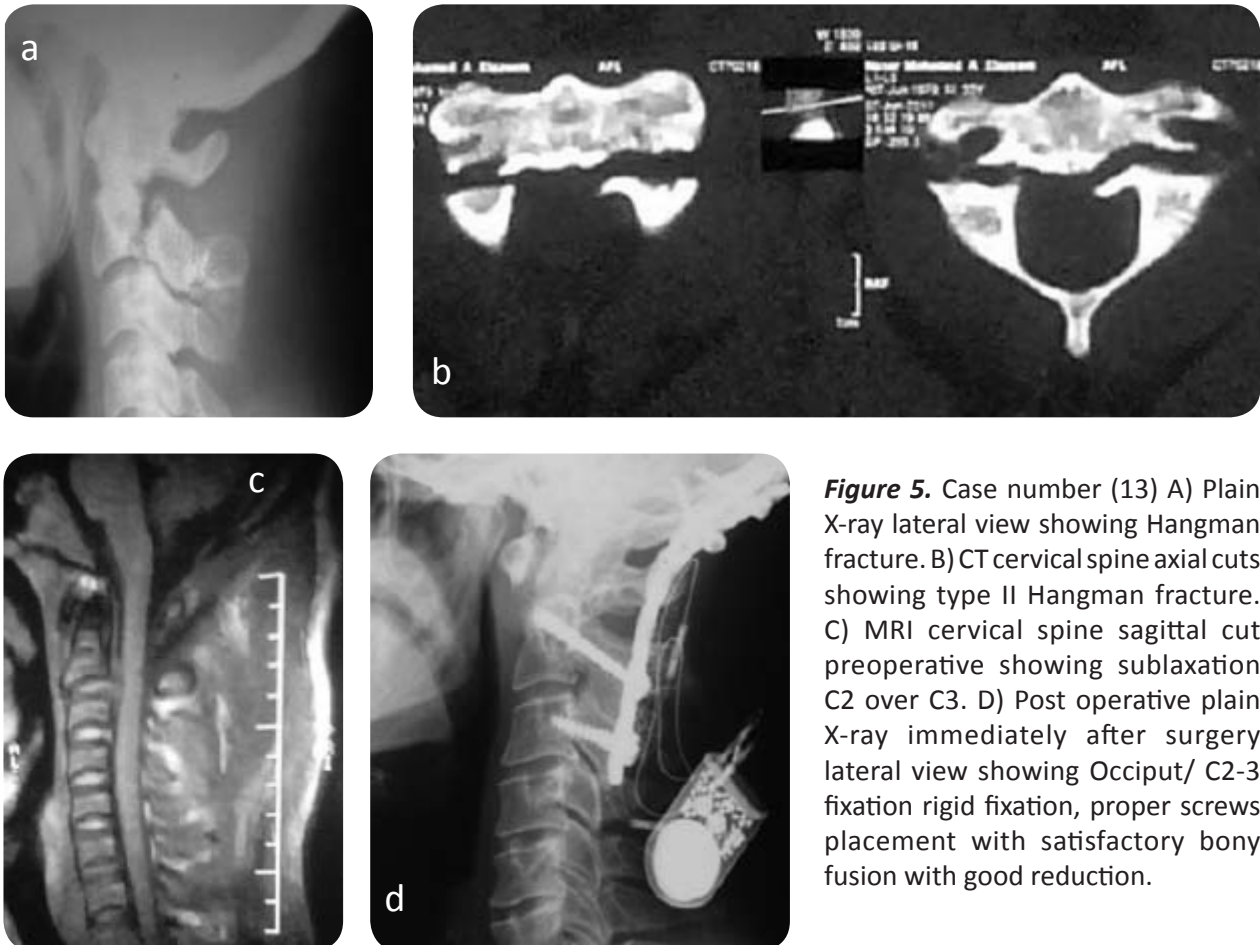


Figure 5. Case number (13) A) Plain X-ray lateral view showing Hangman fracture. B) CT cervical spine axial cuts showing type II Hangman fracture. C) MRI cervical spine sagittal cut preoperative showing subluxation C2 over C3. D) Post operative plain X-ray immediately after surgery lateral view showing Occiput/ C2-3 fixation rigid fixation, proper screws placement with satisfactory bony fusion with good reduction.

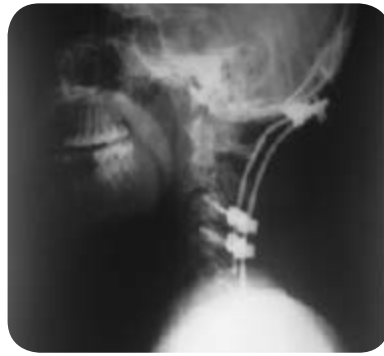
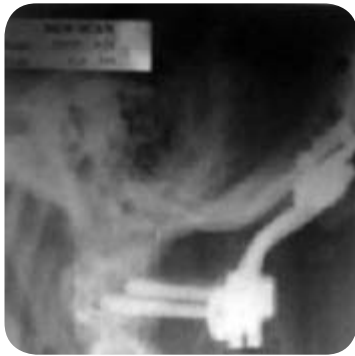
Figure 6. A) Case number (14) Plain X-ray lateral view post operative showing Occiput/ CV1 fixation. B) Case number (6) Post operative plain X-ray lateral view showing Occiput/ CV3-4 fixation.

We reported one case (4.5%) of deep wound infection started on the 8th day postoperatively, which necessitated reoperation for local debridement, therapeutic irrigation with (antibiotic, saline), and application of 2 suction drains in the subfascial layer, emerging from the upper and lower ends of the wounds for daily injecting antibiotics and saline from the upper end and draining from the lower end of the wound. Drains were kept for 9 days, and patient was given intravenous antibiotic according to the results of culture and sensitivity swab taken from the deep layer of the wound. Patient improved totally 2 months later on, and without any need to remove the construct. Follow up clinically and radiologically for this patient later on proved no complications related to the infection.

We met a case of profound bleeding intraoperatively from the vertebral venous plexuses, which was controlled by local application of haemostatic agent made of an oxydized cellulose polymer, and required blood transfusion (one unit). There was not any case of vertebral artery (VA) injury reported during the operation.

Discussion

The unexampled biomechanical strength limitations of the occipitocervical junction, the complex anatomy of occipitocervical region and the frequent diversity in anatomy among individuals all require a specific instrumentation system. The appropriate instrument should have a high strength in different axes, proper dimensions to accommodate into this region, and great flexibility allowing easy stepped implantation of the different parts of the instrument system. There is ongoing controversy regarding the best accepted technique for occipitocervical fusion owing to complexity of surgery, potential risks, efficacy of the system and nevertheless familiarity of the surgeon with the system. The instability of the occipitocervical junction in our study resulted from trauma (9 patients), rheumatoid arthritis (2

patients), basilar impression (1 patient), tumor (1 patient), and Os odontoideum (1 patient) are matching all the published series for possible causes of occipitocervical junction instability.^{3,16,22}

The clinical symptoms for the patients preoperatively included neck pain, occipital headaches, torticollis, parasthesias, weakness and dysphagia are matching the same preoperative clinical symptoms published in other articles with a similar prevalence.^{1,9,20,22} The patients in our study were clinically graded before and after the surgery according to the Frankel grading system similar to George Sapkas et al,⁶ contrary to other authors who used the Japanese Orthopaedics Association score as a clinical assessment parameter, while other published series did not rely on a clinical scoring system for spinal cord affection.^{5,9,20,22} It is our belief that using a specific grading system to detect precisely the degree of spinal cord affection from the specific pathology and its reflection on the clinical status is of great help in accurately comparing (preoperative / postoperative) clinical status and allows comparison of the subsequent results by other authors in the future. Radiological investigational protocol applied in our study (preoperatively-postoperatively) was the same protocol followed up by many other authors.^{3,5,9,18,20,22,24}

The indication for surgical intervention in our study through a posterior approach was the presence of radiological evidence of instability of the occipitocervical junction without anterior compression of the spinal cord matches identically all other series.^{3,5,7,9,21,23} Operative time was longer at the beginning then gradually shortened to between 47 and 60 minute. Similar trends were seen when intra-operative blood loss and X-ray exposure were evaluated. The follow up period had a mean of 18 months in our study is definitely less than the 10 years follow up period reported by Matsunaga et al.¹⁴ the 38 months reported by Gyo-Chang et al.⁹ and the 2 years reported by KJ

Tan et al., Fehlings MG et al.^{4, 11} while more than the 1 year follow up period reported by George et al.⁶ and the 5.2 months follow up period reported by Simon et al.²²

Although there many standardized clinical grading systems evaluating patients with cervical myelopathy, such as the Japanese Orthopaedics Association score (JOA score) and the Nurick Scale, we were stick to the Frankel Classification system as was found in the patient's medical records. The improvement of neck pain (100%), of occipital headache (90%), and the clinical improvement in 12 patients (86%) with (79%) of patients reaching grade (E) on Frankel Classification system are consistent with the 75% to 100% clinical improvement rate reported in the literature^{2,8,9,13,14} and close to the (67%) incidence of clinical improvement reported by other authors.¹⁶ It was difficult to conclude a statistically firm conclusion due to the small sample size, but variable recovery grades of myelopathy is definitely a fact. It is our opinion that diversity in myelopathy grading systems in the literature requires future clinical research with a unified grading system for reliable comparable statistical results.

The overall fusion rate in our 14 patients (86%) without any implant system failure, removal or reoperation till the last visit on the follow up period, are matching the published studies by different authors.^{6,7,9,12,16,17,18,26} Indeed, all recent studies have demonstrated very consistent high fusion rates with occipitocervical junction fixation regardless underlying pathology.^{9,25} Deutsch et al.³ reported a (6%) pseudoarthrosis following occipitocervical fusion which was not met in our study.

The Possible complications related to this specific surgery, include excessive venous hemorrhage, neural tissue injury, VA injury, dural lacerations, were not met in our series but for a case of profound bleeding intraoperatively from the vertebral venous plexuses, which was controlled by local application of haemostatic agent. We reported one case (7%) of deep wound infection which improved after 60 days later on, which is higher than the (3.5%) incidence reported by Jan Stulik et al.¹⁰ The very low rate of surgery related complications of this study also confirms the safety of the procedure.

Doubtlessly, the diverseness in the underlying etiology for occipitocervical instability among the patients in our study might make the outcome apprehension of occipitocervical fusion difficult,

but undoubtedly our study demonstrated an excellent clinical and radiological outcome.

Conclusion

The newly adapted polyaxial plate/rod system for occipitocervical stabilization provided rigid internal fixation with immediate stability with elimination of occipitocervical pseudoarthrosis. The hurdles previously met with standard plate or rod-screw constructs have eliminated. This system allows easy initial screw placement followed by easy rod / plate attachment due to polyaxial screw heads. The system adapts competently to abnormal cervical curvatures, allows an enormous space for bone graft, can easily be extended to multiple levels, and possesses the advantage of compression or distraction. The high fusion rate (86%) as well as biomechanical stability, with a very low rate of complications related to this procedure, with other mentioned technical advantages, all compensate for a the high cost of system. This system provided to be safe and effective, and we advocate using this system until other innovational systems come to light.

References

- 1) Abumi K, Takada T, Shono Y. Posterior occipitocervical reconstruction using cervical pedicle screws and plate-rod systems. *Spine* 24: 1425–34, 1999.
- 2) Deen AG, Birch BD, Wharen RE, Reimer R. Lateral mass screwrod fixation of the cervical spine: a prospective clinical series with 1-year follow-up. *Spine J* 3: 489-95, 2003.
- 3) Deutsch H, Haid RW Jr, Rodts GE Jr, Mummaneni PV: Occipitocervical fixation: Long-term results. *Spine* 30:530–535, 2005.
- 4) Fehlings MG, Errico T, Cooper P, Benjamin V, DiBartolo T: Occipitocervical fusion with a five-millimeter malleable rod and segmental fixation. *Neurosurgery* 32(2):198-207. 1993.
- 5) Gaia Georgopoulos, Peter D. Pizzutillo, Myung Soo Lee, Wilmington, Delaware: Occipito-atlantal instability in children: A report of five cases and review of the literature. *The Journal of Bone and Joint Surgery* 69 (3), 1987.
- 6) George Sapkas, Stamatios A. Papadakis, Dimitrios Segkos, Konstantinos Kateros, George Tsakotos: Posterior instrumentation for occipitocervical fusion. *The Open Orthopaedics Journal* 5: 209-218. 2011.
- 7) Grob D, Dvorak J, Panjabi MM, Antinnes JA : The role of plate and screw fixation in

- occipitocervical fusion in rheumatoid arthritis. *Spine* 15 : 2545-2551, 1994.
- 8) Grob D, Janneret B, Aebi M : Atlanto-axial fusion with transarticular screw fixation. *J Bone Joint Surg Br* 73 : 972-976, 1991.
 - 9) Gyo-Chang Song, Kyoung-Suok Cho, Do-Sung Yoo, Pil-Woo HuhSang-Bok Lee: Surgical treatment of craniovertebral junction instability: Clinical outcomes and effectiveness in personal experience. *J Korean Neurosurg Soc* 48 : 37-45, 2010.
 - 10) Jan Stulik, Tomas Vyskocil, Petr Sebesta, Jan Kryl: Atlantoaxial fixation using the polyaxial screw-rod system. *European spine journal* 16 (4) : 479-484, 2007.
 - 11) KJ Tan, HT Hee: Neurological recovery after occipitocervical fixation. *Journal of Orthopaedic Surgery* 15(3): 323-326, 2007.
 - 12) Korovesis P, Katonis P, Aligizakis P. :Posterior compact Cotrel-Dubousset instrumentation for occipitocervical, cervical and cervicothoracic fusion. *Eur Spine J*; 10: 385-94, 2001.
 - 13) Lenoir T, Hoffmann E, Thevenin-Lemoine C, Lavelle G, Rillardon L, Guigui P: Neurological and functional outcome after unstable cervicothoracic junction injury treated by posterior reduction and synthesis. *Spine* J.6(5):507-13, 2006.
 - 14) Matsunaga, K Ijiri, H Koga : Results of a longer than 10-year follow-Up of patients with rheumatoid arthritis treated by occipitocervical fusion. *Spine* 25: 1749- 1753, 2000.
 - 15) Michael A. Finn, Frank S. Bishop, Andrew T. Dailey: Surgical treatment of occipitocervical instability. *Neurosurgery* 63:961-969, 2008.
 - 16) Nockels RP, Shaffrey CI, Kanter AS, Azeem S, York JE: Occipitocervical fusion with rigid internal fixation: Long-term follow-up data in 69 patients. *J Neurosurg Spine* 7:117-123, 2007.
 - 17) Oda I, Abumi K, Sell LC, Haggerty CJ, Cunningham BW, McAfee PC : Biomechanical evaluation of five different occipito-atlanto-axial fixation technique. *Spine* 24 : 2377-2382, 1999.
 - 18) Paquis P, Breuil V, Lonjon M. Occipitocervical fixation using hooks and screws for upper cervical instability. *Neurosurgery* 44: 324-31, 1999.
 - 19) Paquis P, Lonjon M, Grellier P. Craniovertebral stabilization using a new CCD technique. *Neurochirurgie*; 44: 101-4, 1998.
 - 20) Praveen V. Mummaneni, Regis W. Haid, Vincent C. Traynelis, Rick C. Sasso, Brian R. Subach, Amory J. Fiore, Gerald E. Rodts: Posterior cervical fixation using a new polyaxial screw and rod system: technique and surgical results. *Neurosurg Focus* 12 (1):Article 8, 2002.
 - 21) Sasso RC, Jeanneret B, Fischer K, Magerl F : Occipitocervical fusion with posterior plate and screw instrumentation. A long term follow-up study. *Spine* 19 : 2364-2368, 1994.
 - 22) Simon Bick, Robert Dunn: Occipito-cervical fusion: Review of surgical indications, techniques and clinical outcomes. *Sa orthopaedic journal* 26-32, 2010.
 - 23) Smith MD, Anderson P, Grady MS: Occipitocervical arthrodesis using contoured plate fixation. An early report on a versatile fixation technique. *Spine* 18:1984-1990, 1993.
 - 24) Vale FL, Oliver M, Cahill DW : Rigid occipitocervical fusion. *J Neurosurg* 91 : 144-150, 1999.
 - 25) Winegar, Corbett D; Rihn, Jeffrey A; Hong, Joseph; Fernandez, Carmella; Friel, Brian; Vaccaro, Alexander R:Contemporary posterior occipitocervical fixation techniques.*Current Orthopaedic Practice* 19 (4): 398-406, 2008.
 - 26) Wirbelsäulenzentrum, St. Josefs-Hospital, Wiesbaden: Posterior instrumentation of the cervical spine using the neon occipito-cervical system. Part 2: cervical and cervicothoracic instrumentation. *Oper Orthop Traumatol.* 17(6):579-600, 2005.

Acknowledgments

The authors are grateful to Ehab Emran for assistance with the radiographic image in the figures.

Address reprint
request to:

Mohamed Sawan, MD

Prof in Neurosurgery, Neurosurgery department,
Cairo University, Cairo, Egypt.

Email: mosawan@hotmail.com

نتائج التثبيت الجراحي لعدم الاستقرار القذالي العنقي عن طريق إستخدام نظام متعدد المحاور (لوحة / قضيب) . تقرير من ١٤ حالة

المقدمة: عدم الاستقرار الوصلة القذاليه العنقيه مفترق كانت دائما مشكلة جراحية صعبة بسبب الخصائص الفريدة التشريحية والنشاط الحيوي لهذه المنطقة

الهدف: هو تحديد السلامة والفاعلية و المضاعفات المتعلقة باستخدام نظام التثبيت الجراحي لعدم الاستقرار القذالي العنقي عن طريق إستخدام نظام متعدد المحاور (لوحة / قضيب).

تصميم الدراسة: هذه دراسة استعادية لعدد ١٤ مريضا خضعوا لانصهار الوصلة القذاليه العنقيه بسبب عدم الاستقرار باستخدام نظام التثبيت الجراحي لعدم الاستقرار القذالي العنقي عن طريق إستخدام نظام متعدد المحاور (لوحة / قضيب). خلال الفترة من يناير ٢٠٠٩ الى سبتمبر ٢٠١١ في مستشفيات جامعة القاهرة ومستشفى معهد ناصر

المواد والطرق: دراستنا استعرض التقنية الجراحية ، ومجموعة متنوعة من الأجهزة ، ونتائج ما بعد الجراحة، والمضاعفات المختلفة ومعدلات الاندماج التي تتعلق هذه التقنية

النتائج: كان عدد المرضى ١٤ و كان عدد الذكور ٨ و عدد الإناث ٦ مع متوسط عمر ٤٤.٩ سنة. وكان متوسط وقت الجراحة ٩١ دقيقة ، ومع فقدان للدم بمعدل ٦٦٠ مل على متوسط عدد مستويات المنصهره ٣.٣. وكان متوسط فترة المتابعة ١٨ شهرا. التحسن السريري وقع في ١٢ مريضا. وكان معدل الانصهار واضحا في معظم الحالات (٨٦٪). في الفترة بعد الجراحة حالة واحدة كانت تعاني من التلوث و تحسنت بعد شهرين.

الخلاصة: الانصهار الجراحي والتثبيت من مفترق الوصلة القذاليه العنقيه باستخدام نظام الأجهزة الجديدة على الرغم من أنه يتطلب الكثير من الناحية الفنية أثبت نجاح سريري و أثبت جدوي وارتفاع معدل الانصهار (٨٦ ٪) ، وكذلك استقرار النشاط الحيوي ، مع نسبة منخفضة جدا من المضاعفات المتعلقة بهذا الإجراء.