

## Simultaneous Posterior Fusion with Video Assisted Thoracoscopic Surgery (VATS) for Treatment of Kyphotic Deformities in Prone Position. A Series of 86 Cases

Mohamed Wafa, MD., Fady Michael, MD., Ahmed El Badrawi, MD.  
*Orthopedic department, Einshams University, Cairo, Egypt.*

### Abstract

**Background Data:** The traditional position of the patient during VATS procedure is the lateral decubitus. This make the surgeon oriented to the field since this the same position of the traditional thoracotomy and make it easy for conversion to open surgery if needed. Prone position; although may be difficult; has the advantage of performing two major procedures; posterior fusion and anterior reconstruction by at same time with minimized morbidity and mortality.

**Purpose:** To evaluate the efficacy and safety of VATS in management of different dorolumbar spine pathologies.

**Study Designs:** Prospective clinical case study.

**Patients and Methods:** Eighty six cases of kyphotic deformities due to various pathologies (28 cases of fractures, 42 infection, 16 tumors) were treated by simultaneous posterior fusion techniques and anterior reconstruction by VATS using bone grafts, cages and spacers while the patient is in prone position. The mean follow up of the patients was 26.1 months. All patients were evaluated radiographically preoperatively, postoperatively and at the end of follow up using Cobb angle. Radiographs at the final follow up were assessed for fusion. VAS was used to evaluate pain of the thoracoscopic mini incision. All cases were assessed neurologically by Frankel grading system and Denis pain score for back pain at the end of follow up. Operative time, intra and postoperative complications and blood loss were reported.

**Results:** The mean age was 40.3 years. The regional Cobb angle improved from 34.7° preoperatively to 11.6° postoperatively. Most of patients had improved on both Frankel grading system and scores of pain. There was no indication to convert any case to open procedure. No serious intraoperative complication occurred but one case of massive bleeding due to injury of one intercostal vessel that has been controlled thoracoscopically. The postoperative complications included chest infection, delayed lung inflation, intercostals neuralgia and transient neurological deficits.

**Conclusion:** VATS using limited mini-incision provide an excellent and safe approach for management of dorsolumbar pathologies. Prone position facilitates handling of the spine both anteriorly and posteriorly at the same time to get the maximum benefit offered by both approaches without excessive morbidity to the patient. (2012ESJ020)

**Keywords:** video assisted thoracoscopic surgery, dorsal kyphosis, dorsolumbar spine, prone position.

## Introduction

The history of medical endoscopy can be traced to 1806 when Philipp Bozzini from Frankfurt, Germany, developed a novel invention called the Lichtleiter (light conductor). This invention is considered the first endoscopic instrument. In 1900, Jacobeus introduced thoracoscopy to medical practice for the diagnosis and treatment of pulmonary tuberculosis<sup>18</sup>. In 1993 Mack and colleagues reported 10 cases in whom VATS was used for various spine therapeutic procedures<sup>13</sup>.

The range of endoscopic interventions has expanded continuously over the past few years. As an alternative approach to thoracotomy, thoracoscopy can be used to perform thoracic corpectomies; to decompress the spinal cord and nerve roots; or to resect, reconstruct, and fixate a portion of the spinal column affected by destructive processes<sup>1</sup>.

This is a prospective study for patients with different pathologies that led to kyphotic dorsal spine. We planned to treat such patients with video assisted thoracoscopic procedure to deal with the anterior column pathology simultaneously with posterior surgery in prone position. We aimed to compare our results regarding operative time, complications, postoperative pain, feasibility of the technique and results with the published data in comparison to traditional open approaches as well as the thoracoscopic surgery in traditional lateral position.

## Patients and Methods

Since 2000, 86 patients of dorsal and dorsolumbar kyphotic pathologies were managed by simultaneous posterior fixation and anterior reconstruction by VATS in prone position. Our inclusion criteria included pathologies from D4 to first lumbar vertebra. The exclusion criteria included patients with bleeding tendency, pathologies below L1 vertebra, previous thoracotomies, patients with severe pulmonary diseases who will not tolerate single lung ventilation and patients with no need for anterior column reconstruction.

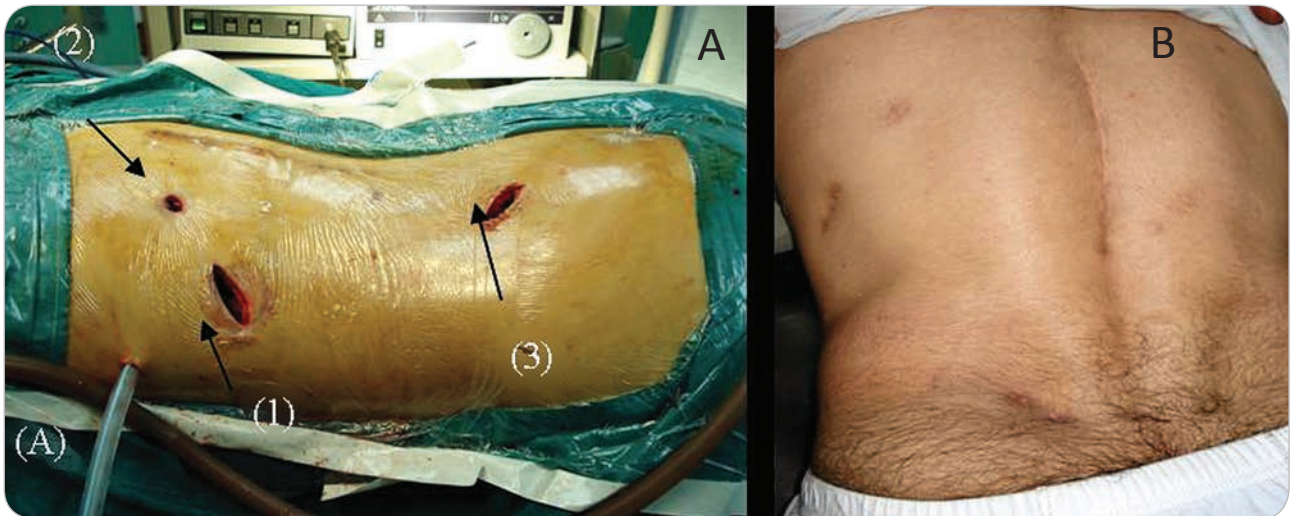
The 86 patients included 28 cases of dorsal and

dorsolumbar fractures, 42 cases of dorsal spine infection and 16 cases of vertebral body metastasis. Our aim was to correct the resulted kyphotic spine deformity by simultaneous posterior fixation and anterior reconstruction with the least morbidity. The indications of surgical interference were significant kyphosis that needed anterior reconstruction, neurological deficits due to anterior compression and presence of anterior abscess.

Our procedure was carried on under general anesthesia using double lumen endotracheal tube to allow selective deflation of ipsilateral lung and single lung ventilation in the opposite side. The patient then was turned to prone position lying on a well-padded frame that allows good support to the patient and a free space to handle the thoracoscopic tools freely. The surgical draping was done to expose the spine for a midline posterior approach, the ipsilateral iliac crest for bone graft harvesting and the chest wall till the anterior axillary line. We prefer to use left sided approach to the thoracic cavity in lesions below the ninth dorsal vertebra and right sided approach for higher levels.

We usually start with the traditional posterior mid line approach of the spine to expose the desired levels for posterior pedicular fixation. The pedicle screws were inserted and their position was verified using the image intensifier in lateral position. The whole construct was not assembled till the end of the thoracoscopic anterior reconstruction procedure.

Two portals only were used to accomplish the endoscopic procedure. (Figure 1: A) The viewing portal where the camera is introduced via a cannula and the working portal which was a mini incision of 3 cm length located in the intercostal space parallel to the rib between the anterior and posterior axillary lines with no need for rib excision. The working portal was usually located in the intercostal space that provides a direct trajectory to the desired level. The single lung ventilation allowed a copious thoracic cavity with no need for inflation of gases. We used a zero degree camera except when decompression was done a 30° telescope was used to verify the clearance of the dura.

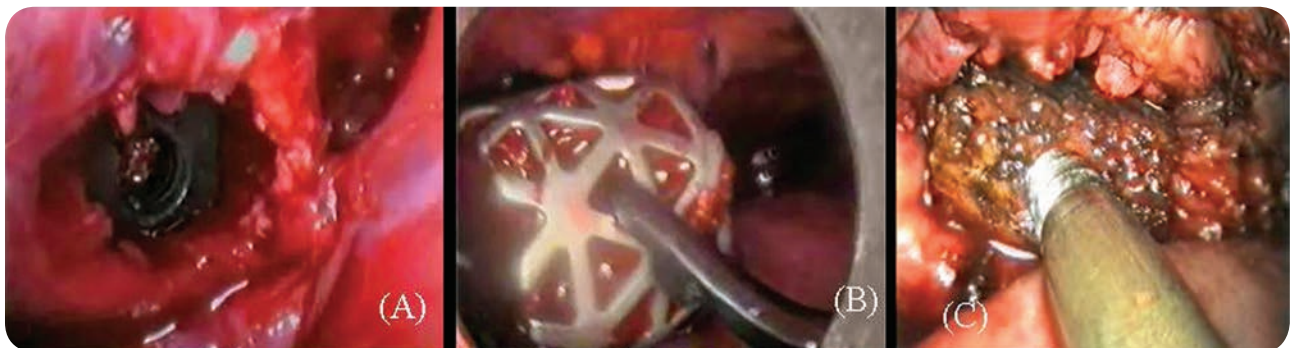

**Figure 1.** A; Prone patient position (1) the working, (2) the viewing portals and (3) bone graft incision B; Wound cosmesis.

The thoracoscopic tools were used for corpectomy, discectomy, decompression, abscess evacuation, debridement or tumour excision followed by anterior reconstruction using tricortical iliac bone graft with or without cages or spacer. We used cement spacers in 12 cases, interbody carbon cages in 8 patients and mesh cage in 14 cases (Figure 2-5).

After anterior reconstruction procedure had been fulfilled, the posterior construct was assembled and compression was applied posteriorly on the anteriorly seated construct to provide more stability.

An intercostal tube was inserted under water seal and all the wounds were closed. The patient was hospitalized under intravenous antibiotics in the ward till after removal of the intercostals tube by two days. Only 2 cases were admitted to ICU due to bad chest condition temporarily for overnight postoperatively. We used intravenous NSAIDs and paracetamol as analgesics. Postoperative X-rays was done together with daily chest x-rays till removal of the intercostal tube.



**Figure 2.** Anterior reconstruction of the vertebral body, (A): Interbody carbon cage, (B) Mesh cage, (C) Tricortical iliac bone graft.

The X-rays were evaluated for pre and postoperative Cobb angle in comparison to the regional Cobb angle at the end of follow up. All patients were graded according to Frankel neurological grade and visual analogue score at the second day postoperative for evaluation of the thoracoscope mini-incision. At the end of follow

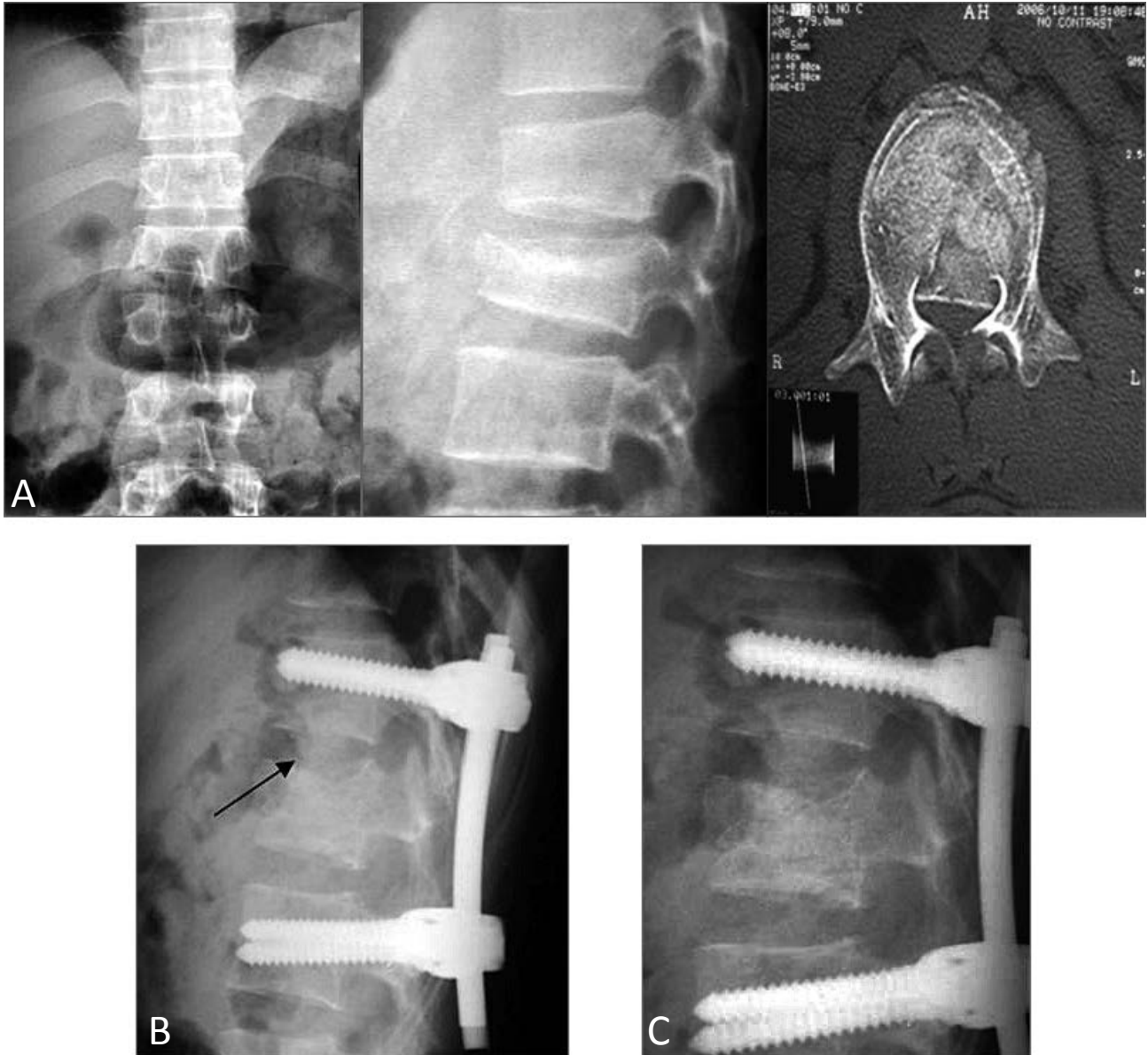
up, all patients were evaluated for back pain using the Denis pain score. The data of the patients were collected prospectively and after discharge. Fixed appointments were scheduled for follow up at 2 weeks, 6 weeks, 3 months then a 3 months schedule till fusion occurred and then at yearly intervals.



## Results

The mean age of patient was 40.3 years. The youngest was 16 years old and the oldest was 68 years old. The study included 49 females and 37 males. TV6 was the highest level and LV1 was the lowest level to be handled thoracoscopically. The mean operative time was 178 minutes. The average

intraoperative bleeding was 480 ml for both the posterior and thoracoscopic procedure. There was no need to convert any patient into open procedure as we did not confront any serious intraoperative complications except in one case of massive blood loss due to injury of one intercostal vessel that was controlled endoscopically.



**Figure 3.** Female patient 18 years old. presented 3 weeks after falling from height with fracture LV1, Frankle B. Posterior fixation from TV12 to LV2 with pedicular screws together with anterior thoracoscopic reconstruction with bone graft between TV12 and LV1. After two years the construct was stable with no loss of correction and sound anterior fusion between TV12 and LV1. The patient became Frankel E. (A); Preoperative x-rays and CT showed burst fracture L1, (B); Immediate postoperative x-ray with the arrow denote the bone graft between D12-L1. (C); 2 years follow up with no loss of correction and sound fusion occur.

The average postoperative blood loss was 400 ml for the posterior approach and 350 for the anterior. The intercostal tube was removed after 4 days in average. The postoperative VAS of the thoracoscopic mini-incision on second day postoperative was of average 4. The mean postoperative stay was 8.2 days.

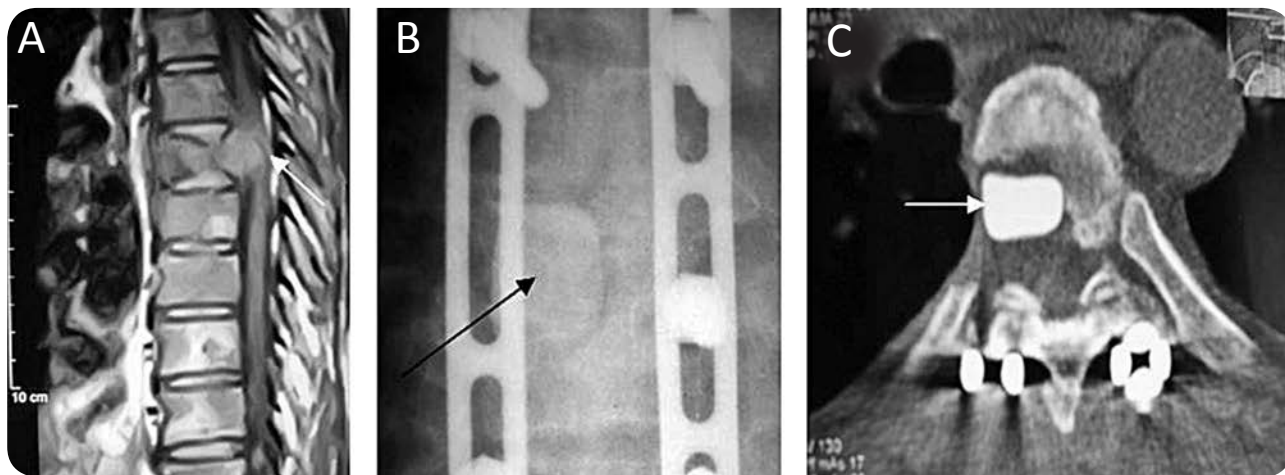
Neurologically, 32 cases were presented with neurological deficits with variable grades on Frankel grading system. 24 cases were improved at least one grade, 6 showed no improvement at the end of follow up and only 2 cases was deteriorated postoperatively one grade (one improved and the other unfortunately did not).

Radiologically, the regional Cobb angle improved postoperatively to  $11.6^\circ$  compared to the mean preoperative angle of  $34.7^\circ$  with average  $23.1^\circ$  correction. The average follow up was 26.1 months. Six cases died during the follow up period (4 cases with lung metastasis, 2 cases of unrelated causes). Most of patients showed marked improvement of their back pain on Denis back pain grading system at the end of follow up (65 were P1 with no pain, 6 were P2 with mild pain without need for analgesics, 4 of score P3 with moderate pain with occasional

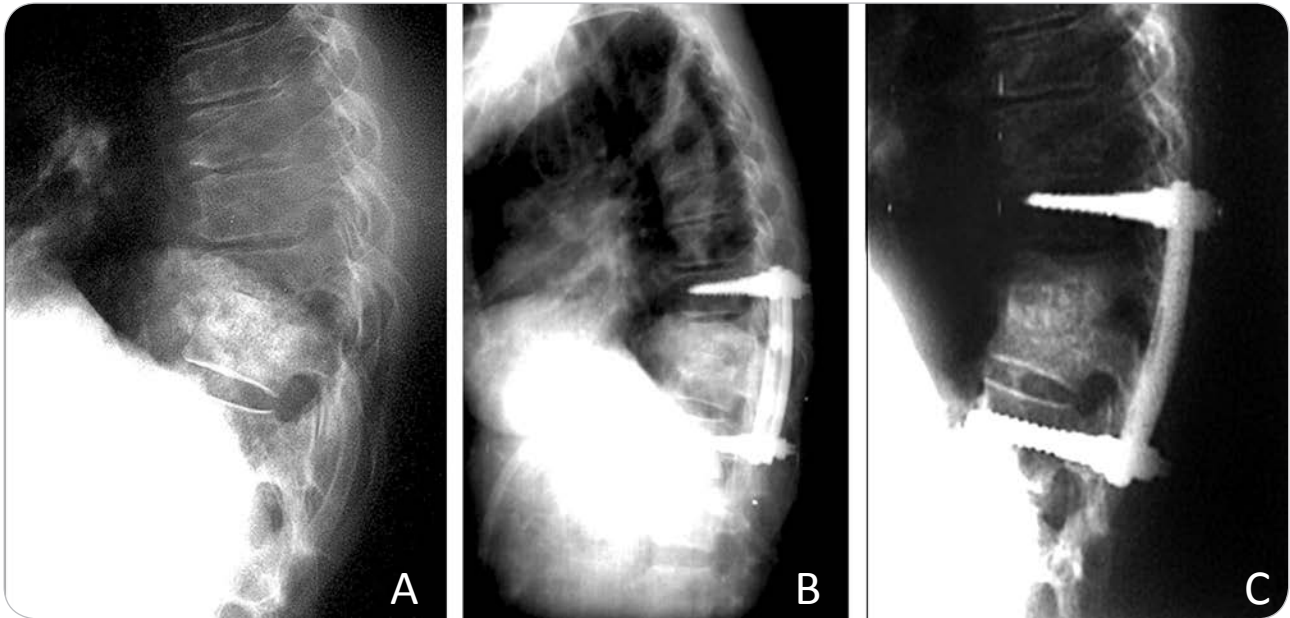
medication but no interruption of work or significant change in activities of daily life and 3 were P4 with moderate to severe pain with frequent medication and occasional absence from work or significant change in activities of daily life and only 2 patients was P5 with constant or severe incapacitating pain and chronic medication). Sixteen cases were still complaining of occasional graft site pain at the end of follow up.

Most of cases went into solid sound anterior fusion at the end of follow up. There was loss of postoperative correction of regional Cobb angle of an average  $6^\circ$ . We had 6 cases of anterior graft resorption and non-union (4 of which showed metal failure). Two of these patients underwent revision surgery.

In our study, we had 15% approach related complications in the form of intercostal neuralgia and lung atelectasis, posterior wound infection and 14% unrelated to the approach in form of chest infection. All the complications were transient and resolved completely with no residual effect except for 2 cases of posterior midline approach deep infection that necessitated debridement and one case of them needed removal of posterior implants.



**Figure 4.** Male patient, 68 years old presented with paraparesis of both lower limbs, MRI revealed metastasis at TV7. Posterior fusion was done together anterior decompression and reconstruction with cement spacer in prone position. (A) Preoperative MRI shows the pathological fracture and cord compression. (B) Postoperative AP view with the cement spacer in place. (C) Postoperative axial CT shows the decompression and cement spacer.



**Figure 5.** Female patient, 62 years old, presented with severe back pain, dorsal tenderness, hyper-reflexia of both lower limbs and elevated ESR and CRP. Plain X-rays revealed spondylodiscitis TV8-TV9. Posterior fusion with anterior thoracoscopic debridement and bone grafting was done at the same session. (A) Preoperative x-ray shows spondylodiscitis TV8-TV9. (B) Immediate post operative after posterior fixation and anterior thoracoscopic debridement and impaction bone grafting. (C) 8 months follow up showed sound anterior fusion of TV8-TV9.

## Discussion

Anterior weight bearing column reconstruction is fundamental in management of any spine pathology to ensure and maintain spine stability and thereafter painless spine. High morbidities of 14-24 % are well known to be associated with traditional open approaches<sup>3</sup>. In a review by Faciszewski et al of 1223 anterior spinal fusion procedures for different indications, the overall complication rate for standard open approaches to the spine was 11.5% with 0.33% mortality, 0.16% incidence of paraplegia and 9.17% incidence of post thoracotomy pain syndrome<sup>3</sup>.

Minimally invasive thoracoscopic and endoscopic assisted approaches are now feasible in treatment of different dorsal and dorsolumbar spine pathologies. All spine procedures that was done through traditional open approaches are now feasible endoscopically with much lower morbidities.

Because the thoracoscopic technique requires small incisions without any need for major muscle dissection or rib resection with a shorter operating time. Regarding the immediate postoperative pain,

there are several investigators that demonstrated the reduction of the overall use of analgesics after minimally invasive surgery in comparison with patients who have undergone anterolateral thoracotomy<sup>5,10,11</sup>. This reduction of postoperative pain was demonstrated in Kim et al., study in which 30 patients having endoscopic surgery in the first year were compared with 30 patients who had undergone open surgery. In the former group, the analgesic medication duration was reduced by 31% and the overall dosage by 42% relative to the latter group treated by open surgery. It is well known that the intensity of acute postoperative pain correlates highly with the occurrence of chronic pain after thoracic surgery. Thus, the reported frequency of chronic postoperative pain ranges from 7% to 55% after thoracotomy compared with 4% to 35% reported with minimally invasive surgery<sup>8</sup>. According to Passlick et al., 68% of 60 patients were free of pain after minimally invasive surgery at the end of a median observation period of 59 months. Thirty two reported chronic pain, of whom two required analgesic medication. In the group of patients

who had undergone thoracotomy, the proportion experiencing chronic pain was 52%. One patient in five regularly took analgesics, four patients even daily. The intensity of pain was on average higher than after minimally invasive surgery<sup>15</sup>.

In this study, we did not confront any case of chronic pain related to our minimally invasive approach, only one case of prolonged intercostals neuralgia that was relieved completely by intercostals block. The intensity of post-operative pain is highly encouraging if compared with the traditional thoracotomy and thoracolumbar approaches. The largest series on the thoracoscope or endoscopic assisted treatment of fractures in 371 patients reported a complication rate of 5.4% associated with the endoscopic approach and a complication rate of 4.3% unrelated to the approach<sup>7</sup>. Thoracoscopic assisted approach is a safe and reliable technique. The level of safety of endoscopic surgery is reflected in lower complication rates and operative time which are least comparable to open procedures. In our series, all the complications related to the thoracoscopic approach were transient. So we agree with the high level of safety of this minimally invasive approach.

Compared to open thoracotomy, no recorded shoulder girdle dysfunction was reported in the current study. This can be explained by the use of mini invasive muscle splitting (2 cm) approach in comparison to the muscle cutting wide exposure of thoracotomy<sup>6</sup>.

Also rib sparing during thoracoscopic approach minimizes pain and intercostal neuralgia. Another advantage of the thoracoscopic approaches was minimal affection of the pulmonary functions. This was illustrated by Faro and colleagues who found that the change in FVC from before surgery to 1 year after surgery was significantly different between the thoracoscopic and thoracotomy groups, with patients who underwent thoracoscopic procedure recovering their preoperative FVC and those who underwent thoracotomy having a persistent FVC deficiency<sup>4</sup>. The esthetic and cosmetic result also speaks in favor of the minimally invasive procedure, reducing the mental damage caused among the predominantly youthful patient group by distressing scar formation to a minimum<sup>1</sup> (Figure 1-B).

The classical thoracoscopic approach utilizes the

lateral decubitus to access the spine<sup>16</sup>. This study was done in the prone position as it has many advantages over the lateral position. First, the prone position allows the posterior procedure to be done simultaneously without the need for changing the positioning, re-draping and sterilization, considerable time is lost and morbidity on changing from lateral to prone position. Also, it shares in correcting the angular deformity by placing the anterior structures at tension. The combined back-front procedures saves time and gives better results; in graft insertion the posterior screws are distracted allowing maximal anterior column height reconstruction, then compression of the graft giving it maximal stability. In the prone position the lung after deflation falls by gravity clearing the field of surgery and furthermore no needed retractors to keep lung away, this obviously frees the assistant hands for other needs. This position as well allows the great vessels to fall anteriorly with a plain of cleavage of areolar tissue between the great vessels and the spine. This adds safety for the prone position. This position allows blood to fall anteriorly away from the spine giving a clear field of vision without the need of frequent interruption of the procedure by using suction device to clear the field. Also, it is more comfortable to the surgeon as it offers him one of the few chances to sit down during spine procedure. The previous advantages of the prone position were reported also by studies made by King et al.,<sup>9</sup> and Lieberman et al.,<sup>12</sup>.

The drawback of this position is that it is not familiar to all surgeons to work in this position which may confuse them and conversion into open thoracotomy procedure necessitates change of patient position into the lateral decubitus which may consume considerable time in critical situations. In our study, we did not need to convert any of our patients into open thoracotomy and we built up learning curve that familiarized us with the prone position without any confusion. Our final outcome measures for patient assessment both radiologically and clinically are highly satisfactory and nearly compared to many investigations that evaluate the use of thoracoscope in different spine pathologies<sup>2,14,17</sup>.



## Conclusion

VATS are a very effective procedure to handle anteriorly based pathology of dorsal and dorsolumbar spine. This technique offers results nearly similar to the open traditional approaches with the least and minimal morbidity. Prone position although it is not familiar, it offers many advantages over the lateral decubitus. It allows the surgeon to control the situation both anteriorly and posteriorly at the same time offering the best results to the patient.

## References

1. Beisse RW, Potulski M, Bührn V: Endoscopic techniques for the management of spinal trauma. *Eur J Trauma* 27:275-291, 2001
2. Beisse RW, Muckley TH, Schmidt MH, Hauschild M, Bühren V: Surgical technique and results of endoscopic anterior spinal canal decompression: *J Neurosurgery Spine* 2:128-136, 2005
3. Faciszewski T, Winter RB, Lonstein JE, Denis F, Johnson L: The surgical and medical perioperative complications of anterior spinal fusion surgery in the thoracic and lumbar spine in adults. A review of 1223 procedures. *Spine* 20:1592-1599, 1995
4. Faro FD, Marks MC, Newton PO, Blanke K, Lenke LG: Perioperative changes in pulmonary function after anterior scoliosis instrumentation: thoracoscopic versus open approaches. *Spine* 30(9):1058-1063, 2005
5. Furrer M, Rechsteiner R, Eigenmann V, Signer C: Thoracotomy and thoracoscopy: postoperative pulmonary function, pain and chest wall complaints. *Eur J Cardiothoracic Surg* 12:82-87, 1997
6. Jaink JS, Burrington JD, Jaink JE, Wayne ER, Chang JHT, Rothenberg SS: anterior exposure of spinal deformities and tumors: A 20 year experience. *J of Ped Surg* 32(6):852-859, 1997
7. Khoo LT, Beisse R, Potulski M: Thoracoscopic-assisted treatment of thoracic and lumbar fractures: a series of 371 consecutive cases. *Neurosurgery* 51(5 Suppl):S104-S117, 2002
8. Kim DH, Jahng TA, Balabhadra RS, Potulski M, Beisse R: Thoracoscopic transdiaphragmatic approach to thoracolumbar junction trauma. *Spine J* 4:317-328, 2004
9. King AG, Mills TE, Loe WA, Chutkan NB, Revels TS: Video assisted thoracoscopic surgery in prone position. *Spine* 18:2403-2406, 2000
10. Kirby TJ, Mack MJ, Landreneau RJ, Rice TW: Lobectomy – video- assisted surgery versus muscle sparing thoracotomy. A randomized trial. *J Thorac Cardiovasc Surg* 109:997, 1995
11. Landreneau RJ, Wiechmann RJ, Hazelrigg SR, Mack MJ: Effect of minimally invasive thoracic surgical approaches on acute and chronic postoperative pain. *Chest surg Clin N AM* 890-891, 1998
12. Lieberman IH, Salo PT, Orr D, Kraetchme B: prone position endoscopic transthoracic release simultaneous with posterior instrumentation for spinal deformity. *Spine* 25:2251-2257, 2000
13. Mack MJ, Regan JJ, Bobeck WP: Application of thoracoscopy for diseases of the spine. *Ann Thorac Surg* 56:736-738, 1993
14. Parker LM, McAfee PC, Feddler IL, Weis J C, Ceis WP: Minimally invasive spine technique to treat spine infections. *Orthop Clin North Am* 27(1):182-199, 1998
15. Passlick B, Mandelkow H, Siemel W, Thetter O: Langzeitbeschwerden nach minimal-invasiven thoraxchirurgischen operationen und nach thoracotomie. *Chirurg* 72:934-938, 2001
16. Regan JJ, Guyer RI: Endoscopic Techniques in Spinal Surgery. *Clin Orthop* 335:122-139, 1997
17. Ringel F, Stoffel M, Stuer C, Totzek S, Meyer B: Endoscopy assisted approaches for anterior column reconstruction after pedicle screw fixation of acute traumatic thoracic and lumbar fractures. *Neurosurgery* J 62:5445-5453, 2008
18. Rosenthal DJ, Dickman CA: The History of Thoracoscopic Spine Surgery, in Dickman CA, Rosenthal DJ and Perin NI(eds) *Thoracoscopic Spine Surgery*. Thieme Medical publishers, Inc, New York, 1999, 1-5



Address reprint  
request to:

Mohamed Wafa, MD.

Orthopedic department, Einshams University, Cairo, Egypt.

E-mail: mwafaspine@hotmail.com

## الملخص العربي

الانصهار الخلفي في وقت واحد مع جراحة الفيديو المساعد لعلاج التشوهات حدابي في وضعيّة الرقود. سلسلة من ٨٦ حالة.

لقد تم إدخال منظور الصدر الجراحي لعلاج أمراض العمود الفقري منذ عام ١٩٩٣. وقد أثبتت هذه الطريقة فعاليته كبيره في التعامل مع الأمراض الأمامية من العمود الفقري للفقرات الصدرية والفتننية الأولى. هذا الأسلوب يوفر نتائج المريض مشابه تقريبا للنهج التقليدي مع الحد الأدنى للمضاعفات.

وقد كان وضع الاستلقاء الجانبي هو الوضع المعتاد لهذه الجراحة مما يجعل من السهل التحويل لشق صدري إذا لزم الأمر. وبالرغم أن وضع الاستلقاء علي البطن هو وضع غير معتاد لجراحي مناظير الصدر ولكنها توفر مزايا عديدة أكثر من الاستلقاء الجانبي. لأنها تتيح للجراح إجراء الجراحة الأمامية والخلفية في نفس الوقت مع تقديم أفضل النتائج للمريض.

وقد تم علاج ٨٦ حالة من التشوه التحدي بسبب أمراض مختلفة (٢٨ حالة من حالات كسور الفقرات و٤٢ حالة من حالات العدوى العمود الفقري الظهرية، ١٦ حالة من أورام الجسم الفقري) في وقت واحد بواسطة تقنيات التثبيت الخلفي وإعادة البناء الأمامي للفقرات بواسطة المنظار الجراحي وقد أظهرت هذه الجراحة نتائج مرضية جدا مع تلافي مضاعفات الجراحة المعتادة.