

# The Efficacy of Stand-Alone PEEK Cages versus Locking Plate in Three or More-Level Anterior Cervical Discectomy and Fusion

**Khaled M Hassan MD., Mohamed El-Meshtawy MD.**

*Orthopedic Department, Assiut University Medical School, Assiut, Egypt.*

## Abstract

**Background Data:** Anterior cervical discectomy and fusion (ACF) is currently the gold standard for surgical treatment of cervical degenerated disease (CDD). For many years, patients were treated with ACF using tricortical autogenous bone graft augmented with anterior cervical locking plate. Later, Cages packed with calcium triphosphate bone substitute were the treatment of choice.

**Study Design:** A comparative clinical case study.

**Purpose:** Compare the outcomes of ACF using stand-alone PEEK cages packed with calcium triphosphate bone substitute compared with tricortical iliac autograft augmented with anterior locking plate in treatment of three or more-level CDD in 47 patients.

**Patients and Methods:** We evaluated 47 patients (22 patients in the locking plate group and 25 patients in the cage group) at our institution from January 2007 to September 2010. They were followed up for minimum 2 years. The clinical outcomes (Nurick grade and JOA score), radiographic changes (local kyphotic angle (LKA), fusion, subsidence, and adjacent disc degeneration), and complications were compared between the 2 groups.

**Results:** The blood loss was significantly less in cage group (388 cc) than plate group (529.6cc). Both groups showed significant improvement in LKA postoperatively and at latest follow up with no significant difference. Fusion was 94.1% and 94.4% in cage and plate groups in order. There was insignificant more subsidence in cage (21.4%) than plate group (11.3 %). There was significant improvement in Nurick grading of both cage and plate groups as it improved from 3.32 and 3.68 preoperatively to 0.84 and 1.05 at latest follow up in order with no significant difference between the two groups. Final outcome was comparable in both groups: In cage group: excellent in 7 patients, good in 16, and fair in 2. In plate group, excellent in 8 patients, good in 11, and fair in 3.

**Conclusion:** In multiple levels (three or more) ACF, the use of stand-alone PEEK cages results in less blood loss, less adjacent disc degeneration, less complications than the use of autograft augmented with locking plate but unfortunately, more incidence of subsidence. However, there is no significant difference in the postoperative and latest follow up LKA, fusion rate, clinical, and functional outcomes between the cage and plate groups. (2013ESJ049)

**Keywords:** multiple level CDD, cervical locking plate, cervical PEEK cage.

## Introduction

Cervical degenerated disc disease (DDD), in severe cases, could potentially be debilitating disease.<sup>36</sup> Several procedures have been described for the treatment of disc herniation and cervical spondylosis when conservative treatment fails.<sup>1,2,4,8,10,16,33</sup> In the past few years, anterior cervical discectomy and fusion (ACF) had been the gold standard for surgical treatment of cervical DDD.<sup>8,29,36</sup> Multilevel cervical discectomy is often combined with plate and screw fixation to maintain the spinal curvature, and increasing the graft fusion rate. However, plates and screws may cause complications, such as screw breakage, screw pull out, esophagus perforation and spinal cord or nerve injury.<sup>22</sup>

Stand-alone interbody fusion cages represent an alternative for anterior cervical fusion in the treatment of cervical DDD. Cage-assisted ACF can restore physiologic disc height, provide immediate load bearing support to the anterior column, facilitate fusion and avoid many graft and plates related complications.<sup>18,20</sup> Clinical outcomes have been encouraging in one- and two-level procedures but the results are still questionable in three- and four-level.<sup>17</sup> Good results have been reported with performing ACF using cages as regard fusion rate, subsidence, and pseudoarthrosis.<sup>25,38</sup>

The aim of this study is to evaluate the outcomes of ACF using PEEK cages alone packed with calcium triphosphate bone substitute compared with tricortical iliac autograft augmented with anterior locked plate in treatment of multiple levels cervical DDD in 47 patients.

## Patients and Methods

### **Patients:**

This study included 47 patients with multiple levels cervical DDD presented with radiculopathy, myelopathy, radiculomyelopathy. All patients underwent ACF in Orthopedic department of Assiut University Hospital between January 2007 and September 2010. Twenty two patients were treated with ACF using tricortical autogenous bone graft augmented with anterior cervical locking plate (Figure 1, A) (plate group). PEEK cages (Figure 1, B) packed with calcium triphosphate bone substitute were used in the other 25 patients (cage group). No specific guidelines or indications were used in dividing the patients among the two groups. Discectomy and

decompression were done microscopically and the posterior longitudinal ligament was removed in all cases. The demographic data and surgical levels of both groups are shown in table (1).

### **Methods:**

All patients of both groups were assessed neurologically according to Nurick grading<sup>27</sup> preoperatively, postoperatively, and at latest follow up. Posterior neck pain and arm pain (radiculopathy) was described by 10 point-Visual Analogue Scale (VAS).<sup>6</sup> Plain X-ray and MRI were done for all patients preoperatively. Postoperative clinical and radiological follow up were carried out at 3 months interval up to 24 months after surgery. Fusion was assessed according to Brantigan Criteria of fusion.<sup>5</sup> This criteria include: the bone in fusion area is more dense and more mature than originally achieved during surgery, no interspace between the cage and the vertebral body, and mature bony trabeculae bridging in fusion area. The anterior segmental height (ASH) and posterior segmental height (PSH) were measured on the radiographs. The ASH/PSH was measured as the distance between the anterior/posterior margin of the upper end plate of the upper vertebra and the anterior/posterior margin of the lower end plate of the lower vertebra. Anterior/posterior subsidence was defined as  $\geq 2$  mm reduction in the ASH/PSH between immediately after surgery and the last follow-up.<sup>12,14</sup> The radiological evidence of adjacent disc disease was determined using the modified Hilibrand criteria<sup>15</sup> as follows; new anterior osteophyte formation or enlargement of existing osteophytes, increased or new narrowing of a disc space ( $>30\%$ ), new or increased calcification of the anterior longitudinal ligament.

The surgical outcome was evaluated by the Modified Japanese Orthopedic Association (JOA) score<sup>26</sup> and the recovery ratio (RR). A recovery rate over  $\%75$  is described as excellent, from  $\%51$  to  $\%75$  is good, from  $\%26$  to  $\%50$  is fair and equal or less than  $\%25$  is unchanged.

### **Statistics:**

A statistician reviewed the data, using the Mann-Whitney tests and Chi-Square tests. Statistical significance was defined as ( $P < 0.05$ ).

## Results

The minimum follow-up period of both groups was 24 months (range, 24 to 48). The average operative

time was less in cage group (122.4 minutes ranged from 60 to 180) than plate group (129.6 minutes ranged from 90 to 180) with no significant statistical difference between the two groups (P=0.47). The average blood loss was significantly less in cage group (388 CC ranged from 200 to 700) than plate group (529.6 CC ranged from 300 to 800) (P=0.01) (Figure 2).

**Radiological Results:**

**Local Kyphotic Angle (LKA):**

In cage group, the average LKA improved significantly from -5) °1.32 to 4) preoperatively to 12-) °7.08- to 2-) immediately postoperative and 10-) °5.44- to 0) at latest follow up (P<0.05). This means the average degree of angle gain was °8.40 postoperatively and that of angle loss was °1.64 at latest follow up. In plate group, the average LKA improved significantly from 3-) °1.05 to 4) preoperatively to 10-) °5.91- to 0) immediately postoperative and 8-) °4.32- to 1) at latest follow up (P<0.05). This means the degree of angle gain was °6.96 postoperatively and angle loss was °1.59 at last follow up. There was no significant difference between the two groups (P> 0.05) (Figure 3) (Table 2).

**Fusion:**

According to Brantigan criteria<sup>5</sup>, fusion was considered certain in 79 out of 84 levels (%94.1) at latest follow up of cage group while it was certain in 67 out of 71 levels (%94.4). There was no significant difference between the two groups (P=0.701).

**Subsidence:**

There was relatively more subsidence in cage (%21.4) than plate group (%11.3) without significant statistical difference (P=0.338).

**Adjacent disc degeneration (ADD):**

It was relatively more in plate group (%40.9) than cage group (%28) without significant statistical difference

between the two groups (P=0.351).

**Clinical Results:**

There was significant improvement in Nurick grading of both cage and plate groups as it improved from 3.32 (2-5) and 3.68 (2-5) preoperatively to 0.0-5) 84) and 5-0) 1.05) at latest follow up in order (P<0.05). There was no significant difference between the two groups (P>0.05). There was significant improvement in VAS of neck pain of both cage and plate group as it improved from 6.64 (5-8) and 7.05 (5-9) preoperatively to 1.68 (4-1) and 1.55 (1-3) at latest follow up in order (P<0.05). Similarly, there was significant improvement in VAS of arm pain as it improved from 8-0) 5.32) and 8-0) 4) preoperatively to 3-0) 1.04) and 0.77 (0-4) at latest follow up in order (P<0.05). There was no significant difference between the two groups (P>0.05) (Figure 4) (Table 3).

**Functional Results:**

In both cage and plate groups, there was significant improvement in modified JOA score from 7.2 (2-10) and 5.27 (1-11) preoperatively to 16-9) 13.48) and 12.27 (8-16) in order at latest follow up (P<0.05) with no significant difference between the two groups. Similarly, there was insignificant difference in (RR) between the two groups. Final outcome was comparable in both groups: In cage group, 7 patients were excellent, 16 were good, and 2 were fair. In plate group, 8 patients were excellent, 11 were good, and 3 were fair (Table 4) (Figure 5). Figure 6,7 are representative of two of our patients for both group of patients.

**Morbidity:**

Dysphagia more than 3 months in 4 patients (18.2 %) and donor site pain more than one year was recorded in 6 patients (27.3 %) in plate group.

**Table (1):**  
Demographic Data and Surgical Levels of Both Groups.

	Cage group	Plate group
<b>Number</b>	25	22
<b>Age (years)</b>	47.72(35-64)	49.27(33-70)
<b>Male</b>	14(56%)	13(59.1%)
<b>Female</b>	11(44%)	9(40.9%)
<b>Radiculopathy</b>	9(36%)	7(31.8%)
<b>Myelopathy</b>	6(24%)	7(31.8%)
<b>Radiculomyelopathy</b>	10(40%)	8(36.4%)
<b>All disc levels</b>	84	71
<b>3-level patients</b>	16(64%)	17(77.3%)
<b>4-level patients</b>	9(36%)	5(22.7%)

**Table (2):**  
Radiological  
Results.

	Cage group	Plate group	P3 value
<b>LKA: Preoperative</b>	1.32°(-5 to 4)	1.05(-3 to 4)	0.648
<b>Postoperative</b>	-7.08°(-12 to -2)	-5.91(-10 to 0)	0.112
<b>P1 value</b>	0,000*	0,000*	
<b>LKA: Last follow up</b>	-5.44°(-10 to 0)	-4.32°(-8 to 1)	0.166
<b>P2 value</b>	0,000*	0,000*	
<b>Fusion/level</b>	79/84(94.1%)	67/71levels (94.4%)	P=0.701
<b>Subsidence/level</b>	18/84(21.4%)	8/71 levels (11.3%)	P=0.338
<b>ADD/patients</b>	7(28%)	9 patients (40.9%)	P=0.351

P: Chai Square, \* Statistical significant difference (P < 0.05), ADD: Adjacent disc degeneration, LKA: local kyphotic angle

P1: comparison between pre and post in each group (Wilcoxon Signed Ranks test).

P2: Comparison between post and last in each group (Wilcoxon Signed Ranks test).

P3: Comparison between cage and plate group (Mann Whitney test).

**Table (3):**  
Clinical Results.

	Cage group	Plate group	P2 value
<b>Nurick grading: Preoperative</b>	3.32 (2-5)	3.68 (2-5)	0.170
<b>Last follow up</b>	0.84 (0-5)	1.05 (0-5)	0.515
<b>P1value</b>	0.000*	0.000*	
<b>VAS(neck): Preoperative</b>	6.64 (5-8)	7.05 (5-9)	0.330
<b>Last follow up</b>	1.68 (1-4)	1.55(1-3)	0.619
<b>P1 value</b>	0.000*	0.000*	
<b>VAS(arm): Preoperative</b>	5.32 (0-8)	4 (0-8)	0.130
<b>Last follow up</b>	1.04 (0-3)	0.77(0-4)	0.230
<b>P1 value</b>	0.000*	0.000*	

P1: comparison between pre and last in each group (Wilcoxon Signed Rancks test).

P2: Comparison between cage and plate group (Mann Whitney test).

\* Statistical significant difference (P < 0.05).

**Table (4):**  
Functional  
Outcomes.

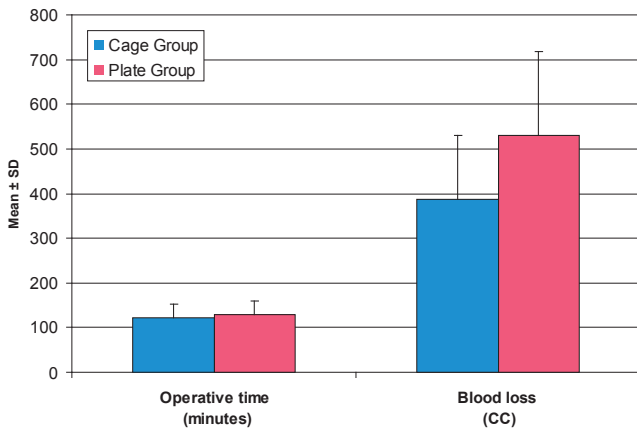

	Cage group	Plate group	P2 value
<b>JOA score: Preoperative</b>	7.2(2-10)	5.27(1-11)	0.107
<b>Last follow up</b>	13.48(9-16)	12.27(8-16)	0.348
<b>P1 value</b>	0.000*	0.000*	
<b>RR</b>	66.42(46.7-87.5)	62.86(40-88.9)	0.347
<b>Outcomes: Excellent</b>	7(28%)	8(36.4%)	
<b>Good</b>	16(64%)	11(50%)	
<b>Fair</b>	2(8%)	3(13.6%)	
<b>Unchanged</b>	0	0	

P1: comparison between pre and last in each group (Wilcoxon Signed Rancks test).

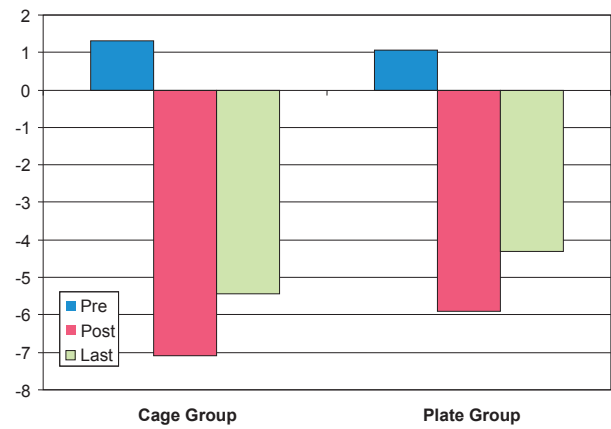
P2: Comparison between cage and plate group (Mann Whitney test).

\* Statistical significant difference (P < 0.05).

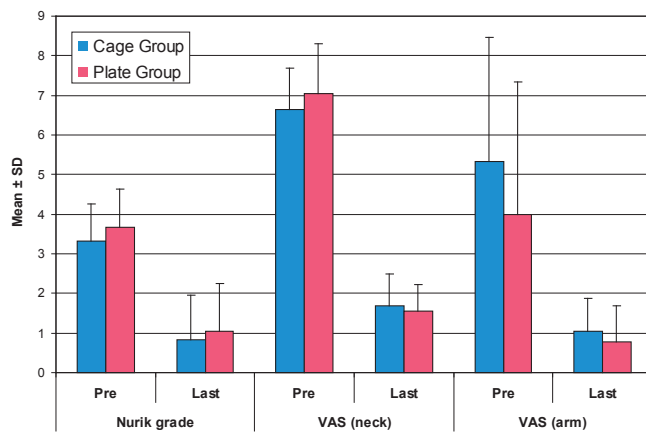
**Figure 1.**  
It shows (A) the anterior locking plate and (B) the PEEK cages used in this study.



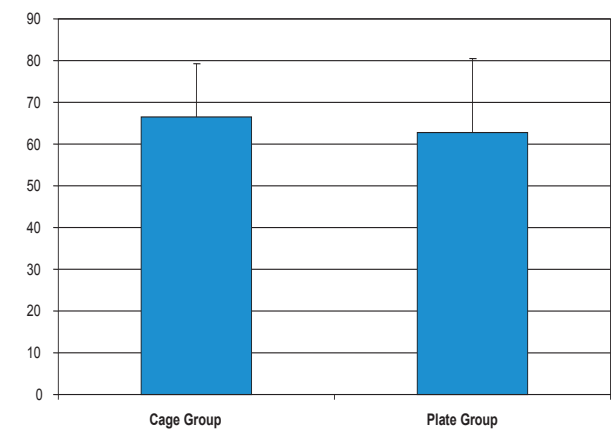
**Figure 2.** Operative time and blood loss in both groups.



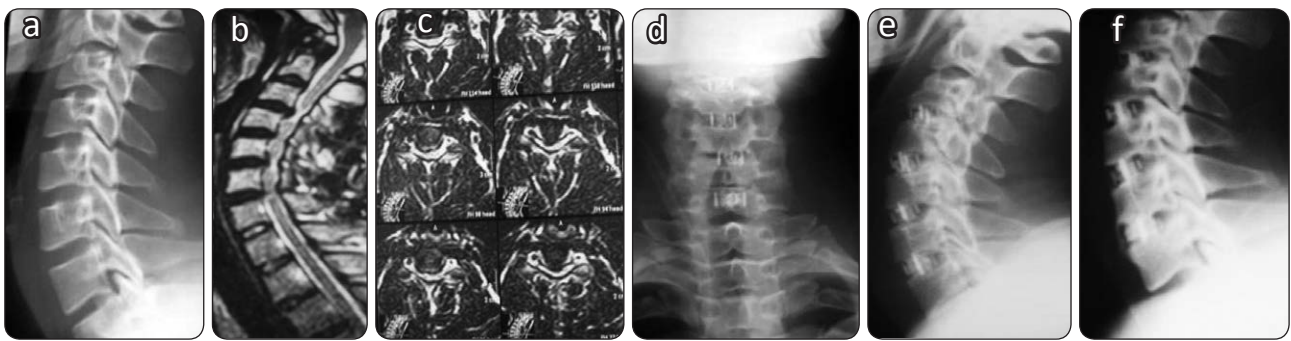
**Figure 3.** Preoperative, postoperative, and last follow up LKA of both groups (mean).



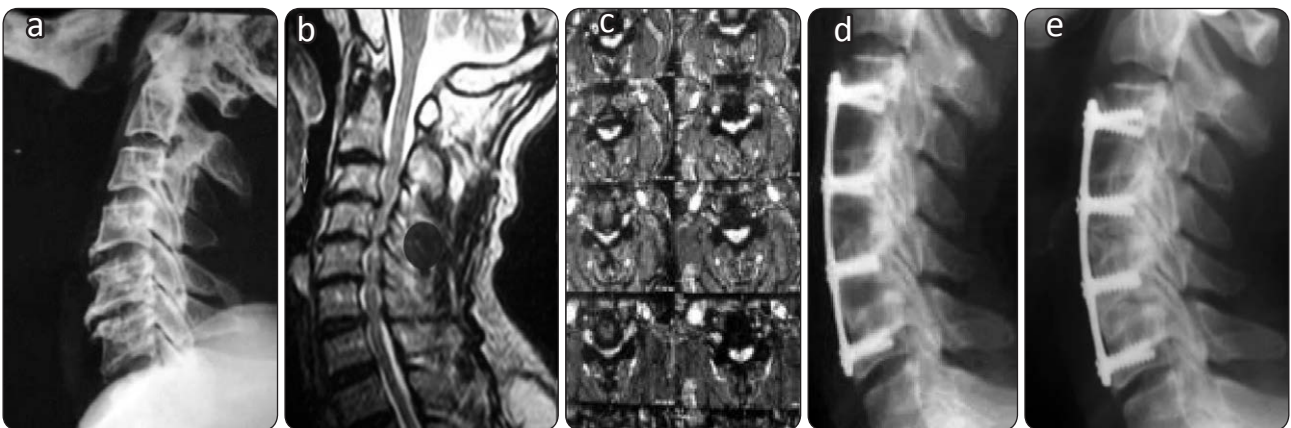
**Figure 4.** Clinical results of cage and plate groups (mean).



**Figure 5.** Recovery ratio (RR) of both cage and plate groups (mean).



**Figure 6.** Female patient, 53year old, Nurick grade4, (A): Preoperative plain X ray lateral view, MRI (B) sagittal and (C) axial views showing severe canal stenosis, multiple disc lesions (C34,C45,C56,C67) with severe cord compression and cord malacia, postoperative plain X ray (D) anteroposterior, (E) lateral views, and (F), latest follow up lateral view showing no subsidence, sound fusion after 4 levels ACF with cage. Nurick 2, RR 85.7% (excellent).



**Figure 7.** Male patient, 65 year old, Nurick 4 (A): Preoperative plain X ray lateral view, MRI (B) sagittal and (C) axial views showing severe canal stenosis, multiple disc lesions (C34,C45,C56) with severe cord compression and cord malacia, postoperative plain X ray (D) lateral views, and (E), latest follow up lateral view showing no subsidence, sound fusion after 3 levels ACF and plating. Nurick 3, RR 88.5% (excellent).

## Discussion

Anterior cervical discectomy and interbody fusion (ACF) has been the standard treatment for cervical DDD for more than 50 years.<sup>29</sup> There is no clear consensus regarding the optimal surgical procedure for cervical DDD.<sup>18,30,31</sup> Multiple levels ACF still remain a difficult problem. Autogenous iliac bone graft does not maintain spinal stability very well and the complications are higher than at the single level.<sup>34,38</sup> Moreover, it has been reported that even with solid fusion, kyphosis often develops in multilevel discectomies with autogenous iliac bone graft fusion.<sup>9,20</sup> Augmentation with plate fixation may be preferable in multilevel ACF as plate fixation may decrease the micromovement of the cervical spine, enhance the fusion rate and correct spinal

curve to physiological lordosis).<sup>32,35</sup> However, plate complication rate varies from <sup>11,19,21,22,39</sup> %24-2.2 These complications favored ongoing development of cage technology.

Different types of cages are available to perform ACF; including titanium cage, carbon fiber reinforced polymer (CFRP) cages, and polyether ether ketone (PEEK) cages. The absence of cytotoxicity and mutagenicity were demonstrated for PEEK cage in an in vitro study. It provides combination of strength, stiffness, toughness, and environmental resistance.<sup>7</sup> Moreover, the modulus of elasticity of PEEK is similar to that of bone and the volume related stiffness of the PEEK cage is higher than that of iliac bone in all direction. These results show that PEEK could be manufactured as the optimal

interbody spacer, providing an adequate volume for bone refilling and immediate mechanical stability in ACF.<sup>13,24,40</sup> Additionally, BEEK cage is radiolucent and allowing the surgeon to evaluate easily fusion status on radiograph or CT scans.<sup>7</sup> Because of these previous advantages of PEEK cage, we used it in last 25 patients in this study compared with locking plate in ACF technique for treatment patients with multilevel cervical DDD.

In this study, there was significant correction of LKA in both cage and plate groups postoperatively and latest follow up with no significant difference between the two groups. This was comparable with Yong et al,<sup>41</sup> series. Barsa et al,<sup>3</sup> observed cage subsidence rate (%14). Higher cage subsidence rate (%44.8) was reported in the series of Schmieder et al,<sup>34</sup> who used titanium cages. However, none of their cases required revision surgery despite of their higher subsidence rate because cervical lordosis was radiologically present throughout follow up. These reports illustrated a possible discrepancy between radiological apparent cage subsidence and clinical relevance of these findings. This study reported relatively more subsidence incidence in cage group (%21.4) than plate group (%11.3) without significant statistical difference. This may attributed to increased stability and maintenance of cervical lordosis with the use of plate fixation.

Yong et al,<sup>41</sup> reported insignificant difference in fusion rate between cage (%90.9) and plate (%95) groups. Similar results was reported in this study in which fusion rate was (%94.1) and (%94.4) in both cage and plate groups in order. Reversely, many authors<sup>3,21</sup> reported better fusion rate in plate group. They believed that insufficient fixation power of cage alone in multiple levels ACF allowing continuous postoperative micromotion preventing the induction of bone fusion. However, this postoperative micromotion decreases insignificantly the incidence of adjacent disc degeneration in cage group (28 %) compared with plate group (%40) in our study. Song et al,<sup>37</sup> reported that rigid fixation with plate reduces segmental motion and causes high stress on the disc below and above the fusion site during cervical motion which leads to adjacent level degeneration.

This study reported significant clinical improvement in Nurick grade, and VAS of neck and arm pain of both cage and plate groups at latest follow

up compared with preoperative scores without significant difference between the two groups. Similarly, there was insignificant difference in operative time. However, there was significant less blood loss in cage than plate group. Yong et al,<sup>41</sup> reported shorter operative and less blood loss in cage group. Previous studies<sup>13,24</sup> have reported donor-site morbidity from %9.4 to %49 including pain, infection, seroma, and fracture etc. In this study, 6 patients (%27.3) demonstrated postoperative donor site pain which improved within one year and %18.2) 4) developed dysphagia which improved within 4 months in plate group. Similarly, Kyung et al,<sup>23</sup> who used plates in his series reported 4 patients (%4.8) developed dysphagia which improved within 3 months. As a result of this significant radiological and clinical improvement, the final functional outcomes including, modified Japanese Orthopedic Association (JOA) score and recovery ratio (RR) improved significantly in both groups at latest follow up without significant statistical difference.

## Conclusion

In multiple levels (three or more) ACF, the use of stand-alone PEEK cages results in less blood loss, less adjacent disc degeneration, less complication than the use of autograft augmented with locked plate but unfortunately more incidence of subsidence. However, there is no significant difference in the postoperative and latest follow up LKA, fusion rate, clinical, and functional outcomes between the cage and plate groups.

## References

- 1) Bagbay GW: Arthrodesis by distraction-compression method using a stainless steel implant. *Orthopedics* 1988 ,934-11:931
- 2) Bailey RW, Badgley CE: Stabilization of the cervical spine by anterior fusion . *J Bone Joint Surg (Am)* 1960 ,594-42:565
- 3) Barsa B, Suchromel P: Factors affecting sagittal mal-alignment due to cage subsidence in stand-alone cage assisted anterior cervical fusion. *Eur Spine J* 2007 ,1400-1395 :16
- 4) Bartolozzi P, Salvi M: Anterior surgery of the lower cervical spine. *Chir Organi Mov* ,85-77:81 1992
- 5) Brantigan JW, Steffe AD: A carbon fiber implant to aid interbody lumbar fusion. Two-year clinical

- results in the first 26 patients. *Spine* 18:2106-2107, 1993
- 6) Briggs M, Closs JS: A distributive study of the use of Visual Analogue Scale and vertebral rating scale for assessment of postoperative pain in orthopedic pain. *J Pain Symptom Management* 18:1999 ,446-438
  - 7) Cho DY, Liau WR, Lee WY, Liu JT, Chiu CL, Sheu PC: Preliminary experience using a polyetheretherketone (PEEK) cage in the treatment of cervical disc disease. *Neurosurgery* 2002 ,1350-51:1343
  - 8) Cloward RB: The anterior approach for removal of ruptured cervical disks. *J Neurosurg* -15:602 1958 ,617
  - 9) Colac A, Kutlay M, Tosali L: Three-level cervical discectomy and fusion without internal fixation. *Turkish Neurosurg* 2000 ,130-10:126
  - 10) Edward CC, Heller JG, Silcox DH: T-saw laminoplasty for the management of cervical spondylotic myelopathy. *Spine* ,1794-25:1788 2000
  - 11) Emery SE, Fisher RS, Bohlman HH: Three-level anterior cervical discectomy and fusion. *Spine* 1997 ,2625-22:2622
  - 12) Gercek E, Arlet V, Delisle J, Marchesi D: Subsidence of stand-alone cervical cages in anterior interbody fusion: Warning. *Eur Spine* 12(5):513-516, 2003
  - 13) Gu YT, Jia LS, Chen TY: Biomechanical study of a hat type cervical intervertebral fusion cage. *Int Orthop* 2007 ,105-101:(1)31
  - 14) Ha SK, Park JY, Kim SH, Lim DJ, Kim SD, Lee SK: Radiological assessment of subsidence in stand-alone cervical Polyetheretherketone (PEEK) cage. *J Korean Neurosurg Soc* 2008 ,374-44:370
  - 15) Hilibrand AS, Carlson GD, Palumbo MA, Jones PK, Bohlman HH: Radiculopathy and myelopathy at segments adjacent to the site of previous anterior cervical arthrodesis . *J Bone Joint Surg (Am)* 1999 ,528-81:519
  - 16) Hirabayashi K, Watanabe K, Wakano K, Suzuki N, Satomi K, Ishii Y: Expansive open- door laminoplasty for cervical spinal stenotic myelopathy. *Spine* 1983 ,699-8:693
  - 17) Hwang S, Lin C, Lieu A, Lee K, Kuo T, Hwang Y, Su Y, Howing S: Three-level and four-level anterior cervical discectomies and titanium cage-augmented fusion with and without plate fixation. *J Neurosurg* 2:160-167, 2004
  - 18) Jacob WC, Anderson PG, Limbeek J, willems PK, Pavlov P: Single or double-level anterior inter body fusion technique for cervical degenerative disc disease. *Cochrane Database Rev*, 2004
  - 19) Kaiser MG, Haid RW, suback BR, Barnes B, Rodts GE: Anterior cervical plating enhances arthrodesis after discectomy and fusion with cortical allograft. *Neurosurgery* ,235-25:229 2002
  - 20) Katsuura A, Huku S, Imanaka T, Miyamoto K, Kanemoto M: Anterior cervical plate used in degenerative disease can maintain lordosis. *J Spinal Disord* 1996 ,476-9:470
  - 21) Katzer A, Marquard H, Westendorf J, Wening JV, Forster G: Polyetheretherketone cytotoxicity and mutagenicity invitro. *Biomaterials* 2002 ,1759-1749:(8)23
  - 22) Kostuik JP, Connolly PJ, Esses SL, Sub P: Anterior cervical plate fixation with the titanium hollow screw plate system. *Spine* 1993 ,1278-18:1273
  - 23) Kyung JS, Cyrus GT, Margaret SH, Kwang BL, GYU HK, JI HS: Plate augmentation in anterior cervical discectomy and Fusion with cage for degenerative cervical spinal disorders. *Eur Spine J* 19 (2010 ,1683-1677:(10
  - 24) Liao JC, Niu CC, Chen WJ, Chen LH: Polyetheretherketone (PEEK) cage filled with cancellous allograft in anterior cervical discectomy and fusion. *Int Orthop* -643:(5)32 2008 ,648
  - 25) Majd ME, Vadhava M, Holt RT: Anterior cervical reconstruction using titanium cage with anterior plating. *Spine* 1999 ,1610-24:1604
  - 26) Mohamed GH: Anterior discectomy and fusion for cervical spondylotic myelopathy. MD thesis Assiut University, 1990
  - 27) Nurick S: The natural history and the results of surgical treatment of the spinal cord disorder associated with cervical spondylosis. *Brain* 1972 ,108-95:101
  - 28) Robertson JT, Papadopoulos SM, Traynelis VC: Assessment of adjacent-segment disease in patients treated with cervical fusion or arthroplasty-2 years study. *J Neurosurg Spine* 3:417-423, 2005
  - 29) Robinson RA, Smith GW: Anterolateral cervical disc removal and interbody fusion for cervical disk syndrome. *Bull Johns Hopkins Hosp* -96:223



- 1955 ,224
- 30) Smith GW, Robinson RA: The treatment of certain-spine disorders by anterior removal of the intervertebral disc and interbody fusion. *J Bone Joint Surg (Am)* -40A:1958 ,624-607
- 31) Samartzis D, Shen FH, Lyon C, Philips M, Goldenberg EJ, An HS: Does rigid anterior instrumentation increase the fusion rate in one-level anterior cervical discectomy and fusion? *Spine J* 2004 ,643-4:636
- 32) Samartzis D, Shen FH, Matthews DK, Yoon ST, Goldenberg EJ, An HS: Comparison of allograft to autograft in multilevel anterior cervical discectomy and fusion with rigid plate fixation. *Spine J* 2003 ,459-3:451
- 33) Sampath P, Bendebba M, Davis JD, Bucter TB: Outcomes of patients treated for cervical myelopathy: a prospective multicenter study with independent clinical view. *Spine* -25:670 2000 ,676
- 34) Schmider K, Wolzik GM, Pechlivanis I, Engelhardt M, Scholz M, Harder A: Subsidence of the wing titanium cage after anterior cervical interbody fusion: 2-years follow up. *J Neurosurg Spine* 2006 ,453-4:447
- 35) Shapiro s, Connolly P, Donaldson J, Abel T: Cadaveric fibula, locked plate, and allogenic bone matrix for anterior cervical fusion after cervical discectomy for radiculopathy or myelopathy. *J Neurosurg* 2001 ,50-95:43
- 36) Silber JS, Anderson DG, Daffner SD: Donor site morbidity after anterior iliac crest bone harvest for single-level anterior cervical discectomy and fusion. *Spine* 2003 ,139-28:134
- 37) Song KJ, Kim GH, Choi BW, Lee KB: Does plate construct improve the result of 1-2 level anterior cervical fusion ? *Neurosurg Q* 2008 ,177-18:172
- 38) Varruch, Hedlund R, javid D, Leszniewski W, Shalabi A: A prospective randomized comparison between the Cloward procedure and a carbon fiber cage in the cervical spine: A clinical and radiological study. *Spine* 27:-1694 2002 ,1701
- 39) Wang JC, McDonough PW, Endo KK, Delamarter RB: Increased fusion rates with cervical plating for three-level anterior cervical discectomy and fusion. *Spine* 2001 ,647-26:643
- 40) Wenz LM, Merritt K, Brown SA, Moet A, Steffe AD: Invitro biocompatibility of polyetheretherketone and polysalfon composites. *J Biomed Mater Res* 24(2):1990 ,215-207
- 41) Yong HJ, Jong WL, Ki YK, Jong JR, Hyun KL: Comparison of fusion with cage alone and plate instrumentation in two levels cervical degeneration disease. *J Korean Neurosurg Soc* 48(4):342-350, 2000

Address reprint  
request to:

**Khaled M Hassan MD.**

Assiut University Medical School, Assiut, Egypt.

E-mail: khaledhyounes@yahoo.com - Mobile: 01005363318

فعالية أقفاص البيك المستقلة مقابل الشريحة ذاتية القفل في الاستئصال

و الانصهار الأمامي لثلاثة أو أكثر مستويات للغضروف العنقى

البيانات الخلفية: يعتبر الإستئصال الأمامي للغضاريف العنقية مع تثبيت الفقرات هي الطريقة المثالية لعلاج حالات الإنزلاق الغضروفي العنقى سواء تم إستخدام الشرائح الأمامية المعشقة مع الترقيع العظمى أو إستخدام الأقفاص المعدنية المحشوه بفسفات الكالسيوم الثلاثي.

الهدف: الهدف من هذه الدراسة هو مقارنة النتائج المترتبة على هذه الجراحة بين إستخدام الشرائح الأمامية المعشقة مع الترقيع العظمى وبين إستخدام الأقفاص المعدنية المحشوه بفسفات الكالسيوم الثلاثي في حالات الإنزلاق الغضروفي العنقى المتعدد (ثلاثة أو أكثر).

الطريقة: تم تقييم ٤٧ مريضا بالإنزلاق الغضروفي العنقى المتعدد وتم تقسيم المرضى إلى مجموعتين : مجموعة تشمل ٢٥ مريضا تم علاجهم بالشرائح الأمامية مع الترقيع العظمى ومجموعة أخرى تشمل ٢٢ مريضا تم علاجهم بالأقفاص المعدنية المحشوه بفسفات الكالسيوم الثلاثي وتمت مقارنة النتائج الإشعاعية والإكلينيكية والوظيفية في كل من المجموعتين.

النتائج: نتج عن هذه الدراسة: أن ن كمية فقد الدم كانت أقل في مجموعة الأقفاص المعدنية وأن كلا المجموعتين شهدت تحسن ملحوظ في درجة إوجاج الفقرات العنقية دون أى فرق بينهما كان معدل إلتئام الفقرات والتحسن الإكلينيكي متقارب في المجموعتين وكانت النتيجة النهائية في مجموعة الأقفاص المعدنية كما يلي : ممتاز في ٧مرضى و جيد في ١٤ مريض ومقبول في مريضين . أما في مجموعة الشرائح الأمامية المعشقة وكانت النتيجة النهائية في مجموعة الأقفاص المعدنية كما يلي : ممتاز في ٨ مرضى و جيد في ١١ مريض ومقبول في ثلاثة مرضى. الاستنتاج: أستنتج من هذه الدراسة إستخدام الأقفاص المعدنية المحشوه بفسفات الكالسيوم الثلاثي في حالات الإنزلاق الغضروفي العنقى المتعدد (ثلاثة أو أكثر) تسبب فقد أقل للدم و درجة أقل في خشونة الفقرات المجاورة و نسبة اقل في المضاعفات ولكن نسبة أعلى في درجة هبوط الفقرات مقارنة بمجموعة الشرائح الأمامية ولا يوجد أى اختلاف دى مغذى بين المجموعتين في التحسن الإكلينيكي والوظيفي العام للمرضى