

## Atlas Lateral Mass Screw Fixation in Atlanto-Axial Instability, Clinical Case Series

**Mohamed Ali El-Gaidi, MD.**

*Neurosurgery Department, Kasr El-Aini Medical School, Cairo University*

### Abstract

**Background Data:** Segmental spinal screw fixation has been used effectively for subaxial spine instability for long time. However, atlantoaxial fixation is still challenging due to complex topographical anatomy. So, sublaminar wires were frequently used despite their complications. Unlike transarticular atlantoaxial screws which necessitate perfect reduction before insertion, C1 lateral mass screws are inserted independently of C2.

**Purpose:** The aim of this work is to assess the safety and efficiency of C1 lateral mass screw fixation in cases with atlantoaxial instability.

**Study Design:** A prospective clinical case study.

**Patients and Methods:** This study was conducted in Al-Manial university hospital, Kasr Al-Aini Medical School, Cairo University, between 2008 and 2013. Ten patients underwent segmental atlantoaxial screw fixation using atlas lateral mass screws and either transpars interarticularis or transpedicular axis screws. Clinical results were evaluated by using the criteria of Japanese Orthopaedic Association Scoring System for Cervical Myelopathy (JOA score). The surgical technique, results and morbidity and mortality were assessed.

**Results:** There were 6 females and 4 males; the average age was  $30.2 \pm 17.5$  y (range from 4y-61 years). The most common cause of atlantoaxial instability was trauma (6 patients), followed by os odontoideum (2 patients). The most common presentation was quadriparesis (5 patients) followed by neck pain and paresthesia. At the end of follow up (mean  $8.5 \pm 4.2$  months) the average preoperative JOA score improved from  $13.1 \pm 1.9$  to  $15.2 \pm 1.6$  ( $P=0.005$ ) and the average recovery rate was  $48.3 \pm 17.8\%$ . Twenty screws were inserted in lateral mass of atlas successfully. The average screw length was  $27.8 \pm 1.5$ mm (range 24-31mm). Postoperative CT scans showed the mean atlantodens interval improved from  $5.4 \pm 1.9$  to  $1 \pm 1.4$  ( $P=0.004$ ), MRI showed that the mean cervico-medullary angle changed from  $126.2^\circ \pm 9.4^\circ$  to  $141.1^\circ \pm 12.4^\circ$  ( $P=0.005$ ). There was no mortality or vertebral artery injury. One patient had profuse venous bleeding and one unit of blood was transfused and one patient had superficial wound infection and managed conservatively.

**Conclusion:** C1 lateral mass screw fixation is a safe and effective method of atlantoaxial fixation with low complication rate. (2013ESJ052)

**Keywords:** Atlantoaxial instability, C1 fixation, Lateral mass screws

## Introduction

Atlantoaxial instability can be caused by trauma, congenital malformation, inflammatory disorder as rheumatoid arthritis, infection and neoplasms.<sup>2-4,6,8,10,16,20</sup> Clinically and/ or radiologically significant atlantoaxial instability is best treated by reduction and stabilization of the C1–C2 joint.<sup>8,10</sup> Unlike subaxial spine instability, atlantoaxial fixation is still challenging due to complex topographical anatomy.<sup>1,2</sup>

The sublaminar wires/ cables or interlaminar clamps were traditionally used in atlanto axial fixation.<sup>3,7</sup> However, these techniques had lower fusion rates and necessitates intact posterior vertebral components (C1 posterior arch and C2 lamina) and long postoperative rigid neck immobilization.<sup>4,18</sup> Later, the transarticular screw placed from the C2 pars interarticularis into the lateral mass of atlas had major advantages over the traditional wire/cable techniques as they are more rigid, provided higher fusion rates without postoperative halo immobilization.<sup>4,11,16</sup> However, it carries a higher risk of vertebral artery injury and the C1-C2 articulation must be perfectly reduced before attempting transarticular screw insertion.<sup>1,17</sup>

Goel and Laheri<sup>8</sup> revolutionized atlantoaxial fixation using C1 lateral mass screws and C2 pedicle screws with a plate construct in 1994. Harms and Melcher, popularized this technique by using polyaxial screws and rod construct.<sup>10</sup> Unlike transarticular screws, the lateral mass screws of C1 provide segmental fixation. So, they are placed independently on C2 screws.<sup>6, 8,10,14,20</sup>

In this study, the surgical technique and the results including the complications of C1 lateral mass screws in 10 patients with atlantoaxial instability will be described.

## Patients and Methods

This was a prospective study conducted in Al-Manial university hospital, Kasr Al-Aini Medical School, Cairo University, between September 2008 and February 2013. Ten patients with atlantoaxial instability underwent posterior segmental atlantoaxial screw fixation via atlas lateral mass screws and either transpedicular or transpars interarticularis of axis vertebra.

All patients were subjected to detailed history taking and full general and neurological examination.

The Japanese Orthopaedic Association Scoring System for Cervical Myelopathy (JOA score)<sup>13</sup> was used for clinical evaluation of the patient pre and postoperatively. Preoperative radiographic investigations included plain x-ray cervical spine (Anteroposterior, lateral neutral and open mouth views) and Computed tomography scan (CT) with coronal and sagittal reconstruction and Magnetic Resonance Imaging (MRI) of cervical spine (all imaging modalities should clearly show cranio-cervical junction).

Unless patients presented in acute trauma, patients underwent dynamic radiological investigations (flexion and extension views plain x-rays, CT and or MRI cranio-cervical junction) but not to the extent causing much neck pain or brachialgia or neurological deterioration and under medical supervision with the patients wearing their rigid neck collars but were slightly untightened. The dynamic views were important not only to address the atlantoaxial instability and elucidate the reducibility and best position of fixation during surgery but also to exclude associated occipito-cervical instability not apparent on static views which necessitates occipitocervical fixation. Postoperatively, plain x-rays (including dynamic views) and CT scans were routinely performed to assess the screws and reduction.

The recovery rate was calculated according to Hirabayashi et al,<sup>12</sup> formula:

Recovery rate = (Postoperative JOA score - Preoperative JOA score) / (Normal score (17) - Preoperative JOA score) × 100/1

## Statistical Analysis:

Data were statistically described in terms of mean ± standard deviation (± SD), and range. Comparison between pre and postoperative values was done using Wilcoxon signed rank test for paired (matched) samples. Correlation between various variables was done using Pearson moment correlation equation for linear relation in normally distributed variables and Spearman rank correlation equation for non-normal variables. *p* values less than 0.05 was considered statistically significant. All statistical calculations were done using computer program SPSS (Statistical Package for the Social Science; SPSS Inc., Chicago, IL, USA) release 15 for Microsoft Windows (2006).

### **Surgical Technique:**

The patient was placed in the prone position with a head holder under cervical traction in mild extension (after assessment of preoperative imaging), and the arms were tucked on both sides. The head was elevated up 15° to ease venous return. The ligamentum nuchae was divided and occipitocervical musculature was stripped subperiosteally from the occipital bone and posterior arch of C-1 and C-2 lamina and retracted laterally exposing the lateral margin of C2/C3 facets bilaterally.

C2 neurectomy was done bilaterally to expose the C2 pars-interarticularis, the atlantoaxial joint and the inferior articular facet of the lateral mass of atlas. At this stage, there was profuse venous bleeding from the venous plexus surrounding C2 roots which was controlled by bipolar coagulation and by using haemostatic agents. The articular facets of the C1-2 joints were dissected bilaterally and the joint capsule was widely removed by using a microdrill, and pieces of bone grafts harvested from the iliac crest were packed into the joints.

The entry point of C1 lateral mass screw located at the center of the lateral mass of atlas midway between the articular surface and the intersection of the posterior arch of the C1 and the inferior articular process of the C1 lateral mass. The entry point was drilled with a 3-mm drill bit adopting 15° medial and 15° cephalic angulations. C1 posterior arch was taken as a reference point for the C1 screw trajectory on the cephalic plane which may be checked by lateral fluoroscopy (when necessary but not routinely) aiming to the anterior tubercle of C1 anterior arch. Drilling continued gradually and cautiously until the drill bit just penetrated the anterior cortex of the C1 vertebra thus achieving bicortical purchase. After tapping, polyaxial screws of 3.5-mm diameter were used (Vertex, Medtronic Sofamor Danek, Memphis, Tenn) (Figure 1).

Because of the overlying posterior arch of the C1, longer screws (24-31mm polyaxial screws) were used to achieve easy adaptation of the rod connected to C2 screw. It is worth mentioning that C2 screws were inserted either trans-pars interarticularis (Figure 2,3) or transpedicular (Figure 4,5). The instrumentation was finalized with fixation of the rods on the heads of the polyaxial screws after distraction or manipulation of the C1 and C2 vertebrae individually to achieve satisfactory reduction if needed.

Patients were instructed to wear neck collar for 8 weeks and the patients were followed up every 3 months. All the patients under went dynamic radiographs (flexion and extension lateral view X-rays).

## **Results**

There was slight female predominance (M/F = 4/6) and the average age of patients at time of surgery was 30.2 ±17.5 years (range; 4-61 years) (Table 1). The average duration of symptoms was 12.7 ±11m (range; 0.1-36 months). The most common cause of atlantoaxial instability was trauma (6 patients), followed by os odontoideum (2 patients <15 years), rheumatoid arthritis and post tuberculous infection (one patient each). The most common presentation was weakness (5 patients) followed by neck pain and paresthesia.

No intraoperative mortality, vertebral artery injury, spinal cord injury or cerebrospinal fluid leakage occurred during screw insertion. The average operative time was 149±33 (115-235) minutes, and average blood loss was 250±72 (100-600) ml.

The average duration of follow-up after surgery was 13.5±4.2 (range; 6-18 months). The average preoperative JOA score of the patients showed improvement from 13.1±1.9 (range: 10-16) to 15.2±1.6 (range: 13-16.5) at the final follow up. This improvement in the JOA score was statistically significant by using Wilcoxon signed rank test (P=0.005). The average recovery rate was 48.3±17.8% (range: 25-82%) (Table 2).

The position of 19 atlantal lateral mass screws (95%) were satisfactory as noted on postoperative CT scans (Figure 2-5), while in one screw in one patient with rotational atlantoaxial instability who experienced improvement of quadriparesis, was misdirected upward excessively and penetrated through both the lateral mass of atlas and the occipital condyle without injuring the hypoglossal nerve, vertebral artery or any other structures, so revision surgery was not considered.

Postoperative CT scans showed the mean atlantodens interval improved from 5.4±1.9 to 1±1.4 (P=0.004), MRI showed that the mean cervicomedullary angle changed from 126.2°±9.4° to 141.1°±12.4° (P=0.005).

Analysis of the postoperative results showed significant positive correlation between the

postoperative JOA score and the preoperative JOA score (Pearson correlation was 0.78, P=0.008). However there was no other significant correlation between the postoperative JOA score and the other pre/postoperative variables.

Neither construct failure nor loosening of the screws was observed. No implant failures or sliding in flexion and extension was observed on the dynamic

plain x-rays within the follow up period. Mild occipital hypoesthesia was observed in 2 patients (20%) postoperatively due to C2 neurectomy, which decreased gradually in the follow-up period. None of the patients had excessive discomfort such as headache or neuralgia. One patient had superficial wound infection was treated conservatively with antibiotics.

**Table 1.** Preoperative Clinical Data and Postoperative Complications.

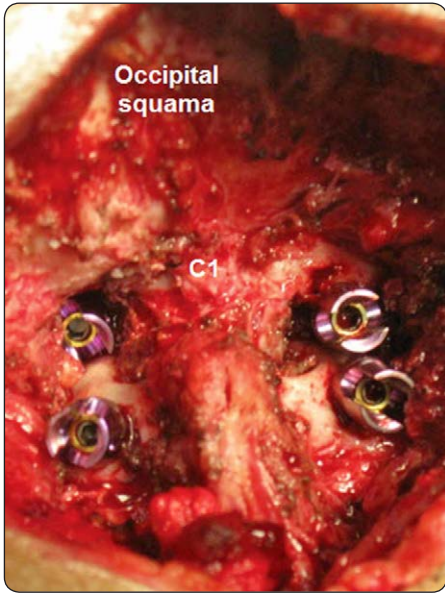No.	Age	Sex	Diagnosis	Presentation	Duration (m)	Complications
1	4	F	Os Odontoideum	Quadripareisis	24	Superficial wound infection
2	13	F	Os Odontoideum	Neck pain	6	-
3	18	M	Type II odontoid fracture	Neck pain	10	Profuse bleeding
4	23	F	Type II odontoid fracture	Quadripareisis, paresthesia	11	-
5	24	M	Type II odontoid fracture	Paresthesia, Precipitancy	9	-
6	29	F	TB→ basilar invagination	Quadripareisis	13	Penetration of occipital condyle
7	39	M	Type II odontoid fracture	Spasticity, paresthesia	0.1	-
8	41	F	Type II odontoid fracture + J F	Quadripareisis, neck pain	36	-
9	50	F	RA→ basilar invagination	Spasticity	18	-
10	61	M	Type II odontoid fracture	Quadripareisis	0.25	-

(JF; Jefferson fracture, RA; rheumatoid arthritis, TB; tuberculosis)

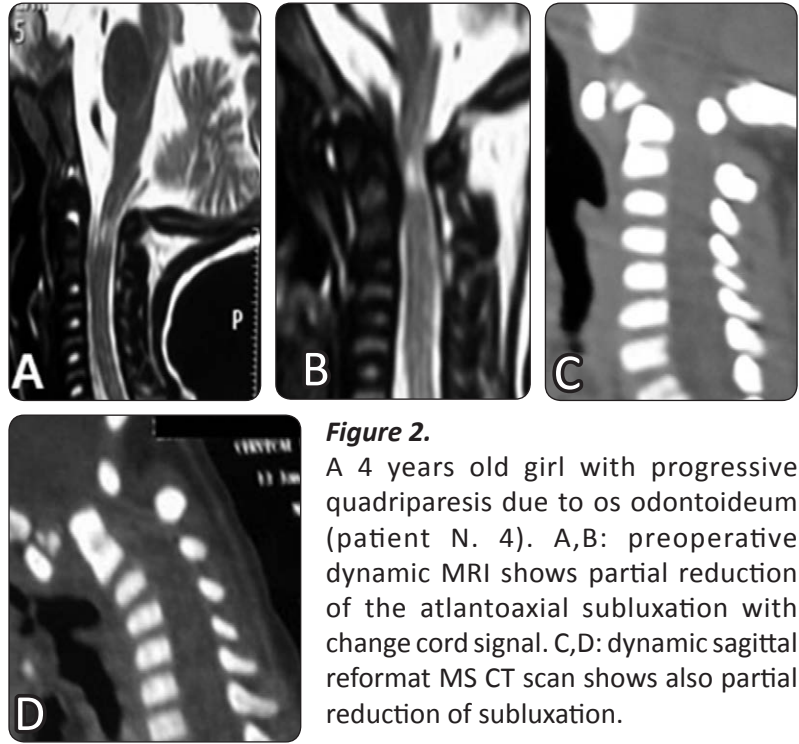
**Table 2.** Results of Used Parameters for Assessment of Clinical and Radiological Outcome.

No.	PreOp JOS	PostOp JOS	Recovery rate	PreOp ADI (mm)	PostOp ADI (mm)	PreOp CM°	PostOp CM°
1	10	13	42.9%	8	4	152	173
2	16	16.5	50%	4	0	121	140
3	14	15	33.3%	6	0	127	133
4	11	14	50%	4	1	125	139
5	15	16.5	25%	3	0	130	140
6	11.5	16	81.8%	6	0	124	142
7	13.5	14.5	28.6%	5	1	126	136
8	13.5	16	71.4%	9	3	118	125
9	14	15.5	50%	5	1	120	140
10	12	14.5	50%	4	0	119	143

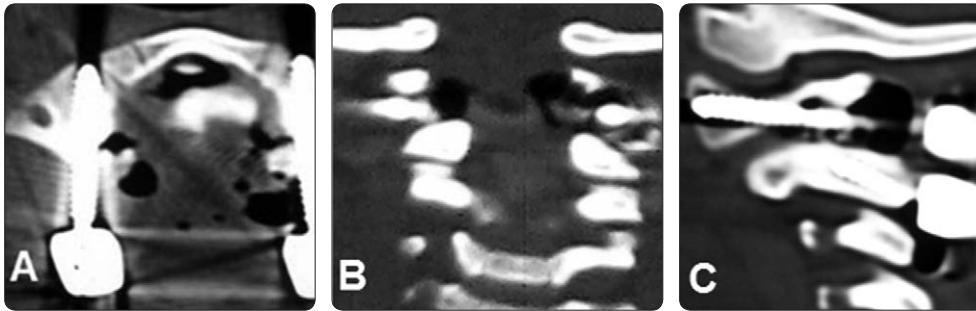
(preOp: preoperative, posOp: postoperative, ADI: atlantodental interval, CM: cervicomedullary angle, JOS: Japanese orthopedic score)



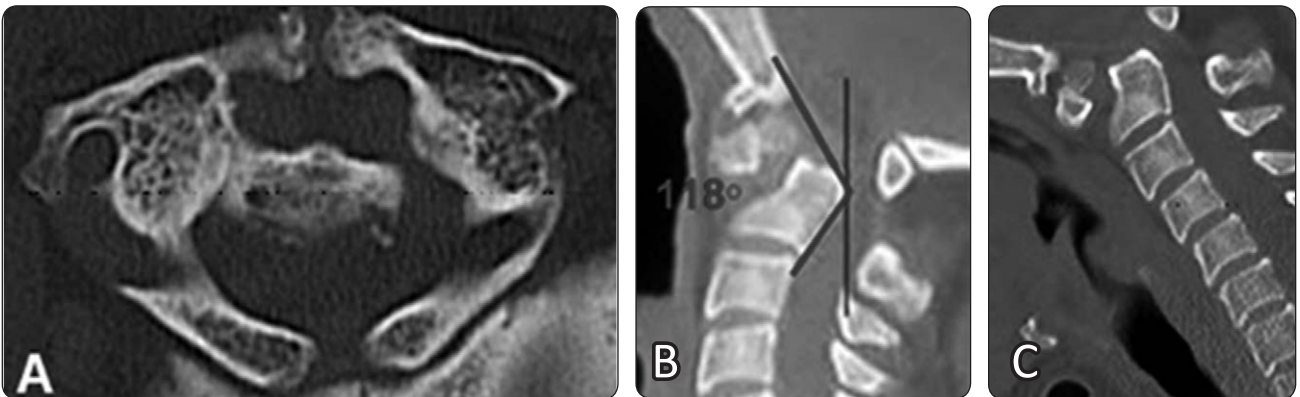
**Figure 1.** Intraoperative photograph demonstrating final positions of C1 lateral mass polyaxial screws and C2 screws.



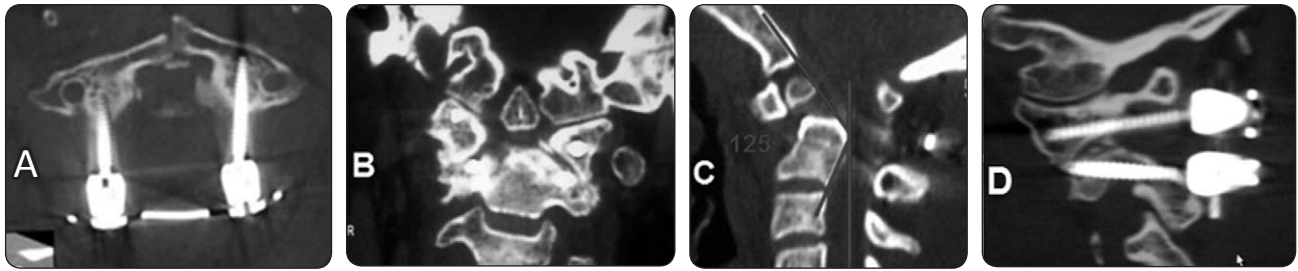
**Figure 2.** A 4 years old girl with progressive quadriparesis due to os odontoideum (patient N. 4). A,B: preoperative dynamic MRI shows partial reduction of the atlantoaxial subluxation with change cord signal. C,D: dynamic sagittal reformat MS CT scan shows also partial reduction of subluxation.



**Figure 3.** A postoperative imaging of the same patient N. 4; A) axial, B) coronal and C) sagittal views CT scan showing good placement of C1 lateral mass screws and C2 trans pars screws.



**Figure 4.** A preoperative imaging of a 41 years old female patient presented with progressive quadriparesis (III/V) after RTA 8 m ago (patient N.8); A) axial CT scan revealed associated non-united Jefferson fracture while dynamic sagittal CT scans during both extension (B) and flexion (C) showed no reduction of the C1-2 subluxation with significant canal compromise.



**Figure 5.** A postoperative CT imaging of the same patient N. 8; A) axial view showing the good position of lateral mass screws bilaterally (note the transverse rod connector), B) coronal view and C) Mid-sagittal view showing partial reduction of base of odontoid and improvement of canal compromise after fixation in comparison with preoperative sagittal CT scan (figure. 4B), D), sagittal view showing the placement of C1 lateral mass and C2 pedicle screws. This patient has improvement of motor power (IV+/V) at 6 m follow up.

## Discussion

Many techniques are currently available for the C1-C2 fixation. However, they have many limitations. The posterior wiring techniques cannot be used when the posterior arch is disrupted congenitally, surgically or after trauma. Moreover, they do not provide rigid fixation so, long postoperative rigid neck immobilization is mandatory.<sup>2,4,7,10,11,18</sup>

Magrel C1-C2 transarticular screws provided more rigid fixation than previous wiring techniques.<sup>11</sup> However, the use of C1-C2 transarticular screws, is precluded in approximately 20% of the cases because of a high arched vertebral artery, and in 3% of patients, the vertebral artery anatomy will preclude safe screw insertion bilaterally.<sup>1,17</sup> Moreover, irreducible C1-C2 subluxation, and severe cervico-thoracic kyphosis, will likewise preclude their optimal placement.<sup>8,10</sup>

The use of C1 lateral mass screws was first described by Goel and Laheri<sup>8</sup> represent an important advancement in spinal surgery. Harms and Melcher<sup>10</sup> have popularized this technique by using polyaxial screws and rods. Hence, atlantal lateral mass screw fixation technique has been widely used for atlanto axial instability.

Many anatomical studies confirmed that C1 lateral masses can accommodate 3.5mm screws bilaterally in almost all patients and in the majority of cases can accommodate 4mm screws.<sup>1,5,19,22</sup> The most important aspect of C1 lateral mass screws is the location of optimum entry site. In this study, the insertion point of C1 screw was the center of the posterior surface of the inferior articular process midway between the articular surface and the

intersection of the posterior arch of the C1 and the inferior articular process of the C1 lateral mass, near to the entry point described by Goel and Laheri<sup>8</sup> at the center of the posterior surface of the inferior articular process 1 to 2 mm above the articular surface. Harms and Melcher<sup>10</sup> defined the insertion point at the midpoint of the posterior surface of the inferior articular process at the junction of the posterior arch and the lateral mass. Simsek et al,<sup>20</sup> described the insertion point at the intersection of the posterior arch of the C1 and the inferior articular process of the C1 lateral mass.

The C2 ganglion and nerve with the surrounding venous plexus cover completely the entry site of the C1 lateral mass screws.<sup>8</sup> Therefore, many authors suggested neurectomy of C2 root with minimal morbidity. In contrast according to Harms and Melcher<sup>10</sup> the nerve should be kept intact and retracted caudally while the screws are inserted. In this study, C2 neurectomy was adopted in all cases to gain wide exposure of the lateral mass entry point and the C1-2 joint, thus, facilitating the placement of the C1 lateral mass screws, C1-2 joint drilling and impaction of graft. Only 2 patients experienced mild postoperative occipital hypoesthesia (20%). On the other hand, manipulation of the C2 nerve root and direct irritation of the nerve root by the unthreaded portion of the C-1 lateral mass screw protruding from the lateral mass may lead to C2 neuralgia rather than C2 neurectomy.<sup>9</sup>

There are minor variations regarding the optimal C1 lateral mass screw trajectory. Goel and Laheri<sup>8</sup> suggested 15° of medial angulation with the 15° of cephalic angulation. Harms and Melcher<sup>10</sup> defined the screw trajectory as the anterior arch of C1

under fluoroscopy control. In the study by Rocha et al,<sup>19</sup> the maximum angle of medialization from the midline was calculated as  $16.7^{\circ} \pm 1.3^{\circ}$  (range;  $14.6^{\circ}$ - $20.7^{\circ}$ ). Consistent with Goel and Laheri<sup>8</sup>, Harms and Melcher<sup>10</sup> who preferred bicortical purchase of the C1 lateral mass screws; all our 20 C1 lateral mass screws were placed bicortically with  $\leq 2$ mm over penetration to avoid posterior pharyngeal wall injury.

The majority of our patients (80%) had chronic presentation with the average duration of symptoms more than one year. This is primarily due to refusal of the possible complications of surgery rather than delay of diagnosis. This may be due to the poor results and complications of other traditional methods of atlantoaxial fixation rather than the most recent techniques.

Regarding the average operative time and intraoperative blood loss, the reports varies considerably, from 83 minutes to 169 minutes.<sup>14,21</sup> The mean operative time in the present study (149 minutes) is comparable to these reports. The mean blood loss in reported studies ranged from 123 ml to 730 ml while the mean blood loss in the present study (250 ml) also compares favorably with these studies.<sup>15,21</sup>

Solid bony fusion was achieved in all patients (10/10) in this study, which is consistent with the reported 100% fusion rate of Goel and Laheri<sup>8</sup>, Harms and Melcher<sup>10</sup> and Simsek et al,<sup>20</sup> In contrast, the reported fusion rate of the old wiring techniques was significantly lower (70%-80%) and required long postoperative immobilization.<sup>7,18</sup>

In summary, C1 lateral mass screw fixation is a safe and efficient method of rigid segmental atlantoaxial fixation independent on the axis like transarticular screws or posterior components like wiring techniques. It is a valuable option in the armamentarium of spine surgeon.

## Conclusion

C1 lateral mass screw fixation is a safe and effective method of segmental fixation in cases of atlantoaxial instability. It provides immediate rigid stabilization of the atlantoaxial joint and obviates the need for halo vest immobilization. However, Placement of C-1 lateral mass screws is a technically demanding procedure necessitates thorough understanding of the regional anatomy.

## References

- 1) Abou-Madawi A, Solanki G, Casey AT, Crockard HA: Variation of the groove in the axis vertebra for the vertebral artery: implications for instrumentation. *J Bone Joint Surg Br* 79:820-3, 1997
- 2) Aryan HE, Newman CB, Nottmeier EW, Acosta Jr FL, Wang VY, Ames CP: Stabilization of the atlantoaxial complex via C-1 lateral mass and C-2 pedicle screw fixation in a multicenter clinical experience in 102 patients: modification of the Harms and Goel techniques. *J Neurosurg Spine* 8:222-9, 2008
- 3) Brooks AL, Jenkins EB: Atlantoaxial arthrodesis by the wedge compression method. *J Bone Joint Surg Am* 60:279-284, 1978
- 4) Dickman CA, Sonnag VK: Posterior C1-2 transarticular screw fixation for atlantoaxial arthrodesis. *J Neurosurg* 43:275-280, 1998
- 5) Dong Y, Xia Hong M, Jianyi L, Yuan Lin M: Quantitative anatomy of the lateral mass of the atlas. *Spine* 28:860-3, 2003
- 6) Fiore AJ, Haid RW, Rodts GE, Subach BR, Mummaneni PV, Riedel CJ et al: Atlantal lateral mass screws for posterior spinal reconstruction: technical note and case series. *Neurosurg Focus* 15;12:E5, 2002
- 7) Gallie W: Fractures and dislocations of the cervical spine. *Am J Surg* 46:495-499, 1939
- 8) Goel A, Laheri V: Plate and screw fixation for atlantoaxial subluxation. *Acta Neurochir (Wien)* 129:47-53, 1994
- 9) Hamilton DK, Smith JS, Sansur CA, Dumont AS, Shaffrey CI: C-2 neurectomy during atlantoaxial instrumented fusion in the elderly: patient satisfaction and surgical outcome. *J Neurosurg Spine* 15: 3-8, 2011
- 10) Harms J, Melcher RP: Posterior C1-C2 fusion with polyaxial screw and rod fixation. *Spine* 26:2467-2471, 2001
- 11) Henriques T, Cunningham BW, Olerud C, Shimamoto N, Lee GA, Larsson S et al: Biomechanical comparison of five different atlantoaxial posterior fixation techniques. *Spine* 25:2877-2883, 2000
- 12) Hirabayashi K, Miyakawa J, Satomi K, Maruyama T, Wakano K: Operative results and postoperative progression of ossification among patients with

- ossification of cervical posterior longitudinal ligament. *Spine* 6:354-364, 1981
- 13) Japanese Orthopaedic Association: Scoring system (17–2) for cervical myelopathy. *J Jpn Orthop Assoc* 68:490–503, 1994
  - 14) Lee SH, Kim ES, Sung JK, Park YM, Eoh W: Clinical and radiological comparison of treatment of atlantoaxial instability by posterior C1-C2 transarticular screw fixation or C1 lateral mass-C2 pedicle screw fixation. *J Clin Neurosci* 17:886–892, 2010
  - 15) Liu G, Buchowski JM, Shen H, Yeom JS, Riew KD: The feasibility of microscope-assisted “free-hand” C1 lateral mass screw insertion without fluoroscopy. *Spine* 33:1042–1049, 2008
  - 16) Magerl F, Seemann PS: Stable posterior fusion of the atlas and axis by transarticular screw fixation, in Kehr P, Weidner A (eds): *Cervical Spine*. New York, Springer PP 322–327, 1986
  - 17) Paramore CG, Dickman CA, Sonntag VK: The anatomic suitability of the C1–2 complex for transarticular screw fixation. *J Neurosurg* 85:221–224, 1996
  - 18) Reilly TM, Sasso RC, Hall PV: Atlantoaxial stabilization: clinical comparison of posterior cervical wiring technique with transarticular screw fixation. *J Spinal Disord* 16:248-253, 2003
  - 19) Rocha R, Safavi-Abbasi S, Reis C, Theodore N, Bambakidis N, de Oliveira E, et al: Working area, safety zones, and angles of approach for posterior C-1 lateral mass screw placement: a quantitative anatomical and morphometric evaluation. *J Neurosurg Spine* 6:247-54, 2007
  - 20) Simsek S, Yigitkanli K, Seckin H, Akyol C, Belen D, Bavbek M: Freehand C1 lateral mass screw fixation technique: our experience. *Surg Neurol* 72:676-681, 2009
  - 21) Stulik J, Vyskocil T, Sebesta P, Kryl J: Atlantoaxial fixation using the polyaxial screw-rod system. *Eur Spine J* 16:479–484, 2007
  - 22) Wang MY, Samudrala S: Cadaveric morphometric analysis for atlantal lateral mass screw placement. *Neurosurgery* 54:1436-40, 2004

Address reprint  
request to:

**Mohamed Ali El-Gaidi, MD**

Department of Neurosurgery 26, Faculty of Medicine, Kasr Al-Ainy Medical School, Cairo University, Cairo 11562, Egypt.  
E-Mail: mohamedelgaidi @ gmail.com



تثبيت الكتلتين الجانبيتين للفهقة بواسطة البراغي في التقلقل الفهقي المحوري. دراسة سريرية الخلفية العلمية: ما زال تثبيت فقرتي الفهقه و المحور (الفقرتين الاولى و الثانية العنقيه) يمثل تحديا عكس بقية العمود الفقري و ذلك لأن هذه المنطقة معقدة تشريحيًا و لذلك تم استعمال الاسلاك تحت صفيحتي الفقرتين برغم مضاعفاتها. و علي عكس البرغي المفصلي بين الفهقة و المحور. فان برغي الكتلة الجانبية للفهقة لا يعتمد علي برغي المحور

تصميم الدراسة: دراسته استشرافيه سريرية و صفيه

الغرض: تقييم سلامة و كفاءة تثبيت الكتلتين الجانبيتين للفهقة بواسطة البراغي في التقلقل الفهقي المحوري المرضي والطرق: شملت الدراسة ١٠ مرضي يعانون من تقلقل فقرتي الفهقه و المحور في مستشفى المنيل الجامعي بالقصر العيني خلال الفترة بين عامي ٢٠٠٨ و ٢٠١٣. تم تقييم النتائج سريريا طبقا لمعايير الجمعيه اليابانيه للعظام و ايضا تم تقييم مضاعفات التدخل الجراحي

النتائج: كان متوسط عمر المرضي حوالي ٣٠ عاما. و هم ٦ اناث و ٤ ذكور. كانت الحوادث هي السبب الأكثر شيوعا للتقلقل الفهقي المحوري. و كان الضعف الرباعي هو العرض الأكثر شيوعا ثم الام العنق.

و قد تحسن متوسط درجة الجمعيه اليابانيه للعظام من ١٣.١ نقطة قبل الجراحة الي ١٥.٢ نقطة بعد الجراحة (في نهاية فترة المتابعة و متوسطها ١٣.٥ شهر. و كان متوسط معامل التحسن ٤٨.٣٪. و قد تم تركيب ٢٠ برغي في الكتل الجانبيه للفهقه بنجاح. و كان متوسط طول البرغي ٢٧.٨ ملم. و تحسنت ايضا المعايير الاشعاعيه بعد الجراحة حيث تحسن متوسط المسافة بين الفهقة و سن المحور من ٥.٤ مم الي ٥.٨ مم و تحسن متوسط الزاوية بين التقاء النخاع و الحبل الشوكي العنقي من ١٢٦.٢° الي ١٤١.١°. و لا توجد وفيات او اصابه للشريان الفقاري ولكن حدثت مضاعفات بسيطه و منها نزيف وريدي شديد لاحد المرضي و تم نقل وحده دم له. و احد المرضي عاني من التهاب سطحي للجرح و تم علاجه تحفظيا بنجاح.

الاستنتاج: ان تثبيت الفهقه بواسطه براغي في الكتلتين الجانبيتين وسيله امنه و فعاله و قليلة المضاعفات لمرضي التقلقل الفهقي المحوري.