

A new stand-alone cage for cervical fusion Technique and early results

Yasser Allam, MD.

Orthopaedic Department, Spine Unit, Al-Hadra University Hospital, Alexandria, Egypt.

Abstract

Background Data: After discectomy and anterior decompression, an intervertebral spacer is always necessary to promote fusion and to reconstruct cervical lordosis. The use of stand-alone cages is going to avoid the problems of graft donor site morbidity as well as the complications of the anterior instrumentation

Purpose: The aim of this study is to present an intervertebral spacer that will provide the cervical spine with mechanical stability without the need for anterior instrumentation as well as a high fusion rate without the use of iliac bone graft.

Study Design: Technical report

Patients and Methods: The material of this study consisted of 50 patients with cervical radiculopathy. The mean age was 58.3 years. 55% of the patients were females. Patients were assessed pre-operatively and post-operatively using the Neck Disability Index (NDI) and the Visual Analogue Scale (VAS) for neck and arm pain. Fusion at the end of follow up was detected using X-Ray and multislice CT scans.

Results: The mean operative time per level was 60 minutes. The average blood loss was 100 ml. There were no intraoperative complications. Preoperatively, the VAS neck was 6.8, VAS arm was 7.3 and NDI was 69. At the end of follow up the VAS neck improved to 3.7, VAS arm to 3.1 and NDI to 26. Fusion occurred in 98% and cage subsidence was observed in 8% of patients.

Conclusion: In comparison to other intervertebral cervical spacers, we think that we are going to achieve good clinical results with improved fusion rate. (2014ESJ060)

Keywords: ACDF, Stand-alone, Titanium cages, Fusion, Subsidence

Introduction

The anterior approach for the treatment of the cervical spinal degenerative disorders was actually standardized after Cloward,¹⁰ Bailey and Badgley¹, and Smith and Robinson.²⁸ After discectomy and anterior decompression, an intervertebral spacer is always necessary to promote fusion and to reconstruct cervical lordosis. These intervertebral spacers are either: autogenous tri-cortical iliac bone graft, or one of the different cage designs.

A tricortical bone graft will be taken from the anterior part of the iliac crest to act as intervertebral spacer followed by fixation of the cervical spine by anterior plate and screws. The problems met with in this technique include: (a) Bone graft donor site morbidity: In reviewing the literature, we will find a rate of graft donor site morbidity of 5.6%.²⁵ Additionally, taking a bone graft will lengthen the duration of the operation. (b) Complications of the anterior instrumentation: The main complications met with include; screw loosening, screw breakage and pseudoarthrosis. In his work, reported a revision rate of 7.2% after using Caspar plate.⁵ On the other hand, the study of Lowery et al,¹⁹ showed 35% hardware failure of the anterior instrumentation.

The use of stand-alone cages is going to avoid the problems of graft donor site morbidity as well as the complications of the anterior instrumentation. In fact, a wide variety of spacers are now available for use. The oldest spacer known was PMMA. However, with the sue of PMMA, Hamburger¹⁶ reported a pseudoarthrosis rate of 46.2%. Pseudoarthrosis is one of the most important problems of stand-alone cages. The work of Geisler¹³ showed pseudoarthrosis rate of 4-26% in single level fusion, 17-63% in two level fusions and 50% three level fusions.

The aim of this study is to present an intervertebral spacer that will provide the cervical spine with mechanical stability without the need for anterior instrumentation as well as a high fusion rate without the use of iliac bone graft.

Patients and Methods

Patient Selection:

The material of this study consisted of 50 patients with cervical radiculopathy. The mean age was 58.3 years. 55% of the patients were females. The follow up period ranged from 12-24 months with a

mean of 18 months. All patients complained only of pain (mainly arm and to less extent neck pain) and paresthesia at the distribution of the compressed nerve root. 3 patients suffered from weakness of the Deltoid muscle (M0 – M3) and two patients suffered from triceps muscle weakness (M4).²⁶The diagnosis of cervical disc disease was made sure by X-rays and MRI of cervical spine. 34 patients showed single level while 16 patients showed double level cervical disc disease. The levels affected were C5/6 (30 levels), C6/7 (23 levels), C4/5 (12 levels) and C3/4 (one level). The indication for surgery was failure of conservative treatment of pain over a period of 6 weeks and/or neurological deficits.

Clinical Assessment:

The patients were assessed pre-operatively and post-operatively using the Neck Disability Index (NDI)³¹ and the Visual Analogue Scale (VAS) for neck and arm pain.⁴

Assessment of Fusion:

Bone fusion was assessed at the end of follow up using X-ray and CT scan following the criteria of Peolsson et al,²³ The operated level will be considered fused when there is bridging bone anterior or though the cage and pseudoarthrosis will be considered when there is no bridging bone at all.

Assessment of Cage Subsidence:

Subsidence and kyphosis were assessed on lateral cervical radiographs made directly postoperative and at the end of follow up. Subsidence of the Cage was defined as a decrease in total vertical height of the two fused vertebral bodies as measured on the lateral cervical radiographs made at the end of follow up and compared with the directly postoperative radiographs. Subsidence greater than 3 mm was considered relevant.¹⁴ Because of intra-individual variations of the magnification factor in the radiographs, the total vertical height of the two fused vertebral bodies was corrected for magnification differences by using the anteroposterior diameter of the upper vertebral body on the lateral cervical radiograph.²⁷ Segmental kyphosis or lordosis was measured by the angle between the upper and lower adjacent end plate line.¹⁴

Technical Description and Surgical Technique:

This cage is designed after the principle of 'Meterware' from U-shaped Titanium with wall thickness of 1.5 mm and width of the cage ranged from 15-20 mm. The perforations in the cage will allow bone growth through the cage (Figure 1).

The principle of 'Meterware' will allow cutting the cage with the most suitable height. After microscopic anterior decompression of the spinal canal and through the anterior opening, the cage will be inserted in the disc space. The posterior perforations of the cage will allow insertion of the cage under vision and in this way; we can avoid too far posterior insertion of the cage that may endanger the spinal cord. After correct positioning of the cage (as seen by image intensifier) and through the anterior opening of the cage, decortication of the part of superior and inferior endplate that gain contact with the bone graft will be available. This is achieved by high speed burr or by using sharp bone curette. This means that at the points of cage contact with the vertebrae, the endplates are still intact and this will decrease the possibility of cage sinking and hence loss of cervical lordosis. After that, the cage will be filled with the bone removed from the anterior and posterior osteophytes. Philadelphia collar is applied post-operatively for 8 weeks. Patients were followed up regularly every 3 months.

Results

Demographic Data:

The work inability before surgery was about 3.6 weeks and the patients returned back to work after a mean of 6.8 weeks after surgery. The hospital stay was 4.6 days.

Operative Data:

The mean operative time per level was 60 minutes. The average blood loss was 100 ml. There were no intraoperative complications.

Pain Assessment:

Preoperatively, the VAS neck was 6.8, VAS arm was 7.3 and NDI was 69. At the end of follow up the VAS neck improved to 3.7, VAS arm to 3.1 and NDI to 26. The 3 parameters show highly significant difference ($P < 0.001$) between the preoperative values and the values at end of follow up.

Neurological State:

The two patients with pre-operative triceps muscle weakness (M4), showed postoperative complete recovery. Of the three patients with deltoid muscle weakness (M0-M3), one showed complete recovery and the other two showed incomplete recovery. On the other hand, 32 patients presented with

preoperative sensory deficits recovered completely while 18 patients showed improvement of the pre-operative sensory deficit.

Fusion:

Ninety eight percent of patients showed fusion of the operated cervical segments as seen by X-rays (Figure 2) and CT scans (Figure 3). One patient (2%) complained of neck pain 18 months after ACDF C5-C7. X-ray, CT and MRI showed pseudoarthrosis of C5-C6. Pseudoarthrosis was treated by revision with removal of the fibrous tissue and bone graft remnants from inside the cage, freshening of the upper and lower endplate using high speed burr then grafting using iliac cancellous bone graft. Follow up of this patient showed complete fusion after 6 months from surgery. It must be mentioned that revision for pseudoarthrosis using this cage is easier compared with other cages. As this cage is opened anteriorly, it will be easy to remove the fibrous tissue from the cage, clean the endplates and apply new bone graft without the need to remove the cage completely as it is the case in other cages.

Cage Subsidence:

Subsidence > 3 mm was observed in 4 patients (8%). Inferior cage migration into the inferior end plate was observed in two patients. Both superior and inferior end plate migration was observed in the other two cases (Figure 4,5).

The mean preoperative segmental angle was 3.2° postoperatively, the angle improved to 5.3° and this was statistically significant ($P < 0.05$). At the end of follow up period, the mean angle was 4.5° .

Postoperative Complications:

In the early postoperative period, one patient (2%) suffered from recurrent laryngeal nerve paralysis, managed by speech therapy and showed complete recovery after 12 weeks postoperative. Another patient (2%) presented with post-operative wound hematoma on the night of surgery that was managed by wound revision and hematoma evacuation without any other consequences.

Late post-operative complications included one patient with adjacent segment disease. This was in the form of disc prolapse C5-C6 after two years of ACDF C6-C7. This level was also treated with stand-alone cage using the same cage.




Figure 1.
The Cage

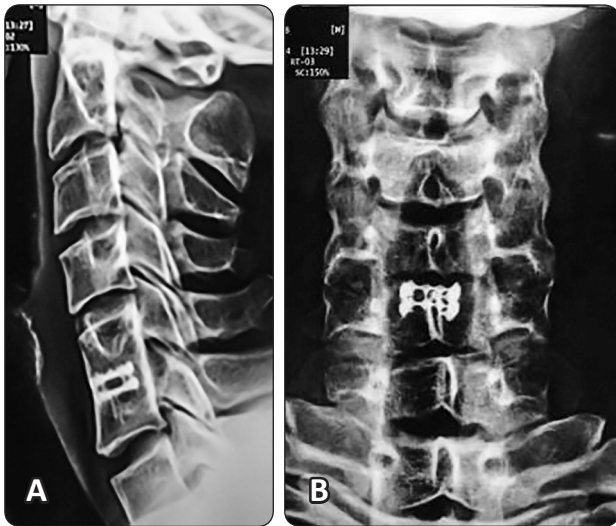

Figure 2. (A) lateral and (B) AP view of the cervical spine showing complete fusion of the operated cervical segment (C5-C6)

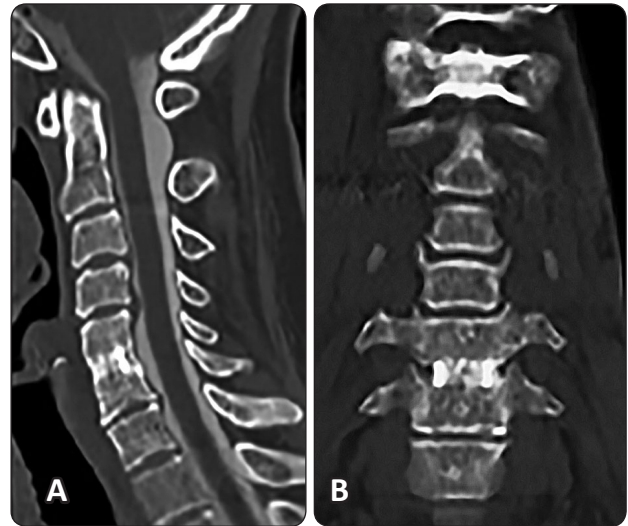


Figure 3. (A) Sagittal and (B) Coronal multislice CT reconstruction of the cervical spine showing complete fusion of the operated cervical segment (C5-C6)

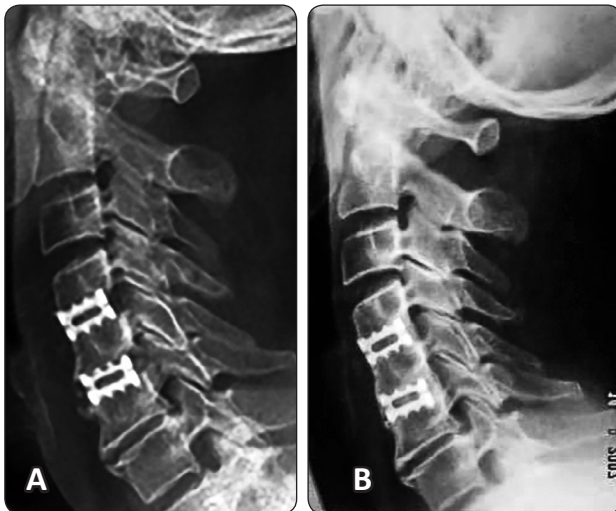

Figure 4. (A) Postoperative and (B) End follow up (15 months) lateral X-ray of the cervical spine after ACDF C4-C6 showing no cage subsidence.

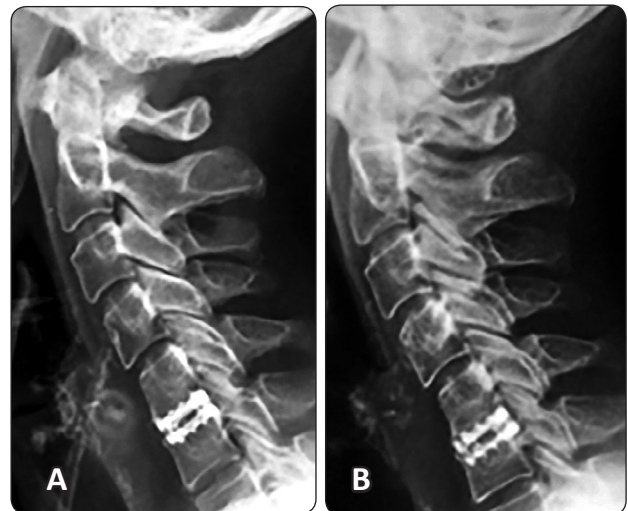


Figure 5. (A) Postoperative and (B) End follow up (12 months) lateral X-ray of the cervical spine after ACDF C5-C6 showing inferior cage subsidence.

Discussion

A variety of cages are currently available, including carbon fiber cages,^{3,6} threaded fusion cages,^{8,9} and titanium meshes.^{11,20} They offer advantages including immediate restoration and maintenance of intervertebral disc height, enlargement of a stenotic neural foramen, and stabilization of the degenerative disc. Recently, histologic evidence of bone graft incorporation within cages has been reported in successful human intervertebral body fusions.²⁹

Regarding bone graft materials, tricortical iliac crest autograft has been the gold standard in the cervical anterior fusion. However, harvesting autogenous bone from the iliac crest can be associated with increased blood loss, limited supplies of donor bone, and postoperative pain at the graft site.¹⁸ Sawin et al,²⁴ reported a 25.3% morbidity rate that included pain, hematoma, fracture, and neuralgia paresthetica. As well, significant discomfort and residual pain may continue for as long as 12–24 months after surgery.²

In the present study, the patient group showed good fusion rates (98%) and good clinical outcomes. This fusion rate is higher than that reported by Fraser et al,¹² in a meta-analysis of fusion rate. He reported for a single disc-level disease, the fusion rates achieved were 92.1% using ACDF, and 97.1% using ACDF with anterior plating. In Marotta study,²¹ 87% fusion rate was found after ACDF using carbon cages without plating and this is far below the fusion rate in current study. However, Chen et al,⁷ reported a fusion rate of 100% for both titanium and PEEK cages. We think that this high rate of fusion is due to good decortication of the part of superior and inferior endplate that are in contact with the bone graft followed by good packing of the graft through the anterior opening of the cage after its insertion. Despite good decortication, at the points of cage contact with the vertebrae, the endplates are still intact leading to less possibility of cage sinking. In other cage designs (circular or rectangular with no anterior opening) the decortication will be carried out before cage insertion. This necessitates decortication of a larger surface area of the endplates. If endplates are under decorticated to avoid cage sinking, the fusion rate will be less and if the endplates are over decorticated, the fusion rate

will be high but cage sinking will be inevitable.

In our study, cage subsidence was observed in 4 patients (8%) with single level ACDF. All 4 patients showed fusion of the operated levels at the end of follow up. The clinical relevance of subsidence is not clear, but subsidence may result in kyphotic deformity, pseudoarthrosis, and recurrence of symptoms, possibly with a need for reoperation.¹⁴ Moreland et al recently reported the short-term results of the Rabea titanium cage for ACDF.²² Fusion was achieved in 95% at 6 months, and subsidence greater than 2 mm occurred at the inferior anterior edge of the cage in 22% of patients. The observation of subsidence did not compromise fusion rate or clinical outcome. Gercek et al,¹⁴ noted subsidence in five of nine fused levels using the Syn-Cage C after 15 months follow-up.

Subsidence behavior of interbody fusion cages may be influenced by various factors such as cage design,¹⁷ cage size,¹⁵ the contact area at the implant–bone interface,³² end plate geometry,³⁰ and the bone quality of vertebral end plates.³⁰ Finally, postoperative neck flexion movements probably influence cage subsidence behavior.³²

We think that the design of this cage with anterior opening may decrease the incidence of subsidence as at cage bone contact area, the endplate will be left intact and decortication will only take place at graft bone contact area.

The obvious advantages of the cage are shorter duration of surgery, immediate relative stability (in compression) resisting axial displacement, ability to act as an incompressible spacer maintaining spinal alignment and foraminal height with minimal subsidence, easy to revise in case of pseudoarthrosis and most importantly the absence of harvest site morbidity. The benefit derived from using cages instead of traditional techniques may be more a matter of avoiding the indirect morbidity rather than obtaining superior results

Conclusion

In comparison to other intervertebral cervical spacers, we think that we are going to achieve good clinical results with improved fusion rate. The technique of stand-alone cage will avoid the iliac bone graft donor site morbidity as well as the complications of anterior instrumentations.

Conflict of interest

No funds were received in supported of this work. No benefits in any form have been or will be received from a commercial party related directly or indirectly to the subject of this manuscript.

References

1. Baily RW, Badgley CE: Stabilization of cervical spine by anterior fusion. *J Bone Joint Surg [Am]* 42:565-569, 1960
2. Banwart JC: Iliac crest bone graft harvest donor site morbidity. *Spine* 20:1055-1060, 1995
3. Bartels RH, Donk R, van Azn RDJ: Height of cervical foramina after anterior discectomy and implantation of a carbon fiber cage. *J Neurosurg.* 95:40-42, 2001
4. Beecher HK: Measurement of subjective responses. Quantitative effects of drugs. Oxford University Press, New York, 1959. XVI + 499 pp.
5. Bose B: Anterior cervical fusion using caspar plating. Analysis of results and review of the literature. *SurgNeurol* 1998;49:25-31, 1998
6. Brooke NS, Rorke AW, King AT, Gullan RW: Preliminary experience of carbon fiber cage prostheses for treatment of cervical spine disorders. *Br J Neurosurg* 11:221-227, 1997
7. Chen Y, Wang X, Lu X, Yang L, Yang H, Yuan W, Chen D: Comparison of titanium and polyetheretherketone (PEEK) cages in the surgical treatment of multilevel cervical spondylotic myelopathy: a prospective, randomized, control study with over 7-year follow-up. *Eur Spine J* 22:1539-1546, 2013
8. Cho DY, Lee WY, Sheu PC: Treatment of multilevel cervical fusion with cages. *SurgNeurol* 62(5):378-385, 2004
9. Cho DY, Liau WR, Lee WY, Liu JT, Chiu CL, Sheu PC: Preliminary experience using a polyetheretherketone (PEEK) cage in the treatment of cervical disc disease. *Neurosurgery* 51(6):1343-1349, 2002
10. Cloward RW: The anterior approach for removal of ruptured cervical discs. *J Neurosurg* 15:602-617, 1958
11. Das K, Couldwell WT, Sava G, Taddonio RF: Use of cylindrical titanium mesh and locking plates in anterior cervical fusion. *J Neurosurg* 94:174-178, 2001
12. Fraser JF, Haertl R: Anterior approaches to fusion of the cervical spine: a metaanalysis of fusion rates. *Neurosurg Spine* 6:298-303, 2007
13. Geisler FH, Caspar W, Pitzen T, Johnson TA: Reoperation in patients after anterior cervical plate stabilization in degenerative disease. *Spine* 23:911-920, 1998
14. Gercek E, Arlet V, Delisle J, Marchesi D: Subsidence of stand-alone cervical cages in anterior interbody fusion: warning. *Eur Spine J* 12:513-516, 2003
15. Goh JC, Wong HK, Thambyah A, Yu CS: Influence of PLIF cage size on lumbar spine stability. *Spine* 25:35-39, 2000
16. Hamburger C, Festenberg FV, Uhl E: Ventral discectomy with PMMA interbody fusion for cervical disc disease. *Spine* 26:249-255, 2001
17. Kandziora F, Pflugmacher R, Schafer J, Born C, Duda G, Haas NP, et al: Biomechanical comparison of cervical spine interbody fusion cages. *Spine* 26:1850-1857, 2001
18. Kurz LT, Garfin SR, Booth RE Jr: Harvesting autogenous iliac bone grafts. A review of complications and technique. *Spine* 14:1324-1331, 1989
19. Lowery GL, McDonough RF: The significance of hardware failure in anterior cervical plate fixation. *Spine* 23:181-187, 1998
20. Majd ME, Vadhva M, Holt RT. Anterior cervical reconstruction using titanium cage with anterior plating. *Spine* 24:1604-1610, 1999
21. Marotta N, Landi A, Tarantino R, Mancarella C, Ruggeri A, Delfini R: Five-year outcome of stand-alone fusion using carbon cages in cervical disc arthrosis. *Eur Spine J* 20 (Suppl 1):S8-S12, 2011
22. Moreland DB, Asch HL, Clabeaux DE, Castiglia GJ, Czajka GA, Lewis PJ, et al: Anterior cervical discectomy and fusion with implantable titanium cage: initial impressions, patient outcomes and comparison to fusion with allograft. *Spine J* 4:184-191, 2004
23. Peolsson A, Hedlund R, Vavruch L: Prediction of fusion and importance of radiological variables for the outcome of anterior cervical decompression and fusion. *Eur Spine J* 13:229-234, 2004
24. Sawin PD, Traynelis VC, Menezes AH: A comparative analysis of fusion rate and donor-site morbidity for autogenous rib and iliac crest bone grafts in posterior cervical fusions. *J Neurosug.* 88:255-265, 1998

25. Schnee CL, Freese A, Weil RJ, Marcotte PJ: Analysis of harvest morbidity and radiographic outcome using autograft for anterior cervical fusion. Spine 22:2222-2227, 1997
26. Seddon HJ: Peripheral nerve injuries. Medical Research council special report series No 282. Her Majesty's Stationary Office, London 1954
27. Siddiqui AA, Jackowski A: Cage versus tricortical graft for cervical interbody fusion: a prospective randomised study. J Bone Joint Surg Br 85:1019-1025, 2003
28. Smith GW, Robinson RA: The treatment of certain cervical spine disorders by anterior removal of the intervertebral disc and interbody fusion. J Bone Joint Surg [Am] 40:607-624, 1958
29. Togawa D, Bauer TW, Brantigan JW, Lowery GL: Bone graft incorporation in radiographically successful human intervertebral body fusion cages. Spine 26:2744-2750, 2001
30. Truumees E, Demetropoulos CK, Yang KH, Herkowitz HN: Failure of human cervical endplates: a cadaveric experimental model. Spine 28:2204-2208, 2003
31. Vernon H, Mior S: The Neck Disability Index: a study of reliability and validity. J Manipulative PhysiolTher 14: 409-415, 1991
32. Wilke HJ, Kettler A, Goetz C, Claes L: Subsidence resulting from simulated postoperative neck movements: an in vitro investigation with a new cervical fusion cage. Spine 25:2762-2770, 2000

Address reprint
request to:

Yasser Allam, MD

Spine unit, Al-Hadra University Hospital, Alexandria, Egypt
Email: yasser_allam@hotmail.com

الملخص العربي

قفص جديد مستقل للحام الفقرات العنقية. الطريقة الجراحية و النتائج الأولية

الخلفية العلمية: بعد استئصال الغضروف العنقي وإزالة الضغط الأمامي يعتبر وضع القفص بين الفقرات العنقية دائما ضروري لتعزيز الاندماج وإعادة بناء انحاء الفقرات العنقية. استخدام الأقفاص المستقلة يؤدي إلى تجنب مشاكل الترقيع العظمى من الحوض فضلا عن مضاعفات أجهزة التثبيت الأمامي تصميم الدراسة: تقرير فني

الغرض: الهدف من هذه الدراسة هو تقديم قفص جديد بين الفقرات العنقية التي من شأنها أن توفر للعمود الفقري العنقي الاستقرار الميكانيكي دون الحاجة للتثبيت الأمامي، فضلا عن معدل عالي للحام دون استخدام الترقيع العظمى من الحوض.

المرضى والطرق: تكونت هذه الدراسة من 50 مريضا يعانون من اعتلال الجذور العنقية. وكان متوسط العمر 58.3 عاما. 55% من المرضى كانوا من الإناث. تم تقييم المرضى قبل الجراحة وبعدها باستخدام مؤشر عجز الرقبة ومقياس الم الرقبة والام الذراع

النتائج: كان وقت العملية للمستوى الواحد 60 دقيقة. كان متوسط فقدان الدم 100 مل. لم تكن هناك مضاعفات أثناء العملية. قبل الجراحة، كان الم الرقبة 6.8، و كان الم الذراع 7.3. وفي نهاية المتابعة تحسن الم الرقبة إلى 3.7، والم الذراع إلى 3.1

الاستنتاج: بالمقارنة مع غيرها من الأقفاص بين الفقرات العنقية، نحن نعتقد أننا ذاهبون لتحقيق نتائج سريرية جيدة مع تحسن معدل للحام.