

Anterior Column Reconstruction for Treatment of Failed Short Segment Pedicular Fixation in Thoracic and Lumbar Spine Fractures

Khaled M Hassan, MD, Belal El Nady, MD.

Orthopaedic department (Spine Unit), Assiut University Hospitals, Assiut, Egypt.

Abstract

Background Data: Short segment pedicular fixation is one of the most common operative techniques to treat unstable thoracolumbar burst fracture. However, it may be associated with pseudoarthrosis, progressive kyphosis, and a high rate of hardware failure. Different surgical techniques were described to deal with this failure. Biomechanical investigations have shown that anterior fusion provides superior stability as compared to single dorsal instrumentations.

Study Design: A retrospective clinical case study.

Purpose: To evaluate the outcomes of anterior column reconstruction for treatment of failed short segment pedicular fixation system in thoracolumbar fractures.

Patients and Methods: This study included 25 patients with failed short segment pedicular fixation after acute thoracolumbar fracture. They were treated by anterior column reconstruction with strut iliac graft and fixed with either posterior long pedicular system or anterior locked system through simultaneous combined approaches. This study was done in the period between January 2009 to December 2013. Neurological status was classified using Frankel classification. All patients had been followed up by radiographs and CT-scans. Back pain and functional outcomes were assessed by VAS and ODI respectively.

Results: All patients were followed up for at least 24 months. The visual analogue scale (VAS) of back pain improved significantly from 6.20 ± 0.94 preoperatively to 1.87 ± 0.83 at the latest follow up. The mean Cobb angle improved significantly from $28.47 \pm 10.80^\circ$ preoperatively to $2.07 \pm 9.39^\circ$ immediate postoperatively and was maintained at $4.13 \pm 10.21^\circ$ at latest follow up. According to Brantigan criteria, fusion was considered certain in all 25 patients (100%) and no failure of internal fixation occurred at latest follow up. The functional outcomes which measured by

Received at:

April 17th, 2015

Accepted at:

June 19th, 2015

Oswestry disability index (ODI) improved significantly from 62.60±11.17% preoperatively to 24.00±6.04% at latest follow up.

Conclusion: Anterior column reconstruction of the spine achieved significant improvement in radiological, clinical, and functional outcomes with few complications for treatment of failed short segment pedicular fixation in thoracolumbar fractures. (2015ESJ091)

Keywords: anterior column reconstruction, failed pedicular fixation, thoracic and lumbar spine fracture.

Introduction

Unstable thoracolumbar fractures may have a major impact on the quality of life of many patients.³⁰ The optimal management strategy for thoracolumbar burst fractures remains controversial.^{8,17,24} Compared with other fixation systems, pedicular spinal purchase provides the most biomechanically rigid restraint to spinal motion in flexion, extension, and torsion.^{21,29} Currently, short segment pedicular fixation is one of the most common operative techniques to treat unstable thoracolumbar burst fracture as it is advantageous in preserving motion segments, which is particularly important in the mobile lumbar spine.^{9,34}

Despite these advantages and satisfactory clinical results of this procedure, pseudoarthrosis, progressive kyphosis, and a high rate of hardware failure remain a concern.^{20,23} Different surgical techniques were described to deal with this failure. Anterior column reconstruction is sometimes mandatory to avoid fixation failure. Biomechanical investigations have shown that anterior fusion provides superior stability as compared to single dorsal instrumentations.^{10,25}

The aim of this study is to evaluate the outcomes of anterior column reconstruction through simultaneous combined approaches for surgical treatment of failed short segment pedicular fixation system in thoracic and lumbar spine fractures.

Patients and Methods

This study included 25 patients with failed short segment pedicular fixation after acute fracture of the thoracic and lumbar spine. They constituted 14 males and 11 females. The mean age was 33.20±10.96 years. They presented with severe back pain to the outpatient clinic of our hospital during the period from January 2009 to December 2013. They were treated by anterior column reconstruction with strut iliac graft and fixed with either posterior long

pedicular system or anterior locked system through simultaneous combined approaches (posterior then anterior). After metal removal of the failed short segment pedicular system, posterior long segment pedicular fixation followed by anterior column reconstruction was done in 16 patients (64%) and anterior column reconstruction associated with anterior locked plate fixation was done in 9 patients (36%). The duration since first surgery ranged from 2 to 20 months (9.80±4.97). Inclusion criteria included all patients presented with failed short segment pedicular fixation used for fixation of traumatic thoracic and lumbar spine fractures. We excluded all patients with: Non traumatic fractures, Patients who have evidence of osteoporosis, Patients who experienced another significant trauma after fixation. Neurological status was classified using Frankel classification.¹⁴ All patients were neurologically free (Frankel E). The initial surgical treatment included simple laminectomy at the fracture level in 6 patients (24%). The etiology for revision surgery was failed short segment pedicular fixation including: screws loosening, screws breakage, and/or screw-rod disconnection associated with loss of correction and/or pseudoarthrosis. All patients had preoperative radiographs (antero-posterior and lateral views) and CT. The fracture levels were T10 in 3 patients, T12 in 9, L1 in 10, L2 in 2, and L4 in one. The local kyphotic angle (LKA) was measured using Cobb technique.³ Various surgical parameters including; blood loss, blood transfusion, surgical time, level of instrumentation and complications (intraoperative and postoperative) were recorded. Back pain of all patients was evaluated using Visual Analogue Scale (VAS).⁵ Fusion was assessed according to Brantigan criteria.⁴ The functional outcomes of all patients were evaluated according to Oswestry Disability Index (ODI).¹³

Surgical Strategy and Technique:

All 25 patients were placed in prone position on a spine table and through posterior approach,

metal removal was done. Posterior release including resection of part of the inferior and superior articular facets of the affected vertebra. With the help of C- arm image, lateral view was taken: -If the lateral sagittal curve of the spine at the fracture level was corrected partially, it means that the correction of the kyphosis through the posterior approach could be done depending on rod contouring. Long segment pedicular fixation (two or more above and below the fractured level) was applied. In the same sitting, the patient was prepared for anterior column reconstruction.-If the lateral sagittal curve of the spine at the fracture level was not corrected at all, it means that the correction of the kyphosis through the posterior approach could not be done except by using more invasive techniques of pedicle subtraction osteotomy or posterior corpectomy which might not be safe specially for patients in whom previous laminectomy at the fracture level was done. Then, the patient was prepared for anterior approach correction, reconstruction, and fixation in the same sitting.

In the anterior approach, all patients were approached through the left anterolateral side. Three approaches were done: thoracotomy (transplural) in T10, thoracolumbar (transpleural, transdiaphragmatic, retroperitoneal) in T12 and L1 and laparotomy (retroperitoneal) in L2 and L4. Anterior column reconstruction was done as follows: In patients who were fixed with long pedicular system posteriorly, three options were available: 1-If only the upper or lower end plate of the affected vertebra was crushed, excision of the affected disc was done and reconstruction with strut iliac autograft. 2- If both the upper and lower discs were involved with preserved 50% or more of the vertebral body size, discectomy of both discs and reconstruction with strut iliac autograft was done. 3- If more than 50% of the vertebral body was crushed, subtotal corpectomy of the affected vertebral body with discectomy of both adjacent discs, and reconstruction with strut iliac autograft were done.

In the patients who were not fixed posteriorly, subtotal corpectomy of the affected vertebral body and discectomy of both adjacent discs were done. This step was followed by distraction of the vertebra above and below to correct kyphosis and then, the gap was filled with strut iliac autograft. Finally, anterior locked plate was applied.

Statistical Analysis:

The follow up results were analyzed using Wilcoxon Signed Ranks test. The accepted level of statistical significance was $P < 0.05$.

Results

All patients were followed for at least 24 months and the mean follow up duration was 31.93 ± 4.83 months. The mean operative time was 166 ± 43.72 minutes. The blood loss was 580 ± 143 cc.

Clinical outcomes:

All patients presented with back pain with different grades of severity and they all reported significant improvement at the latest follow up. The mean of VAS score improved significantly from 6.20 ± 0.94 preoperatively to 1.87 ± 0.83 at the latest follow up ($P = 0.001$) (**Figure 1**). At latest follow up, all patients were neurologically free (Frankel E) as that of preoperative state.

Radiological Outcomes:

A total of 107 screws of short segment posterior fixation system which inserted in the initial surgery (4 screws in each of 18 patients and 5 screws in each of 7 patients), 38 screws (35.5%) were failed. Those screws failed in the form of loosening in 14 screws (36.8%), breakage in 16 (42.1%), and screw-rod disconnection in 8 (21.1%). In the revision surgery, 128 pedicle screws were inserted in 16 patients who fixed with posterior long segment pedicular system (8 screws in each patient) and 36 pedicle screws were inserted in 9 patients who fixed with anterior locked system (4 screws in each patient). At latest follow up, no metal failure was recorded in all patients.

The mean of Cobb angle improved significantly from $28.47 \pm 10.80^\circ$ preoperatively to $2.07 \pm 9.39^\circ$ immediate postoperatively ($P = 0.001$), and was maintained at $4.13 \pm 10.21^\circ$ at latest follow up ($P = 0.007$) (**Figure 2**). According to Brantigan criteria,¹⁶ fusion was considered certain in all 25 patients (100%) at 6 to 10 months follow up and no failure of internal fixation occurred at latest follow up.

Functional Outcomes:

The functional disability of the patients (ODI) improved significantly from $62.60 \pm 11.17\%$ preoperatively to $24 \pm 6.04\%$ at latest follow up ($P = 0.001$) (**Figure 3**).

Complications:

Transient weakness of left quadriceps muscle (grade 3) was observed in one patient with L1 fracture who treated with posterior long segment fixation and anterior corpectomy and graft. He improved

completely after 2 weeks. Hotness of the left lower limb was experienced in another patient with L2 fracture treated with anterior corpectomy and fixed with anterior locked plate. He improved completely after one year.

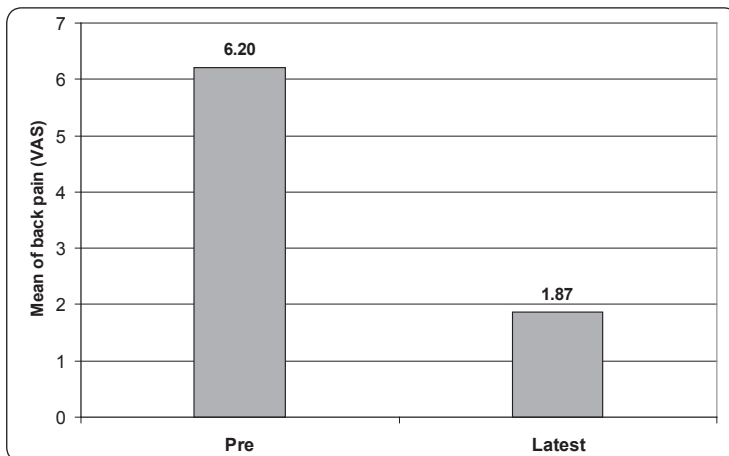


Figure 1.Visual Analogue Scale (VAS)

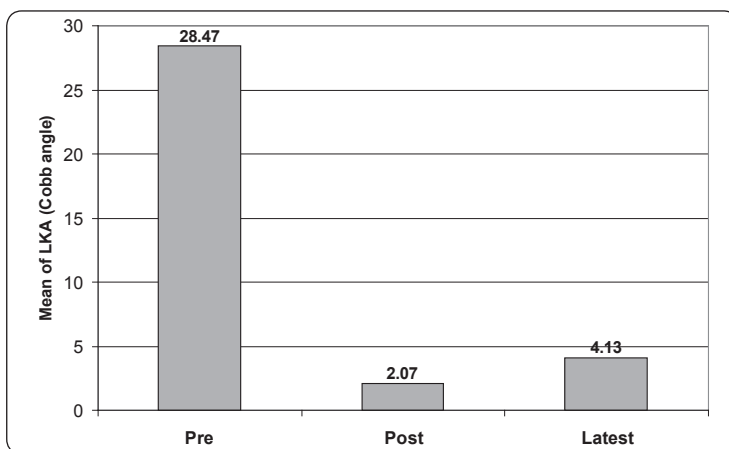


Figure 2.Local Kyphotic Angle (LKA)

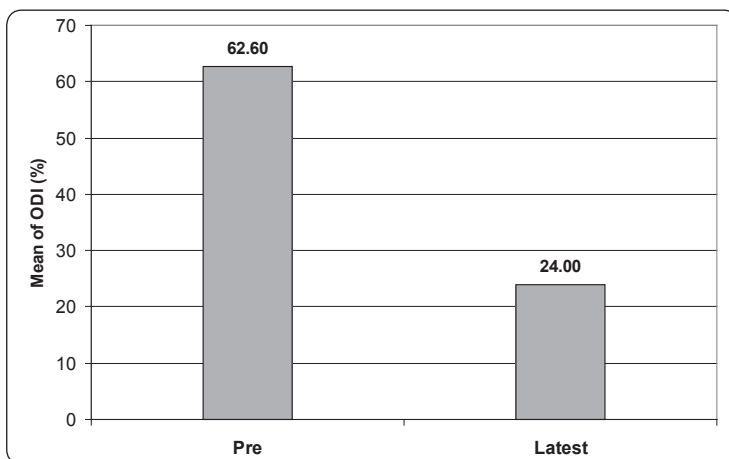


Figure 3.Oswestry disability Index (ODI)

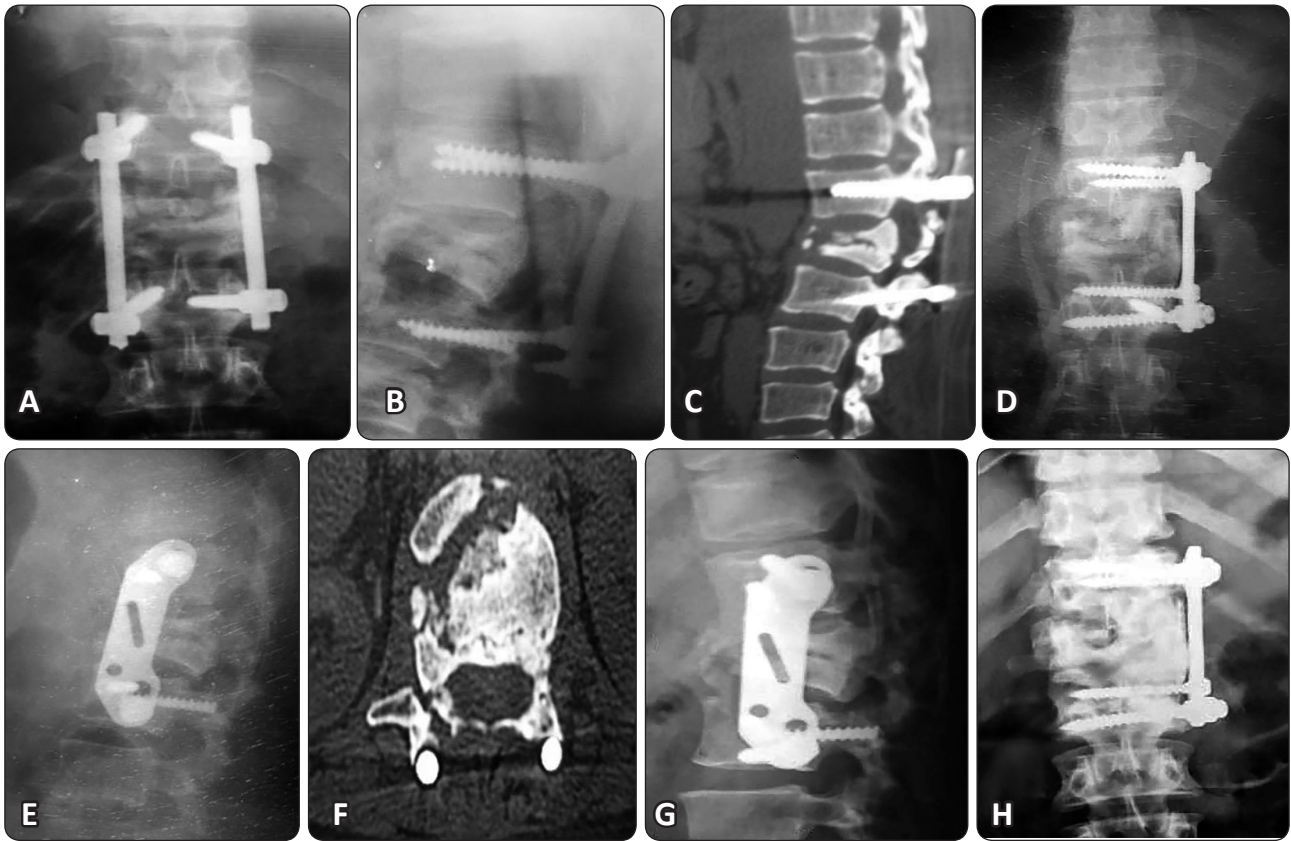


Figure 4. Female patient, 50 years old, Frankel E, with failed short segment pedicular fixation of L1 fracture, 15months since primary surgery. Preoperative plain X ray: anteroposterior (a) and lateral (b), Preoperative CT: sagittal (c) and axial (d) show pseudoarthrosis. Postoperative plain X ray: anteroposterior (e) and lateral (f) show anterior locked plate fixation with anterior corpectomy and strut iliac graft. Latest follow up plain X ray: anteroposterior (g) and lateral (h) show good fusion.

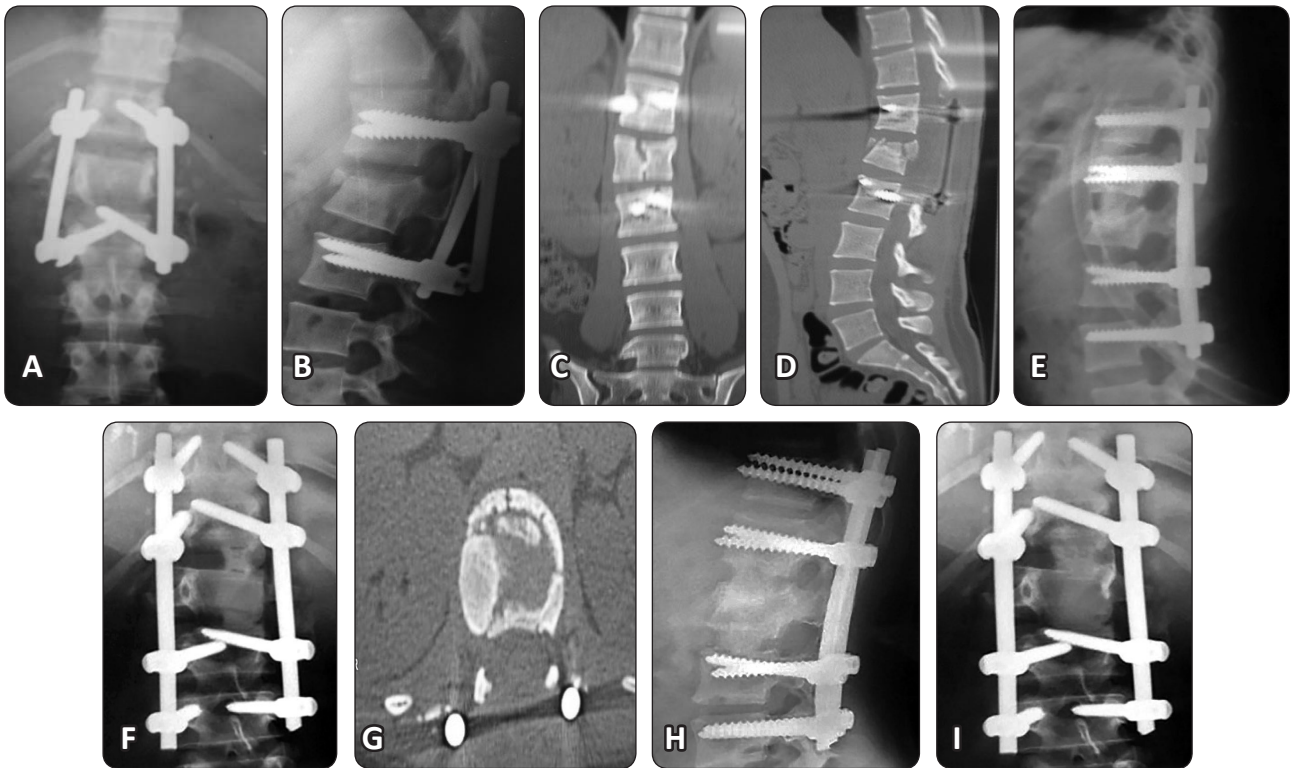


Figure 5. Female patient, 20 years old, Frankel E, with failed short segment pedicular fixation of L1 fracture, 5 months since primary surgery. Preoperative plain X ray: anteroposterior (a) and lateral(b), Preoperative CT: sagittal (c) and axial (d) show pseudoarthrosis. Postoperative plain X ray: anteroposterior (e) and lateral (f) show Posterior long segment pedicular fixation and anterior discectomy of T12 L1 and L1 L2 and strut iliac grafting. Latest follow up plain X ray: anteroposterior (g) and lateral (h) show good fusion.

Discussion

Burst fractures of the thoracolumbar spine are frequent injuries in the clinical practice. Since short segment pedicular system was introduced for the treatment of thoracolumbar spine fractures, satisfactory results have been frequently reported. This procedure has become the commonly chosen option for surgical treatment of acute burst fractures.^{6,26,31} It allows restoration of the vertebral body height and corrects the local kyphotic angle, as well as indirect reduction of the retropulsed compressing bony fragments in the spinal canal. It also provides the benefit of fixation of fewest segments especially in lumbar spine. In contrast to all these previous advantages, many studies have reported loss of correction and implant failure following the fixation of short segment pedicular system.^{1,2,19}

In this study, 25 patients presented with failure of the short segment pedicular fixation associated

with loss of correction and/or pseudoarthrosis. Many authors could explain the causes of such failure. Weidenbaux and Farcy,³¹ have described 'eggshell' deformity after posterior ligamentotaxis reduction as the gap formed in the vertebral body have been gradually filled with fibrous tissue instead of bony fusion in the long-term. Mc Kormak et al,²² have advanced a classification system based on load sharing in a trial to predict which fracture will fail. The degree of vertebral body damage, spread of fracture fragments, and the amount of angle needed to be corrected are the three factors found important in predicting failure. The higher the load sharing score, the higher is the fixation failure rate.

Pedicle subtraction osteotomy (PSO) has been widely used in the treatment of late post-traumatic kyphosis. The advantages of PSO are a large correction (15°-35°) at a single level, its ability to correct rigid deformity, a single-position procedure and simultaneous ability to decompress dural and

roots. However, there are some disadvantages of PSO which are shortening of the posterior column, increased risk to perform this technique in the presence of extensive epidural scarring in patients with previous laminectomy for this trauma and extensive epidural bleeding during the osteotomy procedure.^{7,11,15,32} Similarly, posterior vertebral column resection and fixation is the best optimal solution in treatment severe, rigid, and angular kyphosis. It allows better posterior and anterior release, better decompression, better severe deformity correction. However, it carries the highest risk of dural injuries with its catastrophic sequence of neurological deficits and excessive bleeding.^{28,33}

In this study, a reasonable strategy was followed to deal with the cases of failed short pedicular system used for fixation of fractures of the thoracic and lumbar spine. Anterior column reconstruction through anterior approach was the standard technique. It was associated with either long segment posterior pedicular fixation or anterior locked plates depending on the mobility of the spine after metal removal of the failed pedicular system and partial facetectomy of the superior and inferior facets of the fractured vertebra. Kyphosis correction using aggressive techniques of osteotomy (e.g. pedicle subtraction osteotomy) or posterior vertebral column resection was avoided. These techniques might be more injurious especially in those 9 patients in whom laminectomy was done in the primary surgery of this study. The strategy of this study was to avoid any endocanal procedure which may be catastrophic especially in cases associated with previous laminectomy. Everard,¹² reported that a previous endocanal procedure will always results in adherence between the neural structures and the bone. If these adhesions have not been carefully released prior any significant deformity correction, the risk for localized traction on the spinal cord and/or nerve roots with neurological deficits consequence is very high.

Anterior approach allows reconstruction of the anterior and middle columns with strut iliac graft or cage and rigid anterior fixation of the spine with various system It also permits direct decompression of the neural elements and less dural manipulation to remove anterior compressing bone fragments. However, There are some disadvantages of anterior reconstruction technique including: lack of familiarity

with anterior approach, requiring specific anesthetic techniques, morbidity of anterior approach, and difficulty to restore the normal anterior column height.¹⁸In this study, no major complications were reported associated with anterior approach. Only 2 transient complications were reported in the form of postoperative weakness of left quadriceps in one patient and left lower limb hotness in another one. The weakened left quadriceps might be due to left L3 root traction and the patient improved after 2 weeks. The hotness of left lower limb might be due to inevitable sympathectomy in labarotomy approach and the patient improved after one year.

Gouhau et al,¹⁶ treated 21 patients with failed internal fixation after thoracolumbar burst fracture. They used different surgical procedures such as anterior corpectomy, vertebroplasty, and posterior pedicle subtraction osteotomy based on individual situation. They reported that LKA improved significantly from $42.5 \pm 15.3^\circ$ preoperatively to $2.3 \pm 3.7^\circ$ postoperatively. At the last follow-up, the loss of correction was $0.7 \pm 0.3^\circ$. Comparable results were noticed in this current study as the LKA improved significantly from $28.47 \pm 10.80^\circ$ preoperatively to $2.07 \pm 9.39^\circ$ immediate postoperatively and maintained at $4.13 \pm 10.21^\circ$ at latest follow up with insignificant correction loss. Radiographic union was achieved in all cases. In our opinion, the achievement of a solid fusion is of great importance for patient satisfaction. This current study demonstrated significant improvement of the back pain as the VAS improved significantly from 6.20 ± 0.94 preoperatively to 1.87 ± 0.83 at latest follow up. Similarly, the functional outcomes (ODI) improved significantly from 62.60 ± 11.17 % preoperatively to 24.00 ± 6.04 % at latest follow up. Comparable results were reported by Gouhau et al,¹⁶ as VAS dropped down from 7.6 to 2.1 and the mean ODI decreased from 48.7% to 10.3%. The pain associated with the failed pedicular short segment fixation might be due to the deformity site itself, the injured disc level, a bony nonunion, or from the lordotic compensation above and below the deformity site which adds stresses on the respective facet joints.²⁷ Anterior column reconstruction associated with either posterior or anterior fixation could solve all previously mentioned problems that might be the causes of severe back pain associated with the failed short pedicular system.

Conclusion

Anterior column reconstruction of the spine through simultaneous combined approaches associated with either posterior or anterior fixation achieved significant improvement in radiological, clinical, and functional outcomes with few complications for treatment of failed short segment pedicular fixation in thoracic and lumbar spine fractures.

References

1. Altay M, Ozkurt B, Aktekin CN, Ozturk AM, Dogan O, Tabak AY: Treatment of unstable thoracolumbar junction burst fractures with short- or long-segment posterior fixation in magerl type a fractures. *Eur Spine J* 16(8):1145–1155, 2007
2. Aono H, Tobimastu H, Ariga K, Kuroda M, Nagamoto Y, Takenaka S, Furuya M, Iwasaki M: Surgical outcomes of temporary short-segment instrumentation without augmentation for thoracolumbar burst fractures. *Injury* 47(6):1337-1344, 2016
3. Bradford DS, McBride GG: Surgical management of thoracolumbar spine fractures with incomplete neurologic deficits. *Clin Orthop* 218:201-216, 1987
4. Brantigan JW: Pseudoarthrosis rate after allograft posterior interbody fusion with pedicle screw and plate fixation. *Spine* 23(17):1829-1831, 1994
5. Briggs M, Closs JS: A distributive study of the use of visual analogue scales and vertebral rating scales for the assessment of postoperative pain in orthopaedic pain. *J Pain Symptom Management* 18:438-446, 1999
6. Cahueque M, Cobar A, Zuniga C, Caldera G: Management of burst fractures in the thoracolumbar spine. *J Orthop* 13 (4): 278-281, 2016
7. Cecchinato R, Berjano P, Damilano M, Lamartina C: Spinal osteotomies to treat post-traumatic thoracolumbar deformity. *Eur J Orthop Surg Traumatol* 24 (1): S31- S37, 2014
8. Dai LY, Jiang SD, Wang XY, Jiang LS. A review of the management of the thoracolumbar burst fractures. *Surg Neurol* 67: 221-231, 2007
9. Dobran M, Nasy D, Brunozzi D, di Somma L, Gladi M, Lacoangeli M, Scerrati M: Treatment of unstable thoracolumbar junction fractures: short-segment pedicle fixation with inclusion of the fracture level versus long-segment instrumentation. *Acta Neurochir (Wien)* 19:1-7, 2016
10. Dvorak MF, Kwon BK, Fisher CG, Eiserloh-HL, Boyd M, Wing PC: Effectiveness of titanium mesh cylindrical cages in anterior column reconstruction after thoracic and lumbar vertebral body resection. *Spine* 28: 902–908, 2003
11. El-Sharkawi MM, Koptan WM, El-Miligui YH, Said GZ: Comparison between pedicle subtraction osteotomy and anterior corpectomy and plating for correcting post-traumatic kyphosis: a multicenter study. *Eur Spine J* 20:1434–1440, 2011
12. Everard M: Surgical treatment of post-traumatic kyphosis in the thoracolumbar spine : indications and technical aspects. *Eur Spine J* 19 (1):S69- S73, 2010
13. Fair JC, Pynsent PB: The Oswestery Disability Index. *Spine* 25: 2940-2952, 2000
14. Frankel HL, Hancock DO, Hyslop G: The value of postural reduction in the initial management of closed injuries with paraplegia and tetraplegia. *Paraplegia* 7: 179, 1969
15. Gao R, Wu J, Yuan W, Yang C, Pan F, Zhou X: Modified partial pedicle subtraction osteotomy for the correction of post-traumatic thoracolumbar kyphosis. *Spine J* 15(9):2009-2015, 2015
16. Guohua, Li Jing, Wang Bing, Kang Wang Xiaobin, L Yijun, Hu Jiao, Deng Youwen: Factors and revision strategy for failure of thoracolumbar spine internal fixation after burst fracture. *J Cent. South Univ (Med Sci)* 37 (10): 1037- 104, 2012
17. Hwang JH, Modi HN, Yang JH, Kim SJ, Lee SH: Short segment pedicle screw fixation for unstable T11-L2 fractures: with or without fusion. A three-year follow-up study. *Acta Orthop* 75 (6):822-827, 2009

18. Kaneda K, Tanechi H, Abumi K: Anterior decompression and stabilization with the Kaneda device for thoracolumbar burst fractures associated with neurologic deficits. *J Bone Joint Surg* 79(Am):69-83, 1997
19. Knop C, Fabian HF, Bastian L, Blauth M: Late results of thoracolumbar fractures after posterior instrumentation and transpedicular bone grafting. *Spine* 26:88-99, 2001
20. Leferink VJ, Zimmermann KW, Veldhuis EF, Vergert EM, Duis HJ: Thoracolumbar spinal fractures: radiological results of transpedicular fixation combined with transpedicular cancellous bone graft and posterior fusion in 183 patients. *Eur Spine J* 10:517-523, 2001
21. Liu F, feng Z, Liu T, Fei Q, Jiang c, Li Y, Jiang X, dong J: A biomechanical comparison of 3 different posterior fixation techniques for 2-level lumbar spinal disorders. *J Neurosurg spine* 24 (3):375-380, 2016
22. Mc Cormack T, Karakovic E, Gaines R: The load sharing classification of spine fracture. *Spine* 19:1741-1744, 1994
23. Mclain RF, Burkus JK, Benson DR: Segmental instrumentation for thoracic and thoracolumbar fractures: Prospective analysis of construct survival and five-year follow up. *Spine* 1:310-323, 2001
24. Modi HN, Chung KJ, Seo IW, Hwang JH, Kim HK, Noh KC, Yoo JH: Two levels above and one level below pedicle screw fixation for the treatment of unstable thoracolumbar fracture with partial or intact neurology. *J Orthop Surg Res* 27:4-28, 2009
25. Reinhold M, Schmoelz W, Canto F, Krappinger D, Blauth M, Knop C: A new distractable implant for vertebral body replacement: biomechanical testing of four implants for the thoracolumbar spine. *Arch Orthop Trauma Surg* 129:359-362, 2009
26. Sait A, Prabhav NR, Sekharappa V, Rajan R, Raj NA, David KS: Biomechanical comparison of short-segment posterior fixation including the fractured level and circumferential fixation for unstable burst fractures of the lumbar spine in a calf spine model. *J Neurosurg Spine* 10:1-8, 2016
27. Schoenfeld AJ, Wood KP, Fisher CF, Fehlings M, Oner FC, Bouchard K, Arnold P, Vaccaro AR, Sekhorn L, Harris MB, Bono CM: Posttraumatic kyphosis: current state of diagnosis and treatment: results of a multinational survey of spine trauma surgeon. *J Spinal Disord* 23(7):e1-e8, 2010
28. Suk SI, Chung ER, Lee SM, Lee JH, Kim SS, Kim JH: Posterior vertebral column resection in fixed lumbosacral deformity. *Spine* 30:E703-E710, 2005
29. Trivedi JM: Spinal trauma: therapy- options and outcomes. *Eur J Radiol* 42:127-134, 2002
30. Verlaan JJ, Diekerhof CH, Buskens E, Van der Tweel I, Verbout AJ, Dhert WJ, Oner FC: Surgical treatment of traumatic fractures of the thoracic and lumbar spine. A systemic review of the literatures on techniques, complications, and outcome. *Spine* 29(7):803-814, 2004
31. Weidenbaux M, Farcy JPC: Surgical management of thoracic and lumbar burst fractures. In: Bridwell KH, Dewald RL, eds. *The Text Book of Spinal Surgery*, 2nd ed. Philadelphia: Lippincott Raven; 1839-1880, 1997
32. Yagi M, Kaneko S, Asazuma T, Machida M: Walking sagittal balance correction by pedicle subtraction osteotomy in adults with fixed sagittal imbalance. *Eur Spine J* 9:1-9, 2016
33. Zhang X, Zhang Y, Wang Z, Chen C, Wang Y: Correction of severe post-traumatic kyphosis by posterior vertebral column resection. *Chin Med J* 123(6):680- 685, 2010
34. Zhou MS, Xie JB, Ding GZ, Wang Q,, Xu ZJ, Fang C, Yang M: Posterior short-segment fixation with undermining decompression for upper lumbar burst fractures. *ZhongguoGu Shang* 28(12):1132-1136, 2015

الملخص العربي

البناء الأمامي للعمود الفقري لعلاج فشل التثبيت الخلفي القصير لمسامير عنق الفقرات المستخدمة في علاج كسور الفقرات الصدرية والقطنية

البيانات الخلفية: يعتبر التثبيت الخلفي القصير للعمود الفقري باستخدام مسامير عنق الفقرات من أشهر الجراحات المستخدمة في علاج كسور الفقرات الصدرية والقطنية المنضغطة. ومع هذا قد تحدث نتائج عكسية مثل عدم التئام الكسر واعوجاج للعمود الفقري وفشل المسامير المستخدمة. وسائل جراحية متعددة وصفت لعلاج مثل هذا الفشل لكن الدراسات الديناميكية أثبتت أن إضافة الترقيع العظمي والبناء الأمامي للعمود الفقري لأي نوع من التثبيت أمامي أو خلفي يعتبر من أفضل الطرق لعلاج هذا الفشل.

تصميم الدراسة: دراسة بأثر رجعي.

الغرض: تقييم النتائج المترتبة على الترقيع العظمي والبناء الأمامي للعمود الفقري لعلاج فشل التثبيت الخلفي القصير لمسامير عنق الفقرات المستخدمة في علاج كسور الفقرات الصدرية والقطنية.

المرضى وطرق العلاج: شملت هذه الدراسة ٢٥ مريضاً يعانون من فشل في التثبيت الخلفي القصير لمسامير عنق الفقرات المستخدمة في علاج كسور الفقرات الصدرية والقطنية. الدراسة شملت ١٤ رجل و ١١ سيدة ويبلغ متوسط أعمارهم حوالي ٣٣ سنة. تمت متابعة هؤلاء المرضى من خلال العيادات الخارجية لقسم جراحات العظام والعمود الفقري بمستشفيات أسبوت الجامعية في الفترة من يناير ٢٠٠٩ حتى ديسمبر ٢٠١٣. تم علاج جميع المرضى برفع المسامير المكسورة والترقيع الأمامي للعمود الفقري مصحوب بالتثبيت الخلفي الطويل باستخدام مسامير عنق الفقرات في ١٦ مريض أو التثبيت الأمامي باستخدام الشرائح الأمامية المؤمنة في تسعة مرضى. تمت متابعة هؤلاء المرضى لفترة لا تقل عن ٢٤ شهراً من خلال متابعة وملاحظة ما يلي: (١) درجة الألم ومقدار تحسنه والحالة العصبية للطرفين السفليين، (٢) درجة التئام الكسر والترقيع العظمي ومقدار التحسن في اعوجاج العمود الفقري من خلال الأشعات العادية والمقطعية، (٣) درجة التحسن الوظيفي العامة للمريض من خلال قدرته على ممارسة حياته الطبيعية والعملية.

النتائج: تحسن الألم بدرجة كبيرة من ٦ قبل العملية إلى ٢ تقريباً في آخر متابعة حسب المقياس التدريجي للألم مع عدم وجود أي مضاعفات عصبية. تحسنت درجة التئام الترقيع العظمي بنسبة ١٠٠% كما تحسنت درجة اعوجاج العمود الفقري من ٢٨ درجة تقريباً قبل العملية إلى درجتين تقريباً بعد العملية مباشرة و ٤ درجات تقريباً في آخر متابعة. تحسنت درجة التحسن الوظيفي من ٦٢% قبل العملية إلى ٢٤% تقريباً في آخر متابعة حسب فهرس المقياس الوظيفي.

المضاعفات: ضعف مؤقت للعضلة الرباعية الأمامية اليسرى لأحد المرضى المصاب بكسر بالفقرة القطنية الأولى والذي تم تثبيته من الخلف مع ترقيع عظمي أمامي وقد تحسنت تماماً بعد أسبوعين. الإحساس بسخونة شديدة بالطرف السفلي الأيسر لأحد المرضى المصاب بكسر بالفقرة القطنية الثانية والذي تم تثبيته من الأمام مع ترقيع عظمي أمامي وقد تحسنت تماماً بعد مرور سنة.

الاستنتاج: الترقيع العظمي والبناء الأمامي للعمود الفقري مصحوباً بتثبيت خلفي أو أمامي أدى إلى تحسن ملحوظ من الناحية الأكلينيكية والإشعاعية والوظيفية مع مضاعفات قليلة في علاج فشل التثبيت الخلفي القصير لمسامير عنق الفقرات المستخدمة في علاج كسور الفقرات الصدرية والقطنية.