

# Posterior Cervicothoracic Stabilization Using Tapered Rods

**Mohamed Youssef Elqazaz, MD.**

*Department of Neurosurgery, Faculty of Medicine, Suez Canal University, Ismailia, Egypt.*

## Abstract

**Background Data:** The cervicothoracic spine is a junction area with complex biomechanics. A variety of disorders affect this region, rendering it unstable. Numerous posterior constructs have been evaluated. The clinical efficacy of a screw-rod system utilizing tapered (dual-diameter) rods in cervicodorsal stabilization is still not evident.

**Purpose:** Our aim is to evaluate the clinical efficacy of dual diameter rods (5.5–3.5mm taper), connecting 3.5-mm cervical lateral mass screws/pedicle screws and 5.5-mm thoracic pedicle screws used to instrument across the cervicothoracic junction for a variety of pathologies.

**Study Design:** A retrospective descriptive clinical case study.

**Patients and Methods:** The authors retrospectively reviewed their archive between February 2011 and February 2015, and ten patients who were operated upon due to cervicothoracic junction pathologies were included. All patients underwent surgical treatment by posterior instrumentation utilizing tapered rods. The cases were periodically followed up.

**Results:** There were six men and four women included in the study, with a mean age of 40 years (range 21–62 years). There were five cases of trauma, two cases of tuberculosis and three cases of spine metastasis. Seven patients experienced marked improvement of their preoperative weakness according to Frankel grades of paraplegia. All patients showed stable cervicodorsal junction with fusion after one year. Three patients suffered postoperative wound infection.

**Conclusion:** Tapered rods are an excellent and a viable option to connect screws to stabilize cervicothoracic junction. (2015ESJ089)

**Key Words:** Cervicothoracic junction, tapered rods, lateral mass screws, cervical pedicle screws.

Received at:

April 18<sup>th</sup>, 2015

Accepted at:

June 19<sup>th</sup>, 2015

## Introduction

The cervicothoracic junction is a transitional zone in which the spine changes rigidity and sagittal plane geometry. The cervical spine has a mean lordosis of approximately 40°, and is relatively flexible. By contrast, the thoracic spine is kyphotic with a mean of 10–40°. It is also rigid owing to articulation with the rib cage and sternum.<sup>32</sup>

A variety of conditions destabilize the cervicothoracic junction, including trauma, tumors, infection, and iatrogenic causes. Instrumentation across the cervicothoracic junction must address its challenging biomechanics. As a transition zone from the flexible, lordotic cervical spine to the rigid thoracic spine, the cervicothoracic junction is subjected to force concentration.<sup>30</sup> When significant instability exists, most authors have recommended combined anterior–posterior treatment.<sup>4,14,18</sup> This trend is due in part to the limitations of fixation at the cervicothoracic junction.<sup>31</sup> Fixation in the sub axial cervical spine is not as rigid as that in the upper thoracic spine. Recent advances in technique and instrumentation, however, have improved fixation, making posterior-only treatment of significant instability possible.

A variety of posterior instrumentation techniques are available, ranging from wiring systems to screw-rod systems. The aim of this study is to evaluate the clinical efficacy of dual diameter rods or tapered rods (5.5–3.5mm taper), connecting 3.5-mm cervical lateral mass screws/pedicle screws and 5.5-mm thoracic pedicle screws used to instrument across the cervicothoracic junction for a variety of pathologies.

## Patients and Methods

This is a retrospective study carried out between February 2011 and February 2015, at the Department of Neurosurgery, Suez Canal University Hospitals (Ismailia, Egypt). A total of ten consecutive patients were followed. Inclusion criteria required all patients to have pathologies in the cervicothoracic spine which is the area between 6th cervical vertebra and 2nd thoracic vertebra. The patients underwent a detailed

history, clinical examination, and were investigated in the form of radiographs, magnetic resonance imaging, and computed tomography (CT) scan of the entire spine. The patients' neurological functions were classified according to Frankel grades<sup>11</sup> of paraplegia (Table 1).

### Surgical Procedure:

All patients were operated using midline posterior skin incision and subperiosteal retraction of the Para spinal muscles to expose the affected segment. 3.5mm cervical lateral mass screws were inserted in the 4th, 5th or 6th cervical vertebra according to level of stabilization needed. C7 lateral masses or pedicle screws were used according to every patient anatomical suitability. Transpedicular screws were used in the upper thoracic vertebrae needed. All cases underwent a posterior instrumented fusion. The screws were connected by dual-diameter rods (tapered rods) which taper up from 3.5mm diameter to accommodate the cervical screws to a diameter of 5.5mm for the thoracic screws (Figure 1). In cases with neoplastic and infective etiologies, biopsy material was obtained and appropriate tests were carried out for further management. Duration of surgery, blood loss, and the duration of inpatient treatment were recorded. Intraoperative and perioperative major and minor complications were assessed.

The patients were periodically followed up for a detailed neurological examination. The patients underwent routine radiographic examination at follow-up visits and a CT scan and MRI at 1-year follow-up.

## Results

A total of ten patients were included in this study including six males and four females. The detailed data of the study group are presented in (Table 2). The age of the patients varied from 21 to 62 years (means 40 years). There were five cases of trauma. There were two cases of tuberculosis. There were three cases of spine metastasis.

In this study, five patients suffered from traumatic insult at the cervicothoracic junction.

Three of them suffered flexion distraction injury with unilateral locked facet in one and bilateral locked facet in the other two patients. Attempted closed cervical traction was tried and failed in the three cases. Surgical open reduction was done by using curettes of variable sizes and spinal stabilization and fusion was done. Two patients were neurologically intact preoperatively and the one with complete paraplegia did not show any improvement after reduction, fixation and physiotherapy. The other two trauma patients got tear drop fracture of the 7<sup>th</sup> cervical vertebra due to flexion compression injury. This was due to diving accidents. Both patients had complete paraplegia. Also they showed no improvement in the follow up.

In the study group, two cases of tuberculosis were included. The lesions affected mainly 7<sup>th</sup> cervical and first thoracic vertebra. They were treated with transpedicular decompression. This eliminated the need for an anterior approach. The anterior column was reconstructed by shortening and end-plate to end-plate apposition and compression. All the patients were started on anti-tuberculosis drugs based on drug sensitivity tests. There was significant improvement in neurological status in the two cases after surgical debridement and chemotherapy as shown in (Table 2).

We had three patients with cervicothoracic metastasis. They had their primary in the lung in two patients and in the prostate in the 3<sup>rd</sup> patient. They were treated by posterolateral decompression & posterior instrumented fusion with improvement of the neurological function of both patients. Radiotherapy was started then after wound healing.

Regarding postoperative complications, infection was the main problem in our study. Two patients showed superficial wound infection which improved by daily dressings and medical treatment and one patient showed deep infection three weeks after surgery in the form of progressive swelling and pain at site surgery. The patient had exploration of the wound and debridement. Surgical drain was inserted deeply in the wound and left for ten days to drain. Intravenous antibiotic were given according to culture and sensitivity.

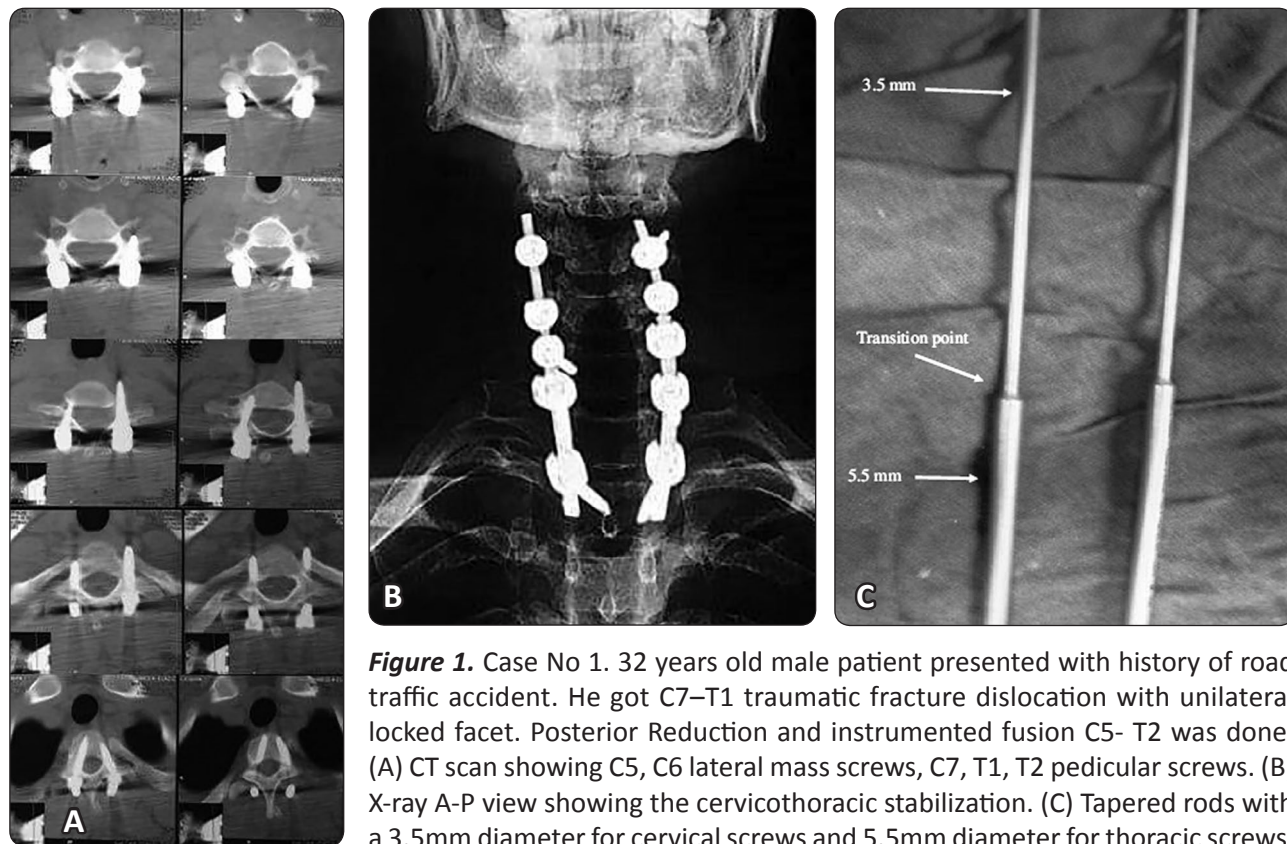
On the basis of the clinical assessment, radiographs, and CT scans, there was no implant failure at final follow up. There was no loss of correction in any of the cases. All cases showed a successful fusion at the end of 1 year. There was a clinical improvement in neurological status in seven of the ten patients (Table 2).

**Table 1.** Frankel Grades of Paraplegia.<sup>11</sup>

<b>Grade A</b>	Complete paralysis
<b>Grade B</b>	Sensory function only below the injury level
<b>Grade C</b>	Incomplete motor function below the injury level
<b>Grade D</b>	Fair to good motor function below the injury level
<b>Grade E</b>	Normal function

Table 2: Patient characteristics and clinical findings in the study series

No.	Age/ Sex	Diagnosis	Level	Surgery	Fusion Levels	Complication	PreOp Frankel	PostOp Frankel
1	32/M	Fracture dislocation, unilat. locked facet	C7–T1	Reduction, instrumented fusion	C5-T2	Deep infection, exploration	E	E
2	56/F	Mets/lung	T1	Decompression, instrumented fusion	C6-T4	–	E	E
3	53//F	TB Spondylodiscitis	C7–T1	Decompression, instrumented fusion	C5-T4	–	D	E
4	29/M	Fracture dislocation, bilat. locked facet	C7–T1	Reduction, instrumented fusion	C5-T3	Superficial infection	A	B
5	32/F	Tear drop fracture, compression flexion type 5	C7	Instrumented fusion	C5- T3	-	A	A
6	62/ M	Mets/prostate	T2	Decompression, instrumented fusion	C7–T4	–	C	D
7	27M	TB epidural abscess	C7–T1	Decompression, instrumented fusion	C5–T4	-	B	D
8	21/M	Fracture dislocation, unilat. locked facet	C7–T1	Reduction, instrumented fusion	C5-T3	-	E	E
9	59/M	Mets /lung	C7	Decompression, instrumented fusion	C4–T3	–	C	D
10	29/F	Tear drop fracture, compression flexion type 5	C7	Instrumented fusion	C5-T3	Superficial infection	B	B



**Figure 1.** Case No 1. 32 years old male patient presented with history of road traffic accident. He got C7–T1 traumatic fracture dislocation with unilateral locked facet. Posterior Reduction and instrumented fusion C5- T2 was done. (A) CT scan showing C5, C6 lateral mass screws, C7, T1, T2 pedicular screws. (B) X-ray A-P view showing the cervicothoracic stabilization. (C) Tapered rods with a 3.5mm diameter for cervical screws and 5.5mm diameter for thoracic screws.

## Discussion

The region of the cervicothoracic transition is characterized by an intermediate zone between the cervical lordosis and the thoracic kyphosis, which leads to a transfer of the load to the posterior arc.<sup>8</sup> This causes an increase in mechanical stress in this transitional region, which added to the anatomical variations, leads to technical difficulties for the passage and effective fixation of screws, prompting the search for options to stabilize of this region.

The biggest challenge in using transpedicular screws in the cervicothoracic region is the technical difficulty of inserting the screws. The small size of the pedicles and the angle of attack for insertion of the screws complicates the surgery. Use of intraoperative fluoroscopy can assist in the placement of these screws. However, the positioning of the C-arm to obtain adequate images may be difficult in some cases.<sup>16,27</sup>

A variety of disorders affect the cervicothoracic junction.<sup>4,7,9,23</sup> Trauma, degeneration, neoplasms, and infections like tuberculosis can potentially destabilize this area. Stabilization of pathologies in this area is challenging because of the small working area and a smaller margin for error as the important viscera of the mediastinum are in close proximity to this region. A number of biomechanical studies have demonstrated the lower cervical spine to be stable in extension and the thoracic spine to be stable in flexion.<sup>4,6,25,28</sup>

Traditionally, anterior approaches are utilized to treat the pathologies in this region. Access to the anterior cervicothoracic junction is difficult and technically demanding, because of the presence of vital structures. This renders the depth of the wound variable due to the sudden change of the cervical lordosis to thoracic kyphosis. Biomechanical studies have demonstrated that anterior plating is inferior to posterior instrumentation and that anterior instrumentation spanning over 2 or more levels requires additional posterior fixation in this region.<sup>1,17,21</sup>

We use the anterior approach only as an adjunct to posterior fixation in cases where there is a significant anterior void. In such a situation, an isolated posterior fixation will fail because a deficient anterior column will prevent the tension-band effect in extension. The posterior fixation provides

a tension-band effect in flexion only in the presence of an intact or minimally compromised anterior column. Biomechanical studies have reflected on this concept.<sup>19</sup> All posterior constructs failed in a three-column injury studied in cadaveric models subject to biomechanical testing.

A variety of implants are available for posterior fixation at the cervicothoracic junction. The oldest and simplest of these are wiring techniques. Sublaminar wires are used in conjunction with Luque rods or the Hartshill rectangle. Numerous reports have described the safety, cost efficiency, and clinical efficacy of this technique. Jackson and Gokaslan<sup>15</sup> have described these implants in management of spinal instability secondary to neoplastic process at the junction with good results. However, these wires are not without complications. The complications reported include cord damage, excessive bleeding, nerve root injuries, and parasthesiae and dyesthesia in the limbs.<sup>13</sup> Furthermore, they cannot be used in situations where a laminectomy is needed and as a consequence long segment fusions are necessitated. The Hartshill and Luque rods are bulky implants which may cause prominence of the skin and subsequent tension on the wound edges leading to necrosis of the skin.

Other systems utilizing hooks and rods are available, and there are 2 studies in literature which have utilized the Cotrell-Dubousset system. The studies have shown good fusion rates and minimum complications. However, insertion of these bulky implants in the cervical canal is fraught with complications. In addition, as decompressive procedures are required in most cases, the surgeon has to fuse more levels necessitating long constructs.<sup>15,17</sup>

Several biomechanical studies have shown lateral mass screws with plates or rods to be superior to posterior wiring techniques.<sup>12,18,26</sup> Many articles utilizing posterior screw and plate constructs have shown good fusion rates.<sup>2,6</sup> However, as the lateral mass screws have variable entry points because of variable inter facet distances, it is difficult to line-up the holes of the plate with the entry points of lateral mass screws. This affects the placement of lateral mass screws, leading to complications.<sup>19,20</sup>

To overcome this, posterior rod and screw constructs were developed. At the cervicothoracic junction, the cervical lateral masses gradually



decrease in size, whereas the thoracic pedicles gradually increase in size. As a consequence, the lateral mass screws become shorter in length and have a more laterally placed entry points, whereas the upper thoracic pedicle screws need to be angulated medially, as reflected by numerous studies.<sup>5,22,24,25,28,29</sup> This causes problems in aligning the rods to fit into the tulips of the cervical and thoracic screws. The advent of polyaxial screws solved the alignment problem.

Various combinations are available, (1) 3.5mm cervical lateral mass screws can be extended into the thoracic spine; (2) the 3.5mm cervical screws can be connected to the 5.5mm thoracic pedicle screws by 2 differing diameter rods connected by a fixed or a hinged domino-connector (wedding band); and (3) the screws can be connected by tapered rods or dual-diameter rods as described earlier.

A biomechanical study of these four constructs (hinged and fixed domino-connectors separate) has been conducted by Tatsumi et al,<sup>30</sup> They concluded that the construct containing all 3.5-mm screws was the weakest and failed consistently at lower loads. The hinged domino construct failed at the hinge axis which was the weakest link in the construct. Theoretically, this could lead to clinical failures. The tapered rod and the solid domino construct were the strongest of all evaluated constructs.

The solid domino-construct is an attractive option. However, at this complex area where the cervical lordosis transitions into thoracic kyphosis, an extensible approach is difficult. Also there is very little space available to manipulate these dominos. The dominos are bulky and rod insertion would require considerable manipulation which could theoretically injure the exposed neural elements. As these dominoes occupy space, bone graft placement may be compromised. In such a situation, the tapered rods offer an excellent fixation method to connect the cervical and thoracic screws. The rod insertion technique is a familiar technique to all spine surgeons. The implants are not bulky and enough space is available for inserting the bone graft. There is a theoretical risk of the rods bending at the transition point, but this has neither been reported in literature nor has been witnessed in our series.<sup>14-32</sup>

The main aim of instrumenting the cervicothoracic junction is to prevent further damage to the neural

structures and stabilize the spine for a sound arthrodesis. Clinically, there was a well-maintained neurological improvement in majority of the patients indicating adequate stabilization of the segments. Radio logically, our study showed no breakage, bending, loosening, or backing out of implants. The tapered rod-screw construct has shown excellent efficacy in posterior instrumentation of the cervicothoracic junction.

## Conclusion

Tapered rods can be considered to be excellent longitudinal connecting members of posterior constructs while instrumenting the cervicothoracic junction. The constructs incorporating these rods have shown no clinical failure in the follow up.

## References

1. Abumi K, Shono Y, Ito M, Taneichi H, Kotani Y, Kaneda K: Complications of pedicle screw fixation in reconstructive surgery of the cervical spine. *Spine* 25:962–969, 2000
2. Anderson PA, Henley MB, Grady MS, Montesano PX, Winn HR: Posterior cervical arthrodesis with AO reconstruction plates and bone graft. *Spine* 16(suppl):72–79, 1991
3. An HS, Gordin R, Renner K: Anatomic considerations for plate screw fixation of the cervical spine. *Spine*. S548–S551, 1991
4. An HS, Vaccaro A, Cotler JM, Lin S: Spinal disorders at the cervicothoracic junction. *Spine* 19:2557–2564, 1994
5. Bailey AS, Stanescu S, Yeasting RA, Ebraheim NA, Jackson WT: Anatomic relationships of the cervicothoracic junction. *Spine* 20:1431–1439, 1995
6. Chapman JR, Anderson PA, Pepin C, Toomey S, Newell DW, Grady MS: Posterior instrumentation of the unstable cervicothoracic spine. *J Neurosurg* 84: 552–558, 1996
7. Delamarter RB, Batzdorf U, Bohlman HH: The C7-T1 junction: problems with diagnosis, visualization, instability and decompression. *Orthop Trans* 13:218, 1989

8. Ebraheim NA, Xu R, Knight T, Yeasting RA: Morphometric evaluation of lower cervical pedicle and its projection. *Spine* 22 (1):1-6, 1997
9. Evans DK: Dislocations at the cervicothoracic junction. *J Bone Joint Surg* 65B:124–127, 1991
10. Fagerstrom T, Hedlund R: Cotrel Dubousset instrumentation in occipitocervico-thoracic fusion. *Eur Spine J* 11:364–374, 2002
11. Frankel HL, Hancock DO, Hyslop G, Melzak J, Michaelis LS, Ungar GH, Vernon JDS, Walsh JJ: The value of postural reduction in the initial management of closed injuries of the spine with paraplegia and tetraplegia. I. Paraplegia 7:179–192, 1969
12. Gill K, Paschal S, Corin J, Ashman R, Bucholz RW: Posterior plating of the cervical spine: a biomechanical comparison of different posterior fusion techniques. *Spine* 13:813–816, 1988
13. Girardi FP, Boachie-Adjei O, Rawlins BA: Safety of Sublaminar wires with Isola instrumentation for the treatment of idiopathic scoliosis. *Spine* 6:691–695, 2000
14. Grubb MR, Currier BL, Stone J, Warden KE, An KN: Biomechanical evaluation of posterior cervical stabilization after a wide laminectomy. *Spine* 22:1948–1954, 1997
15. Jackson RJ, Gokaslan ZL: Occipito cervico thoracic fixation for spinal instability in patients with neoplastic processes. *J Neurosurg* 91(suppl):81–89, 1999
16. Koktekir E, Ceylan D, Tatarli N, Karabagli H, Recber F, Akdemir G: Accuracy of fluoroscopically-assisted pedicle screw placement: analysis of 1,218 screws in 198 patients. *Spine J* 14(8):1702-8, 2014
17. Korovessis P, Katonis P, Aligizakis A, Christoforakis J, Baikousis A, Papazisis Z, Petsinis G: Posterior compact Cotrel-Dubousset instrumentation for occipito cervical, cervical and cervicothoracic fusion [see comment]. *Eur Spine J* 10:385–394, 2001
18. Kotani Y, Cunningham BW, Abumi K, McAfee PC: Biomechanical analysis of cervical stabilization systems. *Spine* 19:2529–2539, 1994
19. Kreshak JL, Kim DH, Lindsey DP, Kam AC, Panjabi MM, Yerby SA: Posterior stabilization at the cervicothoracic junction: a biomechanical study. *Spine* 27:2763–2770, 2002
20. Mazel C, Hoffmann E, Antonietti P, Grunenwald D, Henry M, Williams J: Posterior cervicothoracic instrumentation in spine tumors. *Spine* 29:1246–1253, 2004
21. McAfee PC, Bohlman HH, Ducker TB, Zeidman SM, Goldstein JA: One-stage anterior cervical decompression and posterior stabilization: a study of one hundred patients with a minimum of two years of follow-up. *J Bone Joint Surg Am* 77:1791–1800, 1995
22. Moroney SP, Schultz AB, Miller JA, Andersson GB: Load-displacement properties of lower cervical spine motion segments. *J Biomech* 21:769–779, 1988
23. Nicols CG, Young DH, Schiller WR: Evaluation of cervicothoracic junction injury. *Ann Emerg Med* 16:640–642, 1987
24. Panjabi M: Cervical spine models for biomechanical research. *Spine* 23:684–700, 1998
25. Panjabi MM, Brand RA Jr, White AA: Three-dimensional flexibility and stiffness properties of the human thoracic spine. *J Biomech* 9:185–192, 1976
26. Pelker RR, Duranceau JS, Panjabi MM: Cervical spine stabilization: a three-dimensional, biomechanical evaluation of rotational stability, strength, and failure mechanisms. *Spine* 1:117–122, 1991
27. Pelton MA, Schwartz J, Singh K: Subaxial cervical and cervicothoracic fixation techniques--indications, techniques, and outcomes. *Orthop Clin North Am* 43(1):19-28, 2012
28. Shea M, Edwards WT, White AA, Hayes WC: Variations of stiffness and strength along the human cervical spine. *J Biomech* 24:95–107, 1991
29. Stanescu S, Ebraheim NA, Yeasting R, Bailey AS, Jackson WT: Morphometric evaluation of the cervicothoracic junction: practical considerations for posterior fixation of the spine. *Spine* 19:2082–2088, 1994

30. Tatsumi RL, Yoo JU, Liu Q, Hart RA: Mechanical comparison of posterior instrumentation constructs for spinal fixation across the cervicothoracic junction. Spine 32:1072–1076, 2007
31. Vaccaro AR, Falatyn SP, Scuderi GJ, Eismont FJ, McGuire RA, Singh K, Garfin SR: Early failure of long segment anterior cervical plate fixation. J Spinal Disord 11: 410–415, 1998
32. Youdas JW, Garrett TR, Suman VJ, Bogard CL, Hallman HO, Carey JR: Normal range of motion of the cervical spine: an initial goniometric study. Phys Ther 72:770–780, 1992

Address reprint  
request to:

**Mohamed ElQazaz, MD.**

Department of Neurological Surgery, Faculty of Medicine, Suez Canal University Hospital, Ismailia, Egypt 15213.  
Email: myalqazaz@gmail.com

### تثبيت الفقرات العنقية الصدرية باستخدام القضبان المستدقة

**المقدمة:** تمثل منطقة العمود الفقري العنقي الصدري منطقة تقاطع معقدة من حيث الميكانيكا الحيوية. هناك مجموعة متنوعة من الاضطرابات تؤثر على هذه المنطقة، مما يجعلها غير مستقرة، إن تقييم الفعالية السريرية لنظام القضيبي (ثنائي القطر) في استقرار العمود الفقري العنقي الصدري لا تزال غير واضحة.

**الهدف:** توضيح الخصائص الأكلينيكية والنتائج الجراحية لاستخدام نظام القضيبي (ثنائي القطر) في استقرار العمود الفقري العنقي الصدري.

**تصميم الدراسة:** دراسة وصفية تشمل ١٠ مرضى

**طريقة الدراسة:** دراسة لحالات أكلينيكية على ١٠ مرضى بإصابات الفقرات العنقية الصدرية. تم إجراء تقييم تحليلي بأثر رجعي خلال الفترة من فبراير ٢٠١١ حتى فبراير ٢٠١٥ للنتائج السريرية والإشعاعية للمرضى الذين خضعوا للجراحة باستخدام نظام القضيبي (ثنائي القطر) وذلك بقسم جراحة المخ والأعصاب بمستشفى جامعة قناة السويس بالإسماعيلية.

**النتائج:** شملت الدراسة ستة رجال وأربع نساء مع متوسط أعمارهم ٤٠ عاماً (المدى ٢١-٦٢ سنة). كانت هناك خمس حالات إصابات، وحالتين من حالات السل وثلاث حالات من ورم خبيث في العمود الفقري. شهدت سبعة مرضى تحسناً ملحوظاً من ضعفهم قبل الجراحة وفقاً لدرجات فرانكل من الشلل النصف. أظهر جميع المرضى استقرار تقاطع الفقرات العنقية الصدرية مع اللحام العظمي بعد سنة واحدة. عانى ثلاثة مرضى التهاب الجرح بعد العملية الجراحية.

**الاستنتاج:** يعتبر القضيبي المستدق خياراً ممتازاً وخياراً قابلاً للتطبيق لربط مسامير تثبيت تقاطع الفقرات العنقية الصدرية.