

# Functional Outcomes following Surgical Management of Intradural Extramedullary Spinal Cord Tumors

Mohamed Elzoghby,<sup>1</sup> MD., Abdelaal Abdelbaky,<sup>2</sup> MD.

Neurosurgery Departments, faculty of Medicine, AinShams<sup>1</sup> and Banha<sup>2</sup> Universities, Cairo, Egypt.

## Abstract

**Background Data:** Intradural extramedullary tumors are mostly benign lesions that often present late due to their slow rate of growth. Recent advances in the field of neuro-imaging have greatly increased the ability to identify these tumors in early stages. The most effective treatment modality for these tumors is gross total resection, which can sometimes be associated with neurological morbidity and functional impairment.

**Purpose:** to evaluate the functional outcomes following surgical excision of intradural extramedullary spinal tumors.

**Study Design:** This is a retrospective cohort clinical case study.

**Patients and Methods:** In this study the medical records of patients who underwent surgery for intradural extramedullary tumors at Ain Shams University Hospitals and Banha University Hospital between 2012 and 2015 were reviewed. Patient's demographics, clinical presentation, radiographic findings, tumor location, histopathological findings and neurological outcome were documented from patients' files. Pain was evaluated by Visual Analog Scale and neurological function was graded before and after surgery by Nurick's Functional Grading System.

**Results:** This study included sixteen patients with intradural extramedullary mass lesions. Six were males (37%) and 10 were females (63%), mean age at presentation was 41 years (range 24 to 63 years). Histopathologically, there were 10 schwannomas (62%), 4 meningioma (%25) and 2 Neurofibromas (%13). Based on the location, we had 9 thoracic, 3 cervical and 3 lumbar lesions. There was improvement of the mean VAS score from 7.8 preoperative

Received at:  
July 28<sup>th</sup>, 2015

Accepted at:  
September 17<sup>th</sup>, 2015

to 1.6 postoperative, as well as the mean Nurick's grade from 3.1 preoperatively to 1.6 postoperatively. **Conclusion:** Intradural extramedullary tumors are almost benign and slowly growing lesions that may be asymptomatic for many years before presentations. These tumors can be surgically excised through a standard posterior approach. Favorable outcome can be achieved by early diagnosis and early treatment with maximal tumor resection. (2015ESJ100)

**Keywords:** Intradural extramedullary tumors, spinal cord tumors, functional outcome, Nurick's Functional Grading.

## Introduction

Spinal cord tumors represent 10% of central nervous system tumors. Intramedullary location represents the largest percentage in children while intradural extramedullary tumors represent around 60% in adults and most commonly reported in the dorsal region more than cervical and lumbar regions. Histopathologically, most of those tumors are nerve sheath tumors and meningiomas.<sup>3,4,5</sup> Nerve sheath tumors arise from supporting cells adjacent to neurons within spinal nerve roots and they represent around 50% of intradural extramedullary lesions. They are either categorized as schwannomas which accounts for 85% or neurofibromas accounting for the remaining 15%.<sup>15</sup> Meningiomas are the second most common intradural extramedullary tumors, representing 40%. They arise from arachnoid cap cells and are seen four to nine times more frequently in women than in men.<sup>9</sup>

Intradural extramedullary tumors are typically slow growing lesions that may be asymptomatic for many years before presentations. The presenting symptoms are usually influenced by tumor's spinal level and size. Both cervical and thoracic tumors can enlarge and compress the cord resulting in myelopathy. Cervical tumors are more likely to present with neck pain, brachialgia and hand weakness. Thoracic tumors often present with back pain, myelopathy and sensory disturbances in lower half of the body. Tumors of the cauda equina usually may cause back pain, sciatica, weakness in lower limbs and sphincters disturbances.<sup>10,12</sup> Gadolinium-enhanced MRI greatly increase the

ability to identify the tumors in early stage and its relation to the spinal cord. The most effective treatment of intradural extramedullary tumors is total excision.<sup>16</sup>

## Patients and Methods

This is a retrospective cohort clinical case study, conducted on 16 patients with intradural extramedullary spinal cord tumors, operated upon at Ain Shams University Hospitals and Banha University Hospital, between 2012 and 2015. Patients' demographics, clinical presentation, radiographic findings, tumor location, histopathological findings and neurological outcome were documented from patients' files. Pain was evaluated by visual analog scale (VAS) and neurological function was graded before and after surgery according to Nurick's Functional Grading System.<sup>13</sup> The mean follow up period was 6 month ranging from 3 to 14 months.

### Surgical Technique:

Systemic antibiotics were administered one hour before surgery. Under general anesthesia the patient was placed in prone position. Tumor's spinal level was marked with the aid of intraoperative C-arm. Sterilization and draping was done. A posterior midline skin incision was made and fascia was divided and the para-spinal muscles were stripped exposing the lamina. Laminectomy was performed in 14 cases, while in the remaining 2 cases hemilaminectomy was sufficient. Bone waxing and homeostasis was done prior to durotomy to maintain a clear intradural operative field. Operating microscope was used for opening the dura and tumor resection. The dura was tented

over a cottonoid lining the epidural space at the limit of laminectomy and secured to the paravertebral muscles. Tumor was dissected from surrounding neuronal elements and removed en bloc if possible (Figure 1), while piecemeal tumor removal was used in large tumors. The remaining part of the tumor was inspected properly to identify its origin from the nerve root. If the tumor was found to be attached to the dura, the dural attachment was coagulated using bipolar coagulation. After removal of tumor, hemostasis was achieved and the dura was sutured with Prolene 4-0 in a water tight fashion. Dural graft was used in one case of meningioma. Sub-fascial drain was inserted and the wound was closed anatomically in layers.

## Results

### **Patient Demographics:**

This study included sixteen patients with intradural extramedullary tumors, 6 were males (37%) and 10 were females (63%). Mean age at presentation was 41 years (Range 24 to 63 years). Histopathologically, there were 10 schwannomas (62%), 4 meningioma (25%) and 2 neurofibromas (13%). Based on the anatomic location, there were 9 thoracic, 3 cervical and 3 lumbar lesions. The most common presenting symptom was pain which was observed in all patients, motor weakness was present in 11 patients while sphincter disturbance was reported in 4 patients. Ten patients were

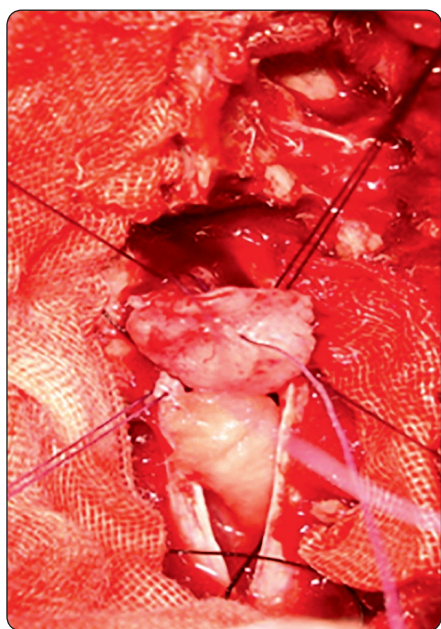
ambulant, 4 were ambulant with help and 2 patients were wheel chair bound. The mean preoperative VAS was 7.8 and the mean preoperative Nurick's grade was 3.1.

### **Patient Outcomes:**

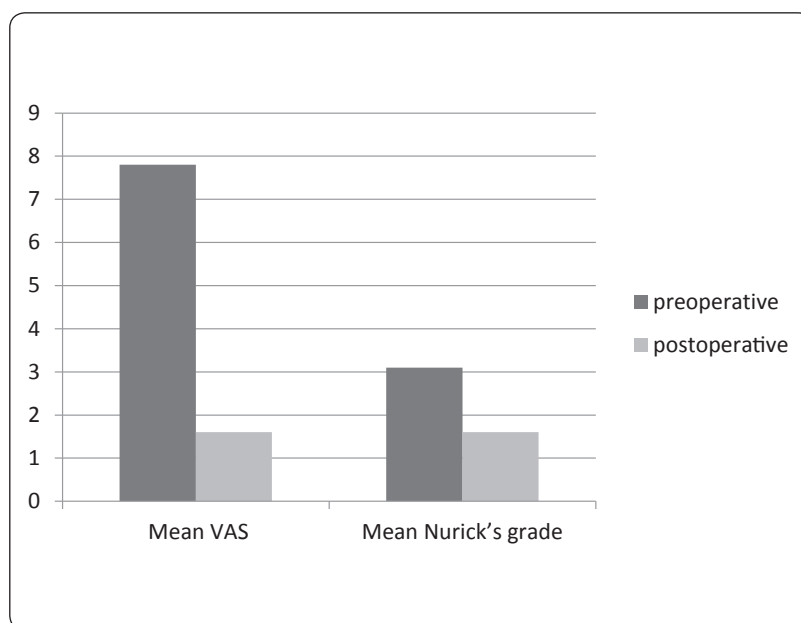
The mean VAS score was reduced from 7.8 preoperatively to 1.6 three months postoperatively (Figure 2). Preoperatively, according to Nurick's grading system there were two cases classified as grade 1, three cases as grade 2, five cases as grade 3 and four cases as grade 4 and two cases as grade 5. At three months after surgery ten cases were Nurick's grade 1, two cases were grade 2, three cases were grade 3 and one case was grade 4 (Table 1, Figure 3). Total resection (Figure 4) was achieved in 14 cases (87%). In the remaining 2 cases (13%), subtotal resection was achieved. The reason for subtotal resection was anterolateral tumor location in a case with meningioma and an intervertebral foramen extension in a case with schwannoma. These 2 patients are being followed up by regular clinical examination and Magnetic Resonance Imaging every 6 months in the first year and annually afterwards. Postoperative complications were experienced in 2 patients (13%), one of them had cerebrospinal fluid leak which required insertion of a lumbar drain and the other one had wound infection that was treated by antibiotics and debridement. None of our patients experienced any new neurological deficit. There was no tumor recurrence during the period of follow up.

**Table 1.** Study population and outcomes.

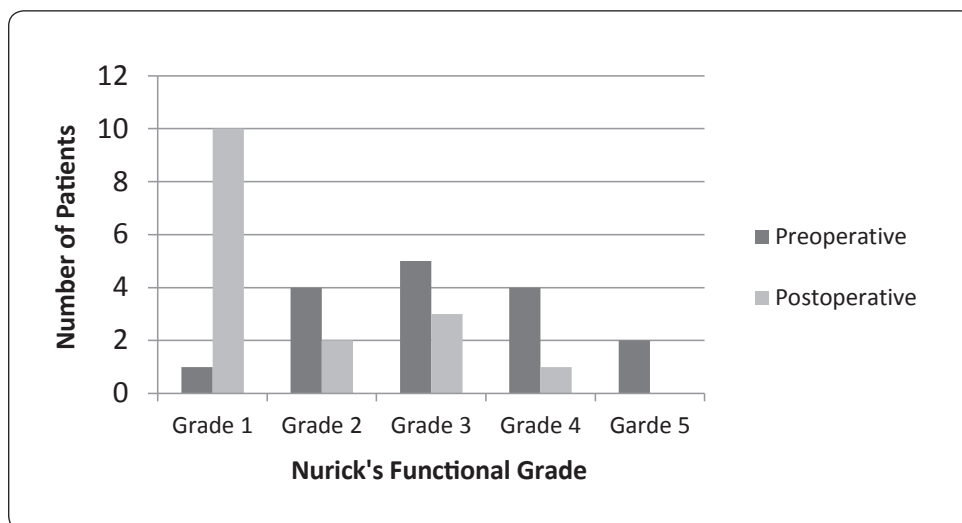
No	Sex	Age	Location	Pre-Op VAS	Post-Op VAS	Pre-Op Nurick	Post-Op Nurick	Excision	Histopathology
1	M	58	Cervical	8	2	4	1	Total	Neurofibroma
2	F	30	Dorsal	7	2	5	2	Total	Schwanoma
3	F	58	Dorsal	7	1	2	1	Total	Meningioma
4	F	24	Dorsal	10	2	3	1	Total	Neurofibroma
5	F	42	Lumber	8	2	2	1	Total	Schwanoma
6	M	33	Dorsal	9	3	5	4	Total	Schwanoma
7	F	38	Dorsal	8	2	3	1	Total	Schwanoma
8	M	29	Lumber	8	1	2	1	Total	Schwanoma
9	F	63	Dorsal	6	0	4	2	Subtotal	Meningioma
10	F	40	Cervical	9	2	4	3	Total	Meningioma
11	M	45	Dorsal	7	1	3	1	Total	Schwanoma
12	M	27	Dorsal	9	2	4	3	Total	Schwanoma
13	F	54	Dorsal	7	2	3	3	Total	Meningioma
14	F	38	Cervical	8	2	3	1	Total	Schwanoma
15	M	52	Dorsal	7	1	2	1	Subtotal	Schwanoma
16	F	39	Lumber	7	1	1	1	Total	Schwanoma



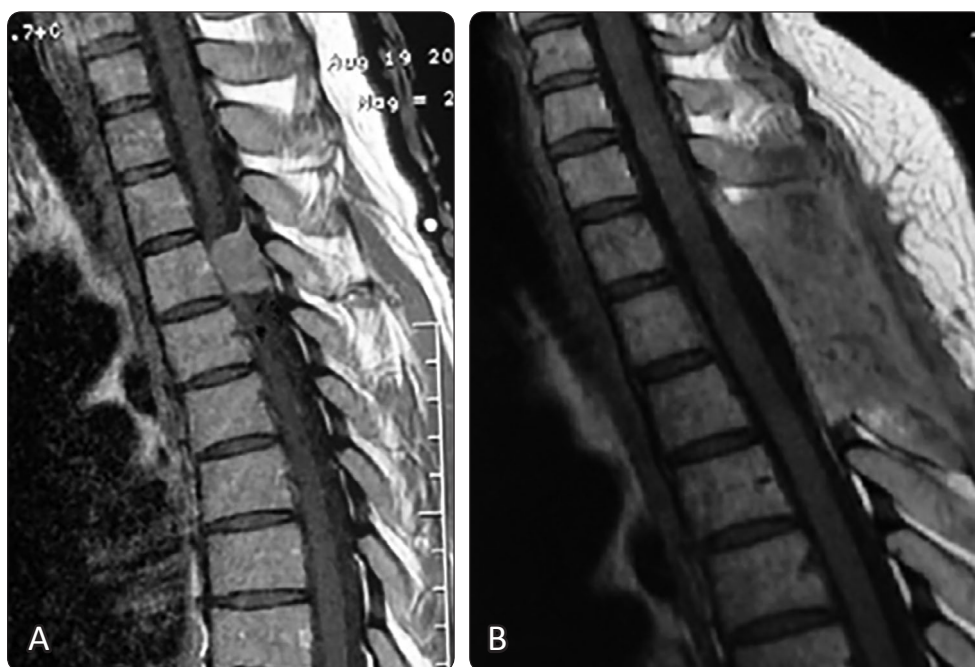**Figure 1.** Intraoperative Photo, showing en bloc total resection of a D3 shwannoma.



**Figure 2.** Preoperative and postoperative Mean VAS score and mean Nurick's Functional Grade



**Figure 3.** Preoperative and postoperative Nurick's Functional Grading



**Figure 4.** (A) Preoperative contrasted T1WI MRI cervical spine sagittal view showing a dorsal meningeioma, (B) Postoperative contrasted T1WI MRI cervical spine sagittal view showing complete resection.

## Discussion

The development of spinal cord tumor surgery began in 1887 when Dr. Horsley removed an intradural extramedullary tumor located at dorsal spine in male patient who presented with spasticity and paraplegia.<sup>7</sup> After surgery

the patient made remarkable recovery and regained the ability to walk. Since then, surgery for spinal cord tumor has evolved through the advent of new techniques such as microsurgery, neuroimaging and intraoperative monitoring. As most of intradural extramedullary tumors are benign, well circumscribed and show clear

demarcations to spinal cord tissue, surgery offers good chance for total excision of the tumor. Early diagnosis and early management of spinal tumors remain the most crucial elements affecting the outcome of such tumors.<sup>2</sup>

Prevedello et al,<sup>14</sup> studied 44 patients with intradural extramedullary tumors, their mean age was 32.9 years, most of tumors were located at the thoracic spine (45.5%), Schwannoma was the most common tumor (65.9%) followed by meningioma (20.5%). Similarly in our series, most of our patients were in 3<sup>rd</sup> and 4<sup>th</sup> decade of their life, thoracic spine was the commonest location and Schwannomas were the commonest type of tumor encountered. Song et al,<sup>17</sup> reported in their series that the most common presenting symptoms were pain in 83.3% of patients followed by motor weakness in 50%, sensory disturbance in 41.6% and sphincter disturbance in 33.3%. In our study, the most common presenting symptoms were pain in 100% of patients. The second most common symptoms were motor weakness 68% followed by sphincter disturbance in 25%.

Many studies of intradural extramedullary tumors reported marked improvement of pain after surgery. Ahn et al,<sup>1</sup> revealed that the mean VAS score was reduced in all cases from 8 before surgery to 1.2 after surgery, whereas Ahsan et al,<sup>2</sup> reported a reduction of the mean VAS score from 7.67 preoperatively to 1.14 postoperatively. Consistent with previous studies, in our series the mean VAS score was reduced from 7.8 preoperative to 1.6 postoperative.

Although each study of intradural extramedullary tumors used different scale as a measuring tool to assess the pre and post-operative neurological status, all of them reported significant neurological improvement after surgery. Konovalov et al,<sup>11</sup> reported that 50% of patients moved to higher functional class of McCormick scale after laminectomy and resection of tumor. Similarly, Gu et al,<sup>6</sup> revealed that 93% of their patients had improved frankel

grade, whereas 7% of patients had no change in their grade after surgery. Ahsan et al,<sup>2</sup> and Ahn et al<sup>1</sup> reported that the mean Nurick's grade has improved from 3 preoperatively to one postoperatively. Consistent with previous studies, in our series there was improvement of the mean Nurick's grade from 3.1 preoperatively to 1.6 postoperatively.

The goal of treatment of intradural extramedullary tumors is maximal tumor removal without neurological injury. In this series, total resection was achieved in 87.5% of cases and subtotal resection in 12.5% of cases. Similar outcomes were observed by kim et al,<sup>8</sup> who reported complete resection of tumor in 94% of cases and Turel et al,<sup>18</sup> who achieved total removal in 93% of cases in their series.

## Conclusion

Intradural extramedullary tumors are mostly benign and slowly growing lesions that may be asymptomatic for many years before presentation. These tumors can be resected through a standard posterior approach. Favorable outcomes can be achieved by early diagnosis and total resection of the tumor.

## References

1. Ahn DK, Park HS, Choi DJ, Kim KS, Kim TW, Park SY: The surgical treatment for spinal intradural extramedullary tumours. Clinics in orthopaedic surgery 1(3):165-172, 2009
2. Ahsan K, Awwal A, Khan SI, Haque H, Zaman N: Intradural extramedullary spinal cord tumours: A retrospective study of surgical outcomes. Bangabandhu Sheikh Mujib Medical University Journal 9(1):11-17,2016
3. Brisman MH, Perin NI, Post KD: Excision of Spinal Neurofibromas. In: operative neurosurgery edited by Andrew H. Kaye and Peter Mcl Black Volume 2, London: Churchill living stone 1937:1946, 2000

4. Broager B: Spinal neurinoma a clinical study comprising 44 cases with a discussion of histological origin and with special reference to differential diagnosis against spinal glioma and meningioma. *Acta Psychiatr Neurol Scand Suppl* 85:1-241, 1953
5. Constantini S, Epstein F: Intraspinal tumors in children and infants. In: Youmans JR., Becker DP., Dunsker SB., et al (eds): *Neurological Surgery*, ed 4. Philadelphia: WB Saunders, 3123-3133, 1996
6. Gu R, Liu JB, Xia P, Li C, Liu GY, Wang JC: Evaluation of hemilaminectomy use in microsurgical resection of intradural extramedullary tumours. *Oncology letters* 7(5):1669-1672, 2014
7. Horsley V, Gowers W. A case of tumours of the spinal cord. Removal, recovery. *Med Chir Trans Soc London* 71:377-430,1888
8. Kim CH, Chung CK: Surgical outcome of a posterior approach for large ventral intradural extramedullary spinal cord tumors. *Spine* 36(8):E531-E537,2011
9. Klekamp J, Samii M: Surgical results for spinal meningioma. *Surgical Neurology* 52(6):552-62, 1999
10. Klekamp J SM: *Surgery of spinal tumors*. New York, Springer Berlin Heidelberg, 2007
11. Konovalov NA, Shevelev IN, Nazarenko AG, Asiutin DS, Korolishin VA, Timonin S et al: The use of minimally invasive approaches to resect intradural extramedullary spinal cord tumors. *Zhurnal voprosy neirokhirurgii imeni NN Burdenko* 78(6):24-34, 2013
12. McCormick PC, Post KD, Stein BM: Intradural extramedullary tumors in adults. *Neurosurgery Clinics of North America* 1(3):591-608.1990
13. Nurjck S: The pathogenesis of the spinal cord disorder associated with cervical spondylosis. *Brain* 95(1):87-100, 1972
14. Prevedello DM, Koerbel A, Tatsui CE, Truite L, Grande CV, Ditzel LF et al: Prognostic factors in the treatment of the intradural extramedullary tumors: a study of 44 cases. *Arq Neuropsiquiatr* 61:241-247, 2003
15. Seppälä MT, Haltia MJ, Sankila RJ, Jääskeläinen JE, Heiskanen O: Long-term outcome after removal of spinal schwannoma: a clinicopathological study of 187 cases. *Journal of Neurosurgery* 83(4):621-626, 1995
16. Shin JH, Benzel EC: Intradural Extramedullary Spine Tumors. *Contemporary Spine Surgery* 13(2):1-7, 2012
17. Song KW, Shin SI, Lee JY, Kim GL, Hyun YS, Park DY: Surgical results of intradural extramedullary tumors. *Clinics in Orthopedic Surgery* 1(2):74-80, 2009
18. Turel MK, D'Souza WP, Rajshekhar V: Hemilaminectomy approach for intradural extramedullary spinal tumors: an analysis of 164 patients. *Neurosurgical focus* 39(2):E9, 2015

Address reprint  
request to:

**Khaled Mohammed Hassan Ali, MD.**

Orthopaedic department (Spine Unit), Assiut University Hospitals. Egypt

E mail: khaledhyounes@yahoo.com

## الملخص العربي

### النتائج الوظيفية للتدخل الجراحي لعلاج الأورام الواقعة داخل الأم الجافية وخارج الحبل الشوكي بالعمود الفقري

**البيانات الخلفية:** تعتبر معظم الأورام الواقعة داخل الأم الجافية وخارج الحبل الشوكي من الأورام الحميدة وتظهر أعراضها متأخرا نتيجة إلى بطء معدل نموها. و لقد ساعدت التطورات الحديثة في مجال فحوصات المخ والأعصاب بشكل كبير من القدرة على تشخيص هذه الأورام في مراحل مبكرة ويعد الاستئصال الكلي للورم هو الطريق الأكثر فعالية للعلاج ولكنه في بعض الأحيان يكون مصحوبا ببعض المضاعفات العصبية والاضطرابات الوظيفية.

**الغرض:** لتقييم النتائج الوظيفية التالية للاستئصال الجراحي للأورام داخل العمود الفقري خارج النخاع الشوكي. **تصميم الدراسة:** دراسة بأثر رجعي.

**المرضى وطرق البحث:** تم استعراض السجلات الطبية للمرضى الذين خضعوا لجراحة استئصال أورام داخل الأم الجافية وخارج الحبل الشوكي في مستشفى جامعة عين شمس ومستشفى جامعة بنها بين عامي ٢٠١٢ و ٢٠١٥. تم دراسة البيانات الديموغرافية والحالة السريرية للمرضى، نتائج فحوصات الأشعة، موقع الورم، نتائج تحليل الأنسجة ونتائج الجراحة من الناحية الوظيفية والعصبية. تم تقييم الألم باستخدام مقياس التناظرية البصرية وتقييم الحالة العصبية باستخدام مقياس نرذ وذلك قبل وبعد الجراحة وكانت متوسط فترة متابعة المرضى هي ستة أشهر (تتراوح بين ٢ و ١٤ شهرا)

**النتائج:** شملت هذه الدراسة ستة عشر مرضى من الذين يعانون من أورام داخل الأم الجافية وخارج الحبل الشوكي. ستة (٣٧%) من الذكور و ١٠ (٦٣%) من الإناث، كان متوسط عمر المرضى ٤١ عاما (يتراوح ما بين ٢٤ و ٦٣ عاما). من حيث نتائج تحليل الأنسجة كان هناك ١٠ (٦٢%) حالات شونوما و ٤ (٢٥%) سحائي و ٢ (١٣%) ورام ليفي عصبي. ومن حيث مكان الورم كان هناك ٩ أورام في مستوي الفقرات الصدرية و ٣ في مستوي الفقرات العنقية و ٣ في مستوي الفقرات القطنية. تحسن متوسط درجة الألم من ٧.٨ قبل الجراحة إلى ١.٦ بعد الجراحة وكذلك تحسن متوسط درجة نرذ من ٣.١ قبل الجراحة إلى ١.٦ بعد الجراحة.

**الخلاصة:** تعد غالبية الأورام الواقعة داخل الأم الجافية وخارج الحبل الشوكي من الأورام الحميدة وذات النمو البطيء وعادة لا تظهر أعراضها إلا بعد مرور عدة سنوات. يمكن استئصال هذه الأورام من خلال التدخل الجراحي من الخلف ويمكن تحقيق نتائج جيدة عن طريق التشخيص المبكر والعلاج المبكر باستئصال الورم.