

# Minimally Invasive Percutaneous Transpedicular Screw Fixation of Acute Thoracolumbar Fractures

**Abdelaal Abdelbaky, MD.**

*Neurosurgery Departments, Benha University, Egypt, and Alhayat National Hospital, Kingdom of Saudi Arabia.*

## Abstract

**Background Data:** Percutaneous transpedicular fixation systems have become more frequently used as it allows the surgeon to achieve same goals as standard open surgery but in a less invasive manner by insertion of pedicle screws and pre-contoured rods through a stab incision and elimination of the need for excessive muscle dissection.

**Purpose:** The aim of this study is to evaluate the outcome of percutaneous fixation of acute thoracolumbar fractures.

**Study Design:** A retrospective study.

**Patients and Methods:** Retrospective review of patients with acute thoracolumbar fractures without neurological deficit treated with percutaneous fixation from January 2011 to January 2015. Baseline data include patient's demographics, operative data, mechanism of injury, fracture level and kyphotic angle. Pain was assessed using visual analogue scale and radiological outcome was assessed as the amount of kyphotic angle correction.

**Results:** Seventeen patients with thoracolumbar fractures were included in this study, 14 patients were male and 3 were female. The mean age of the patients was 41 years. The mode of fracture was fall from height in 13 patients and motor car accident in 4 patients. The mean operative time was 110 minute. The average hospital stay was 3 days. The mean kyphotic angle improved from 24 degrees before surgery to 7 degrees after surgery. The mean VAS improved from 8.4 preoperatively to 1.8 postoperatively.

Received at:  
September 21<sup>st</sup>, 2015

Accepted at:  
December 19<sup>th</sup>, 2015

**Conclusion:** Fluoroscopic guided percutaneous transpedicular screw fixation can provide a safe and effective treatment for acute thoracolumbar fractures with significant reduction in blood loss, postoperative pain and hospital stay. (2015ESJ103)

**Keywords:** Percutaneous fixation, minimally invasive surgery, thoracolumbar fractures

## Introduction

The thoracolumbar junction is the most common injury site for thoracic and lumbar trauma. Most patients are young males involved in high energy accidents. Twenty to forty percent of fractures are associated with neurologic injuries.<sup>1,4,7</sup> surgical treatment of thoracolumbar fractures is deemed necessary if the biomechanical stability of the spine is severely compromised and if a neurologic deficit is imminent or already present. The treatment goals are to decompress the spinal canal, to maintain or restore spinal alignment and stability, preserve neurological function and mobilize the patient as soon as possible.<sup>6</sup>

Open transpedicular fixation for thoracolumbar fractures was first introduced by Roy-Camille<sup>17</sup> in 1963. While Percutaneous fixation of the lumbar spine was first described by Magerl<sup>12</sup> who used an external fixator for the treatment of spinal instability secondary to acute trauma. Mathews and Long<sup>13</sup> first performed percutaneous lumbar fixation technique in which they used plates as the longitudinal connectors. Lowery and Kulkarni subsequently described a similar technique in which rods were placed.<sup>11</sup>

Standard open placement of pedicle screws requires midline incision extending above and below the instrumented levels and extensive dissection of the posterior musculatures to expose the necessary anatomic landmarks for screw insertion and rod placement; this extensive muscle dissection and prolonged retraction can result in tissue ischemia, muscle denervation and atrophy with increased risk of blood loss, infection, increased postoperative pain and delayed recovery.<sup>8,10</sup> Therefore, there has been enthusiasm for developing minimally invasive technique for spinal fixation.

Minimally invasive percutaneous spinal fixation surgery utilize technology to access the spine through smaller incisions; as a result, this technology requires less muscle dissection and thereby minimizes tissue injury, blood loss, risk of infection and chronic pain which consequently leads to shorter hospitalization, earlier rehabilitation and faster recovery.<sup>15</sup>

## Patients and Methods

Retrospective review of patients with acute thoracolumbar fractures without neurological deficit treated with percutaneous pedicle screw fixation in Benha University Hospital in Egypt and Alhayat National Hospital in Kingdom of Saudi Arabia from January 2011 to January 2015 was performed. Baseline data include patient demographics, operative data, mechanism of injury, fracture level and kyphotic angle. Pain was assessed using visual analogue scale and radiological outcome was assessed as the amount of kyphotic angle correction; the kyphotic angle is the angle between the superior endplate of the upper adjacent vertebra and the inferior endplate of the lower adjacent vertebra of the fracture site. All patients had CT spine before and after surgery. Follow up ranged between 3 and 12 months (mean 6 months).

### Surgical Technique:

**General anesthesia and skin marking:** It is important to check that adequate AP and lateral fluoroscopy images of the vertebrae can be obtained before preparing and draping the patient. After induction of general anesthesia and endotracheal intubation, the patient was positioned in a prone position on a radio-translucent table. Using the C-arm, the midline and pedicle line was marked on the skin and a small skin incision was placed about 1 cm lateral to the pedicle line.

**Pedicle identification:** Under fluoroscopic guidance, the tip of the Jamshidi needle was placed over the lateral margin of the pedicle, the needle shaft then aligned parallel to the end plate with lateral to medial trajectory 15 degrees. Then the needle was tapped gently to set the needle tip in to the pedicle, and then the needle position was advanced 10 to 15 mm deeper into the vertebral body. The trochar was removed from the Jamshidi needle and the guide wire was inserted through the needle. The same procedure was repeated for all pedicles in the surgical construct (Figure 1 and 2).

**Pedicle tapping:** Once the guidewire was inserted, the needle was removed. The fascia and muscles were dilated to allow for screw placement using three dilators. The first two dilators were removed, leaving the third dilator to serve as a tissue protection sleeve during the tapping step. The pedicle was tapped by placing the tap over the guide wire and through the third dilation sleeve guided by the C-arm image.

**Screw placement:** After tapping, the dilator was removed and a cannulated pedicle screw was placed over the guidewire at each level and threaded into the pedicle then the guidewires were removed (Figure 3).

**Rod placement:** Then the proper rod length was measured by a rod measuring device. The rod inserter was attached to the screw extenders and the rod was inserted percutaneously through a small incision and passed through the screw head extenders into the screw crowns then the screw caps were inserted into each screw to capture the rod. Distraction of the construct was performed if needed followed by final tightening of the construct and skin closure.

### **Post-operative Care:**

Dorsolumbar support was advised and patients were encouraged to get out of bed within 24 hours after surgery. Postoperative X-ray and CT scan were performed routinely to evaluate the accuracy of screw placement.

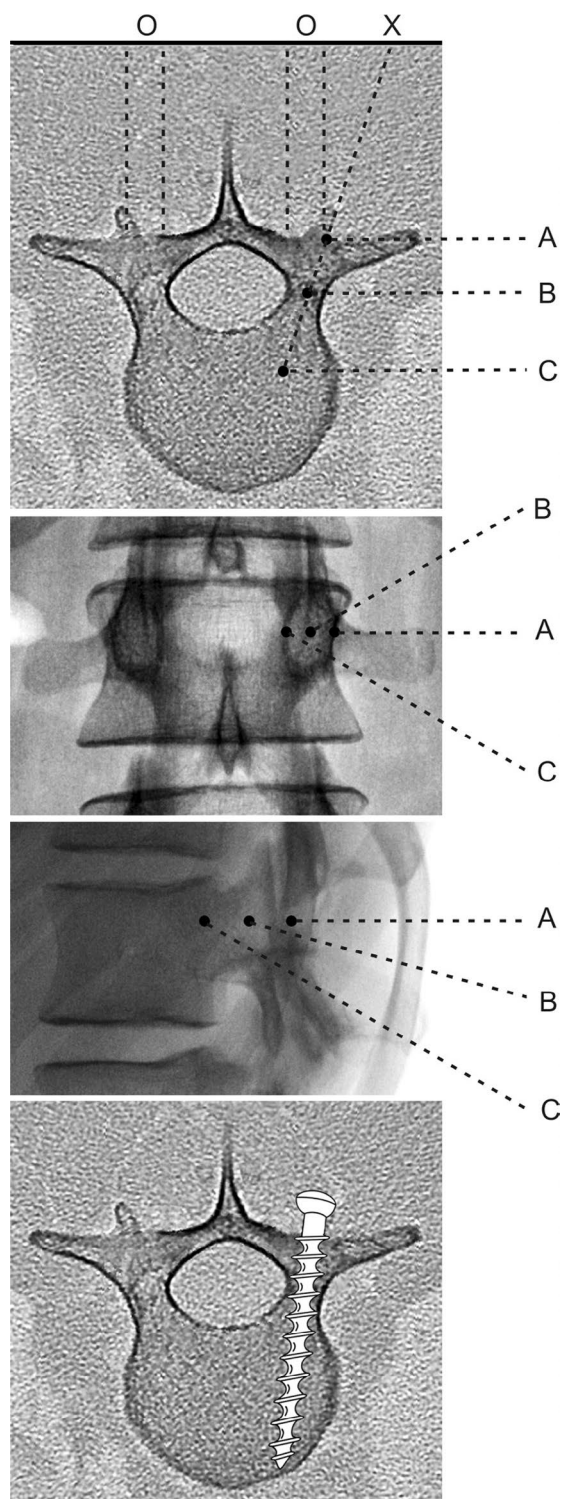
## **Results**

Seventeen patients with thoracolumbar fracture were included in this study, 14 patients were male and 3 were female, the mean age of the patients was 41 years (range 18 to 58). The mode of fracture was fall from height in 13 patients (76.5%) and motor car accidents in 4 patients (23.5%). Fifteen patients (88.2%) had single level fractures, one patient (5.9%) had a double level fracture and another patient (5.9%) had a three level fracture. Ten cases had fracture at L1 and 3 cases had fracture in T12. Short segment percutaneous fixation of one vertebra below and above the fractured level was done in 10 patients. While long segment percutaneous fixation of two or more vertebra below and above the fractured level was done in 7 patients (Figure 4). An additional pedicle screw was placed at the fractured level in 5 patients.

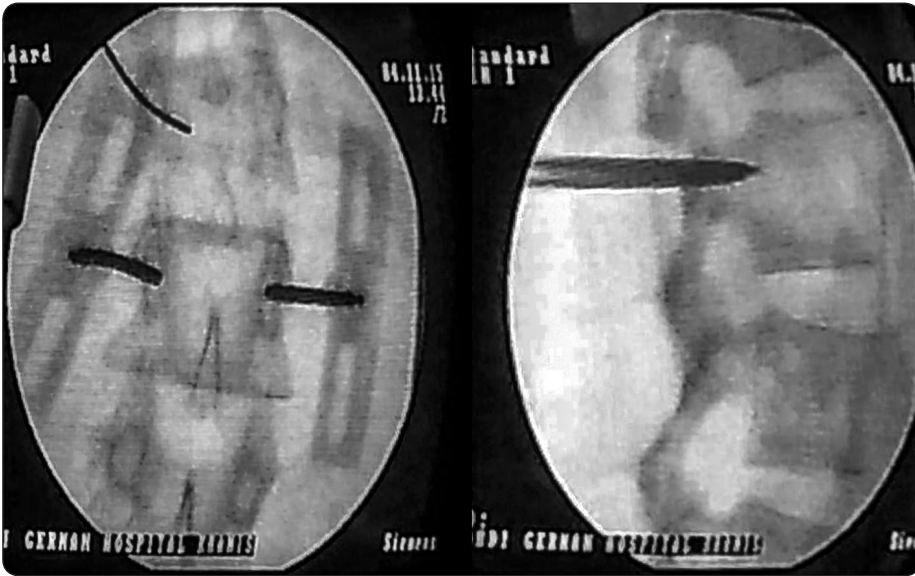
The mean operative time was 110 minute (range 80 to 250 minute). The average hospital stay was 3 days (average 1 to 5 days). The mean kyphotic angle improved from 24 degree before surgery to 7 degree after surgery. The mean VAS improved from 8.4 preoperatively to 1.8 postoperatively (Table 1). Total number of pedicle screws placed was 114. Eight (7%) pedicle breaches less than 2 mm were seen in the postoperative CT scan with no neurological complications.

**Table 1.** Patients characteristics, kyphotic angle and VAS.

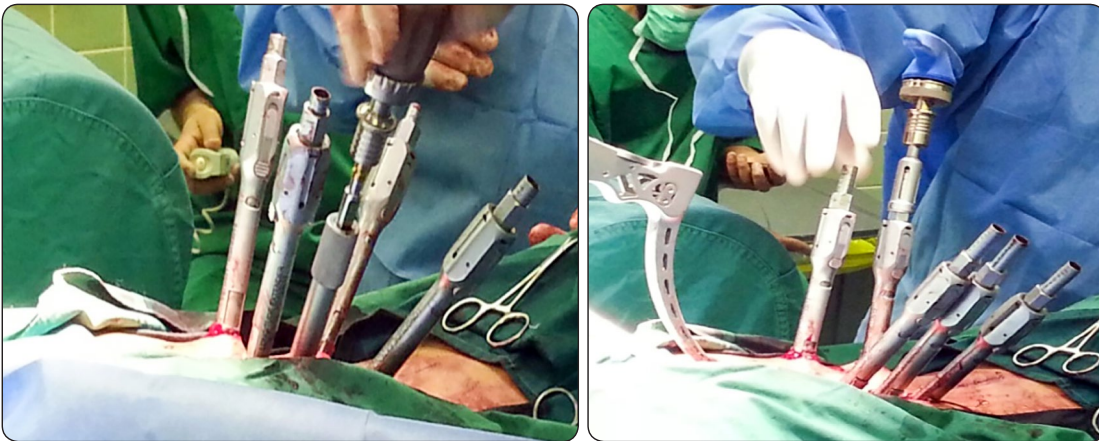
Variables		No. (%)
Age		41
Gender	Male	14(82.4%)
	Female	3(17.6%)
Mechanism of injury	Fall from height	13(76.5%)
	Road traffic accident	4(23.5%)
Vertebral fracture	Single level	15(88.2%)
	Two level	1(5.9%)
	Three level	1(5.9%)
Fracture level	T11	2(10%)
	T12	3(15%)
	L1	10(50%)
	L2	2(10%)
	L3	1(5%)
	L4	1(5%)
Kyphotic angle	Preoperative	24
	Post operative	7
VAS	Preoperative	8.4
	Postoperative	1.8



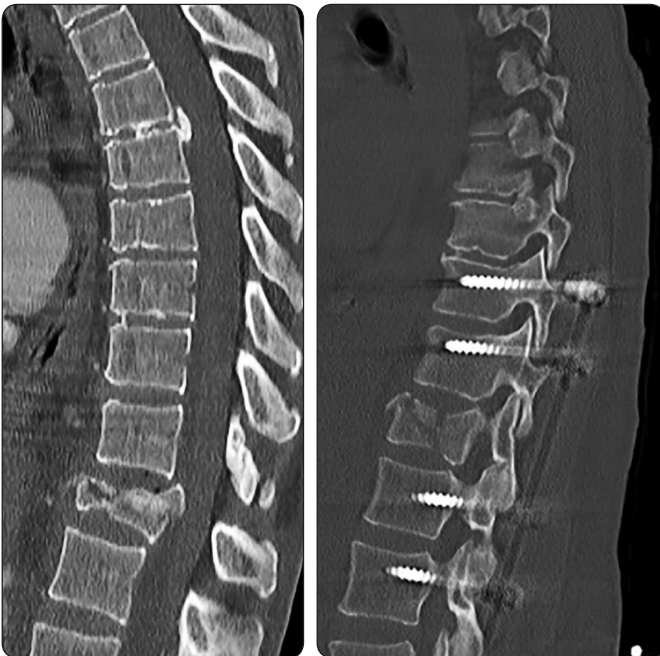**Figure 1.**<sup>5</sup> Diagrams illustrating the anatomical principles of percutaneous pedicle screw insertion: axial, AB and lateral vertebral view: The needle tip is inserted into the lateral margin of the pedicle (point A). As the needle advances toward the base of the pedicle on the lateral image, it should approach the pedicle center on the AB image (point B). When the needle exceeds the posterior wall of the vertebra on the lateral image, the tip of the needle has to remain lateral to the medial pedicle wall on the AB image (point C).



**Figure 2.**  
Anterior-posterior and lateral x-rays demonstrating localization of the pedicle using intra-operative fluoroscopy.



**Figure 3.**  
Intra-operative image during screw insertion and rod placement.



**Figure 4.**  
CT scan before and after percutaneous fixation of T12 fracture.

## Discussion

In last decade, percutaneous pedicle screw fixation systems have become more frequently used as they allow the surgeon to achieve the same goals as standard open surgery but in a less invasive manner through a stab incision and without the need for excessive muscle dissection.<sup>18</sup> They provide rigid fixation of thoracolumbar fracture by engaging all three columns of the spine.<sup>3</sup>

Recently Mc Anany et al,<sup>14</sup> did a meta-analysis to compare between traditional open approach and percutaneous approach for fixation of thoracolumbar fractures, he conclude that, the two groups have nearly same outcome in terms of improvement of pain and kyphotic angle but the percutaneous group had significant decrease in blood loss and operative time, another study reported better functional outcome in the percutaneous group.<sup>8</sup>

In Yang et al,<sup>20</sup> series of 21 patients with thoracolumbar burst fracture treated by percutaneous fixation, the mean age was 39.6, the most common cause of injury was fall from height followed by road traffic accident, 85.7% of patient had single level fracture, 9% had double level fracture and 4.5% had three level fractures. Similarly in our series, mean age was 41 and fall from height was the main cause of fracture; 88.2% of patients had single level fracture while 5.9 % had double level fractures and 5.9 % had three level fractures.

Many studies have reported marked improvement of pain after percutaneous fixation of thoracolumbar fractures.<sup>10,20</sup> Lee et al,<sup>10</sup> reported reduction of mean VAS score from 8 preoperative to 2.9 postoperative. In our study, mean VAS score improved from 8.4 preoperative to 1.8 after surgery. One of the mean goals of percutaneous fixation is correction of kyphosis. Yang et al,<sup>20</sup> reported improvement of mean kyphotic angle from 17.1 degrees preoperatively to 11 degrees postoperatively and Lee et al,<sup>9</sup> reported improvement from 28 degrees

preoperatively to 9.3 degrees postoperatively with achievement of 19 degree of kyphosis correction. Consistent with those previous studies, in our series the mean kyphotic angle was reduced from 24 degree preoperative to 7 degree after surgery.

In Cappuccio et al,<sup>2</sup> study, the mean operative time was 116 minutes (range 35-240 minutes) and was directly related to the number of stabilized levels, mean operative time decreased to 106 minutes with short segment fixation by 4 screws, and increased to 171 minutes with long segment fixation by 8 screws. Blood losses were not assessable intra-operatively. Patients were encouraged to get out of bed in postoperative day 2 and postoperative hospital stay was 5 days. In our study the mean operative time was 110 minute with longer operative time occurring in long segment fixation surgery. Estimated intra-operative blood loss was 50 to 100ml. Patients were mobilized with Dorsolumbar support on first postoperative day.

Routine use of percutaneous pedicle screws has not been free of complications. The incidence of screw misplacement ranges from 4.7% to 23%.<sup>16,21</sup> Smith et al,<sup>19</sup> reported a pedicle breach rate of 6.2%. In our study the incidence of pedicle breach was 7% with no significant neurological complications.

## Conclusion

Fluoroscopic guided percutaneous pedicle screw fixation can provide a safe and effective treatment for acute thoracolumbar fractures with significant reduction in blood loss, postoperative pain and hospital stay.

## References

1. Calenoff L, Chessare JW, Rogers LF, Toerge JO, Rosen JS: Multiple level spinal injuries: importance of early recognition. American Journal of Roentgenology 130(4):665-674, 1978

2. Cappuccio M, Amendola L, Paderni S, Bosco G, Scimeca G, Mirabile L, et al: Complications in minimally invasive percutaneous fixation of thoracic and lumbar spine fractures. *Orthopedics* 36(6):e729-734, 2013
3. Gaines RW: The use of pedicle-screw internal fixation for the operative treatment of spinal disorders. *J Bone Joint Surg* 82:1458–1476, 2000
4. Gertzbein SD: Multicenter Spine Fracture Study. *Spine* 17(5):528-540, 1992
5. Heintel TM, Berglehner A, Meffert R: Accuracy of percutaneous pedicle screws for thoracic and lumbar spine fractures: a prospective trial. *Eur Spine J* 22:495–502, 2013
6. Hitchon PW, Torner JC, Haddad SF, Follett KA: Management options in thoracolumbar burst fractures. *Surg Neurol* 49: 619-626, 1998
7. Hsu JM, Joseph T, Ellis AM: Thoracolumbar fracture in blunt trauma patients: guidelines for diagnosis and imaging. *Injury* 34:426-433, 2003
8. Jiang XZ, Tian W, Liu B, Li Q, Zhang GL, Hu L, et al: Comparison of a paraspinous approach with a percutaneous approach in the treatment of thoracolumbar burst fractures with posterior ligamentous complex injury: a prospective randomized controlled trial. *J Int Med Res* 40(4):1343–1356, 2012
9. Lee GW, Jang SJ, Kim JD, Son JH, Jang JH: The efficacy of percutaneous long-segmental posterior fixation of unstable thoracolumbar fracture with partial neurologic deficit. *Asian spine journal* 7(2):81-90, 2013
10. Lee JK, Jang JW, Kim TW, Kim TS, Kim SH, Moon SJ: Percutaneous short-segment pedicle screw placement without fusion in the treatment of thoracolumbar burst fractures: is it effective? Comparative study with open short-segment pedicle screw fixation with posterolateral fusion. *Acta Neurochir (Wien)* 155(12): 2305–2312, 2013
11. Lowery GL, Kulkarni SS: Posterior percutaneous spine instrumentation. *Eur Spine J* 9:S126-S130, 2000
12. MAGERL F: Stabilization of the lower thoracic and lumbar spine with external fixation. *Clin. Orthop* 189:125-41, 1984
13. Mathews HH, Long BH: Endoscopy assisted percutaneous anterior interbody fusion with subcutaneous superfascial internal fixation: evolution of technique and surgical considerations. *Orthop Int Ed* 3:496-500, 1995
14. McAnany SJ, Overley SC, Kim JS, Baird EO, Qureshi SA, Anderson PA: Open versus minimally invasive fixation techniques for thoracolumbar trauma: a meta-analysis. *Global spine journal* 6:186-194, 2016
15. Mobbs RJ, Sivabalan P, Li J: Technique, challenges and indications for percutaneous pedicle screw fixation. *Journal of Clinical Neuroscience* 18:741-749, 2011
16. Nakashima H, Sato K, Ando T, Inoh H, Nakamura H: Comparison of the percutaneous screw placement precision of isocentric C-arm 3-dimensional fluoroscopy-navigated pedicle screw implantation and conventional fluoroscopy method with minimally invasive surgery. *J Spinal Disord Tech* 22:468–472.,2009
17. Roy-Camille R, Roy-Camille M, Saillant G, Demeulenaere C, Lelièvre JF: Surgical therapeutic indications in vertebral injuries with spinal cord syndrome or cauda equina syndrome. *Nouv Presse Med* 1:2165-2168, 1972
18. Sahoo PK: Percutaneous pedicle screw and rod insertion for fracture of the lumbar spine. *Indian J Neurotrauma* 2:143-8, 2005
19. Smith ZA, Sugimoto K, Lawton CD, Fessler RG: Incidence of lumbar spine pedicle breach after percutaneous screw fixation:

- a radiographic evaluation of 601 screws in 151 patients. J Spinal Disord Tech 27:358–363, 2014
20. Yang WE, Ng ZX, Koh KM, Low SW, Lwin S, Choy KS, et al: Percutaneous pedicle screw fixation for thoracolumbar burst fracture: a Singapore experience. Singapore medical journal 53:577-581, 2012
21. Yoshida G, Sato K, Kanemura T, Iwase T, Togawa D, Matsuyama Y: Accuracy of Percutaneous Lumbosacral Pedicle Screw Placement Using the Oblique Fluoroscopic View Based on Computed Tomography Evaluations. Asian Spine J 10:630-638, 2016

Address reprint  
request to:

**Abdelaal Abdelbaky, MD.**  
Neurosurgery Department, Benha University, Egypt  
Email: abdelaalmd@gmail.com

## الملخص العربي

### تثبيت الفقرات بالتدخلات المحدودة من خلال الجلد لكسور الصدرية القطنية الحادة

**المقدمة:** لقد أصبح من الشائع استخدام تقنية تثبيت كسور الفقرات عن طريق فتحة صغيرة خلال الجلد وذلك لأنها أتاحت للجراح تحقيق نفس نتائج الجراحة التقليدية لتثبيت العمود الفقري ولكن عن طريق التدخل المحدود وتتميز هذه التقنية الحديثة لتثبيت الفقرات بإمكانية زرع مسامير وأعمدة عن طريق فتحة صغيرة بالجلد وتتميز أيضا بانها لا تستدعي تشريح أنسجة العضلات.

**الهدف:** الهدف من هذه الدراسة هو تقييم نتائج تثبيت كسور الفقرات الصدرية والقطنية باستخدام مسامير يتم زرعها عن طريق فتحة صغيرة بالجلد.

**تصميم الدراسة:** دراسة بأثر رجعي.

**طريقة البحث:** تم مراجعة سجلات المرضى الذين كانوا يعانون من كسور بالفقرات الصدرية والقطنية بدون مضاعفات عصبية والذين تم علاجهم باستخدام تقنية تثبيت الفقرات عن طريق فتحة صغيرة بالجلد في الفترة ما بين شهر يناير ٢٠١١ وشهر ديسمبر ٢٠١٥ وقد اشتملت البيانات الأساسية على بيانات المرضى، بيانات العمليات، طريقة الإصابة، مستوى الكسر وزاوية الحدب. تم تقييم الألم باستخدام مقياس التناظرية البصرية وتقييم درجة الانحناء في الأشعة عن طريق قياس زاوية الحدب.

**النتائج:** تضمنت الدراسة ١٧ مريضا كانوا يعانون من كسور بالفقرات الصدرية والقطنية. ١٤ من الذكور و٣ من الإناث وكان متوسط العمر ٤١ عاما. كان السقوط من أعلي هو سبب إصابة ١٣ مريض بكسور الفقرات وكانت حوادث السيارات سبب إصابة ٤ آخرين من المرضى. وقد بلغ متوسط وقت الجراحة ١١٠ دقيقة و متوسط فترة الإقامة بالمستشفى ٣ أيام وقد تحسن متوسط زاوية الحدب من ٢٤ درجة قبل الجراحة إلى ٧ درجات بعد الجراحة. وقد تحسن متوسط مقياس درجة الألم من ٨,٤ قبل الجراحة إلى ١,٨ بعد الجراحة.

**الاستنتاج:** إن تقنية تثبيت الفقرات باستخدام مسامير يتم زرعها خلال فتح صغيرة بالجلد وتحت الأشعة طريقة آمنة وفعالة لعلاج كسور الفقرات الصدرية والقطنية وتتميز بأقلية كمية الدم المفقود أثناء الجراحة وقصر مدة الإقامة بالمستشفى ودرجة آلام بسيطة بعد الجراحة.