

# Full-Endoscopic Soft Tissue Approach for Lumbar Disc Herniation

Walid K Abouzeid,<sup>1</sup> MD, Tamer Hassan,<sup>2</sup> MD, PhD, Hesham Abo Rahma,<sup>3</sup> MD, Ahmed Azab,<sup>3</sup> MD.

Neurosurgery Departments, Sohag University Hospital, Sohag,<sup>1</sup> Alexandria University Hospital, Alexandria,<sup>2</sup> Menufeya University Hospital, Menufeya,<sup>3</sup> Egypt.

## Abstract

**Background Data:** Open lumbar microdiscectomy has been considered the gold standard in the management of lumbar disc herniation (LDH) because of its favorable outcomes in long-term follow up. Nowadays, minimally invasive discectomy is gaining recognition due to its advantages. The advantages endoscopic lumbar discectomy includes clear visualization, less injury to the paraspinal muscle, protection of spinal stiffness and dynamic structure better cosmetic effect, and less postoperative symptoms and open surgery-related complications with subsequent earlier return to work.

**Purpose:** This study was conducted to evaluate the efficacy of transforaminal and interlaminar endoscopic lumbar discectomy in the treatment of lumbar disc prolapse.

**Study Design:** A prospective descriptive case series study.

**Patients and Methods:** A prospective descriptive case series study was carried out on 42 patients who had lumbar disc herniation not responding to medical treatment for 6 months. Patients included from those attending the neurosurgical department of Alexandria University, Sohag University Hospital, and Menofya University; in the period from January 2012 to February 2015. All patients underwent either transforaminal or interlaminar endoscopic lumbar discectomy.

**Results:** All patients had significant improvement in VAS score. According to Mac Nab's criteria; 79% of patients have excellent results and 11% have good results; thus giving about 90% satisfactory outcome. Out of the 25 patients

Received at:

January 21<sup>st</sup>, 2016

Accepted at:

March 12<sup>th</sup>, 2016

undergone interlaminar approach, 24 (96%) had completed the planned operative procedure. On the other hand, out of the 17 patients who undergone transforaminal approach; only 12 patients (70.6%) had completed the planned operative procedure.

**Conclusion:** Pure endoscopic discectomy is an effective surgical method for treatment of lumbar disc prolapse. (2016ESJ104)

**Keywords:** endoscopic, lumbar disc, Interlaminar, transforaminal

## Introduction

The traditional open lumbar microdiscectomy is the standard treatment of lumbar disc herniation (LDH) till now, but it has the disadvantage that the surgeon should remove more or less one third of the facet joint and also the ligament flavum in order to fully expose the nerve root and herniated disc, such large trauma may lead to bleeding, adhesions, instability, and epidural scar that may also cause long postoperative hospital stay with slow recovery and return to work.<sup>23,31</sup> These iatrogenic complications can now be greatly reduced using the full endoscopic techniques,<sup>6,17-20</sup> The full-endoscopic lumbar discectomy was first described by Yeung in 1999 for the treatment of LDH.<sup>32</sup>

Endoscopic discectomy technique, has been introduced since the '80s, but shows much more interest in the last years, with progressive increase in the trend to replace open surgery with endoscopic surgery. The concept behind it is to provide a minimally invasive approach to the lumbar spine when treating disc herniations. Ideally, the goal of the developing endoscopic disc surgery is getting as much as possible similar results obtained using standard microdiscectomy, not only just pain relief as in nerve root or peridural injections, but also providing optimum nerve decompression. At the same time, the endoscopic surgery was developed with the aim of avoiding discomfort and complications related with open techniques.<sup>18</sup>

Nowadays, minimally invasive discectomy is gaining recognition due to its advantages.<sup>5</sup> The most common endoscopic minimally invasive discectomy procedures are the transforaminal (TF) and interlaminar (IL) approaches.<sup>10,15,29</sup> Due to limited microscopic operation space, it is mandatory to have a correctly planned working channel, to get a good access to the disc space as much as possible. As a result, a totally exposed intervertebral disc can be seen within a very narrow space.<sup>10</sup>

The standard transforaminal endoscopic surgery was first introduced by Yeung et al,<sup>31</sup> in 2002. A new study done by Sanusi et al,<sup>21</sup> showed that endoscopic discectomy using lateral approach is a better option for the treatment of symptomatic LDH, as regards lower risk of complications when compared with ordinary microdiscectomy.

The posterolateral transforaminal endoscopic discectomy is a popular endoscopic technique<sup>1,7,12,23,26</sup>, but it has many disadvantages, including complicated perforation techniques, overdose of X-rays exposure, insufficient treatment of disc protrusion at L5-S1 level and finally the controversy regarding its efficiency in dealing with discs located mainly inside the spinal canal.<sup>26,31</sup> Ruetten et al,<sup>17</sup> developed another technique using interlaminar approach into the canal. This preserves the classical posterior pathway and has the advantage of being easy to perform, proved to be sufficient for treatment of L5-S1 by postero-lateral transforaminal approach. With the development of many new techniques, the full-endoscopic spinal disc

surgery has become good and important option in the management of intervertebral LDH, and one of the most important concepts in terms of endoscopic spine surgical approaches is understanding the pathologic neuroforaminal anatomy in terms of both disc pathology and facet changes.<sup>13,26</sup>

In this study, we report our local experience regarding durability, indication, approaches, and surgical outcomes of percutaneous endoscopic lumbar discectomy.

## Patients and Methods

A prospective descriptive case series study that was carried out on 42 patients who had lumbar disc herniation not responding to medical treatment for 6 months. Patients included from those attending the neurosurgical department of Alexandria, Sohag and Menofya University Hospitals; in the period from January 2012 to February 2015. All patients were de novo cases with extra or intraforaminal disc herniations with no history of previous operations, or recurrent disc prolapse were enrolled in this study. Medically unfit patients, recurrent disc, previous spine interventions, sacroiliac joint pain or severe osteoporotic patients were excluded from this study.

As with conventional procedures, patients must be informed about their disease, its possible long-term course and consequences, as well as all known side effects, complications and therapeutic possibilities, despite the minimal invasiveness and the resultant advantages for the surgical procedure. In addition, it must be emphasized that therapy of a possible complication may require a change of the surgical strategy to an open procedure

All patients were subjected to full history taking, neurological assessment, physical examination, laboratory investigation, and

radiological examination (lumbosacral CT, MRI, X-ray) and were operated in the prone position (Figure 1).

### Surgical Procedures:

#### **(A) Transforaminal PELD:** (Figure 2)

This technique was performed in 17 patients. Indications were; disc prolapse at L4/5 or L3/4 levels with no caudal or cephalic migration, and disc prolapse at L5/S1 with the posterior superior iliac spine is low in plain X-ray (AP view). Contraindications; were marked spinal canal stenosis, a full-endoscopic interlaminar procedure access is indicated in such cases.

The transforaminal percutaneous endoscopic lumbar discectomy (TF-PELD) procedure was performed under general anesthesia in the prone position on a standard frame, taking into account not to cause abdominal compression that might exaggerate venous bleeding. A sterile drape-covered C-arm is necessary throughout the whole procedure (Figure 3). Skin entry point is localized empirically between 10 and 12 cm from the midline; further lateralization might be required in obese patients. Continuous fluoroscopic guidance was used to introduce the 18-gauge needle and to check its correct position in both AP and lateral views. The aim of the needle is the wedge-shaped working zone, or Kambin's triangle<sup>33</sup> which is an extracanal area defined above by the exiting root and ganglion, below by the disc itself, and medially by the lateral border of the facet joint (Figure 4).

In AP projections, the pedicle is preferably divided into three pedicular lines: lateral, middle and medial.<sup>7</sup> The skin entry point was commonly higher to the iliac crest and is around 10–13 cm from the midline. After entry point infiltration with local anesthesia, a spinal needle (size: 18-gauge) was introduced, under fluoroscopic guide. The target point of the introduced spinal

needle was the medial pedicular line and posterior vertebral line on the AP image and the lateral image; respectively. When there was a central disc herniation, the spinal needle was targeted more medially on AP image.

The best positioning of the needle tip is at the mid pedicular line on AP projections and inferior foraminal margin on lateral projection, parallel to the superior end plate of the inferior vertebral body. At this point, needle was replaced with a wire; then skin incision was made around it and the wire was then used as a guide to introduce the cannula. Cannula is then maintained against the disc fibers and continuous washing of saline through the cannula is used to continuously clean the surgical view. After insertion of the endoscope, dedicated forceps was used to perform discectomy or fragment removal.

For far lateral herniated disc the cannula can be directly inserted on it and can be easily removed under local anesthesia there is no need to insert the cannula through the interforaminal space. Far lateral HNP can be removed at any level through posterolateral approach

**(B) Interlaminar Approach:** (Figures 5, 6)

This technique was performed for 25 patients. Indication: were disc prolapse at L4/5 or L3/4 levels with caudal or cephalic migration, and disc prolapse at L5/S1 with the posterior superior iliac spine is high in plain X-ray (AP view). Contraindication: compressive intra- or extraforaminal pathologies: a full-endoscopic trans- or extraforaminal procedure with posterolateral to extreme lateral access is indicated in such cases, and pronounced bony shift in the interlaminar window to the cranial levels: due to the required demanding bone resection with currently available instruments, a conventional procedure should be considered in transforaminal technically inoperable pathologies.

The technique of Endoscopic access is done under fluoroscopic AP guidance; skin incision is made as medial as possible in the cranio-caudal midline of the interlaminar. A dilator was inserted toward the lateral margin of the interlaminar window towards the ligamentum flavum. Dilator should be oblique from the midline direction, in order to permit endoscopic access under the facet joint. The subsequent part of the operation was performed under lateral fluoroscopic guide. An operating sheath was then inserted with oblique opening directed toward the ligamentum flavum. Direction in lateral view was pointed towards the disc space with the instruments end just at the facet joint. Dilator was then removed and the endoscope was inserted. The subsequent procedure was achieved under visual control and continuous irrigation. The flavum ligament is clearly exposed with the aid of radiofrequency bipolar and forceps. A lateral incision is made, approximately 5mm long, up to the facet joint. With lateral fluoroscopic guidance, it is easy to have both cranio-caudal and medial to lateral orientation reaching the facet joint and touching the bone with instruments and dissector. Bone of both the ascending facet and superior lamina can be partially resected, hence obtaining a wide exposure of the descending facet. Opening was enlarged using endoscopic bone punch. After entering the spinal canal, the floating epidural fat is clearly visible; neural structures are exposed. After clear recognition of the passing nerve root and dural sac, the operating sheath with oblique opening is used as a second instrument to manipulate the neural structures gently so as to expose and remove the herniated disc material. In order to evade neural damage, principally in the cranial segment, it is must not to laterally displace the passing root for a long time. Traction should be performed

on intermittent basis only after having clearly achieved medial to lateral orientation inside the spinal canal. If gentle lateral traction cannot be achieved, drilling of the descending facet can be considered so as to gain additional space and achieve an indirect decompression. At the end of the procedure the passing nerve root should be seen clearly decompressed with the fatty greasing tissue moving or floating around the nervous structures. The passing nerve root may be gently retracted medially with a blunt dissector; just make sure all prolapsed disc fragments have been removed.

Visual analogue scale (VAS) score of pain and Mac Nab's score were used to evaluate every patient preoperatively, postoperatively and after 2 weeks of postoperative follow up period. Hospital stay, intraoperative, and postoperative complication were all assessed. Follow-up examinations were conducted at day 1 and at 1 month mainly, and at 3rd month, and at 6<sup>th</sup> month if possible.

#### **Statistical Analysis:**

Data were analyzed using the Microsoft Excel 2016 software (Microsoft corporation, Chicago, USA, 2016), and the IBM-SPSS software, version 24 (IBM corporation, Chicago, USA, 2016). Qualitative data were expressed as frequencies and percentages, while quantitative data were expressed as means, medians and standard deviations. Pearson Chi square was used to compare percentages of qualitative variables and paired t test was used to compare means of VAS before and after the operations.

## **Results**

Among 42 patients enrolled in our study, there were slight female predominance (57%), age ranged from 25-57 years old with a mean 38 years old. As regards the site of the sciatica, no site predominance was found; right sided

sciatica was seen in 22 patients (52.3%). No any patients lost during scheduled follow up.

The operating time in the transforaminal group seems to be slightly shorter than interlaminar group, but statistically insignificant, (P=0.077) as it was 25-40 minutes, with a mean of 35 minutes, while the operating time in the interlaminar approach was 30-55 minutes, with a mean 45 minutes. No measurable blood loss in the both-groups because the mean intra- and postoperative blood loss was nearly (60 mm). Out of the total 25 patients undergone interlaminar approach, 24 (96%) had been followed on the planned operative procedure (Figure 7,8), while one case (4%) was shifted to microscopic discectomy due to large L4/L5 fragment. On the other hand, out of the 17 patients who underwent transforaminal approach; only 12 patients (70.6%) had been followed on the planned operative procedure (Figure 9), while 5 patients (29.4%) were shifted to microscopic discectomy due to adhesions or epidural scars caused by old fragments. The difference between the two approaches was statistically significant (P=0.020) in favor of the interlaminar approach (Table 2).

There were no serious complications in either group, such as dural/nerve injury or cauda equine syndrome. Two patients (8.3%) developed a transient postoperative dysesthesia in the interlaminar group which improved, and two patients (16.6%) in the transforaminal group developed complications (1 patient had postoperative bleeding, 1 patient delayed wound-healing). There were no other complications like spondylodiscitis or thrombosis. Overall, the complication rate was significantly elevated in the transforaminal group (P=0.019).

All patients (100%) had significant improvement in VAS score. There was dramatic



decrease in VAS of sciatica immediately after operation, from  $8.20 \pm 0.81$  preoperatively to  $1.57 \pm 1.57$  immediately post operatively ( $P < 0.001$ ). Two weeks after operation, VAS decreased to  $0.33 \pm 1.14$  ( $P < 0.001$ ) (Table 1). According to Mac Nab's criteria; 79% of patients gave excellent results and 11% gave good results;

thus giving about 90% satisfactory outcome and 10% unsatisfactory outcome.

Hospital stay had irrelevant significance in both groups, which ranged from 2-7 days with a mean of 3 days. Patients in both groups regained their original daily activities within one month postoperatively.

**Table 1.** Reduction of VAS after Surgery

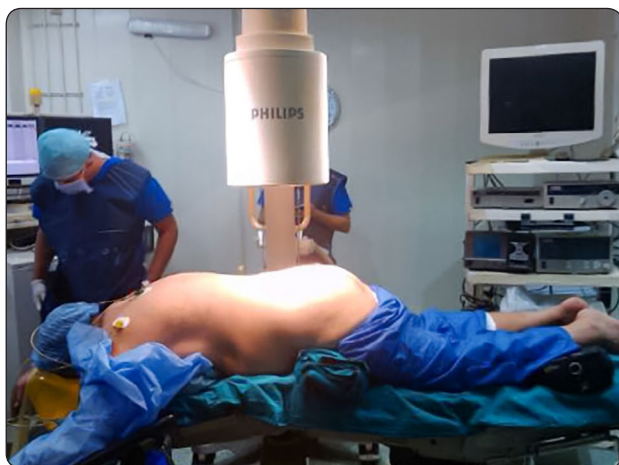Time	VAS	P value
Preoperative	$8.20 \pm 0.81$	-
Immediately postoperative	$1.57 \pm 1.57$	$< 0.001$
Two weeks postoperative	$0.33 \pm 1.14$	$< 0.001$

Paired t test was used in these statistics

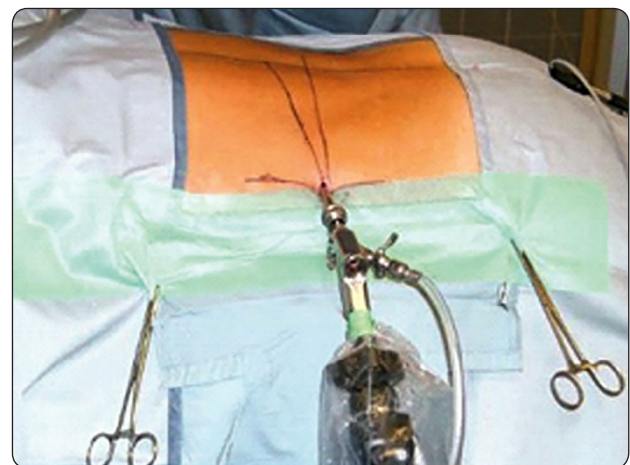**Table 2.** Surgical Procedure

Group	Planned procedure	Shift to microdiscectomy	Cause of shift	P value
Interlaminar approach	24(96%)	1(4%)	large L4/L5 fragment	0.021 (S)
Transforaminal approach	12(70.6%)	5(29.4%)	Old fragments adhesions or epidural scars	

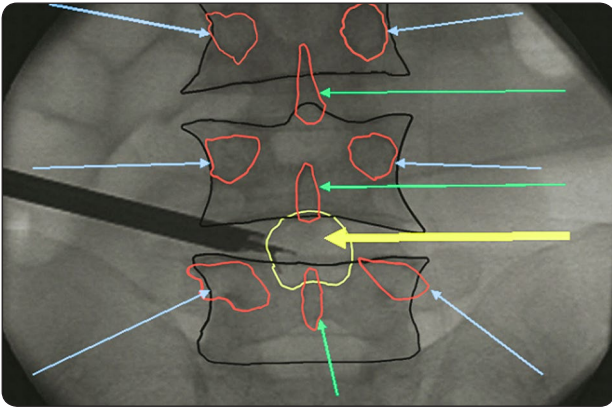
Pearson Chi square was used in this table



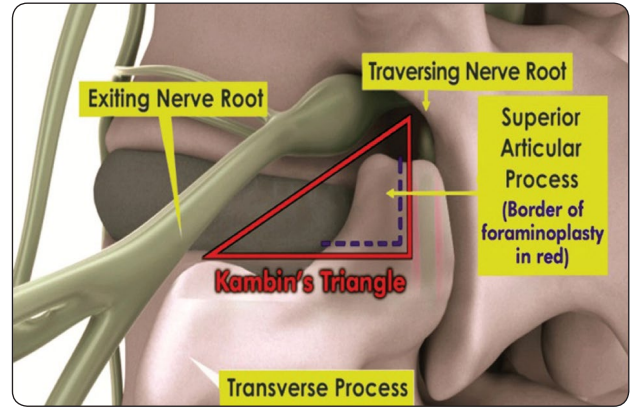
**Figure 1.** Patient position



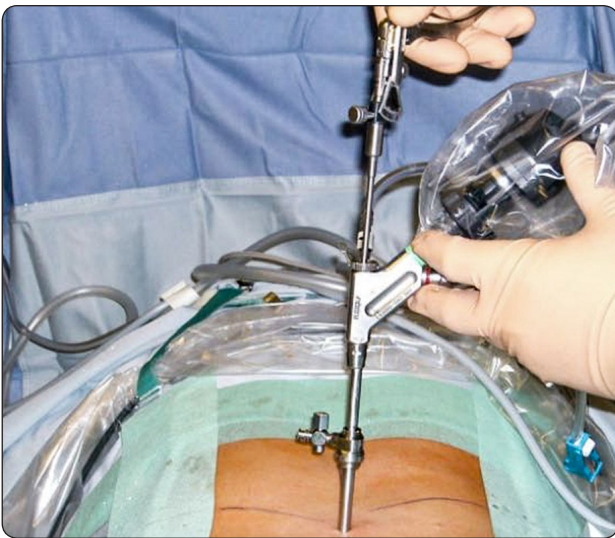
**Figure 2.** Transforaminal approach



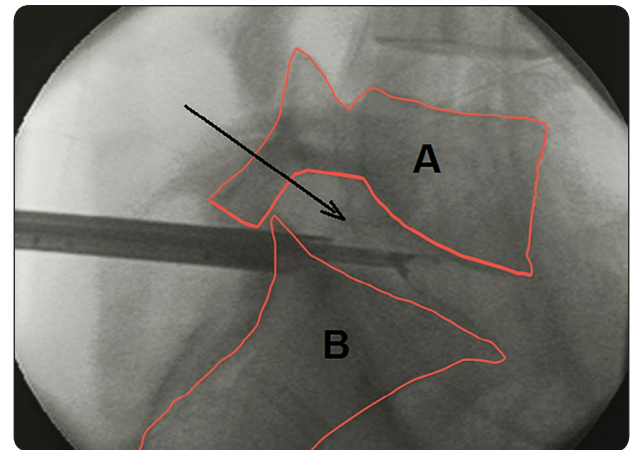
**Figure 3.** Intraoperative C-arm image of transforaminal operation. blue arrows: pedicles, green rows: spinous processes. yellow arrow showing intervention site.



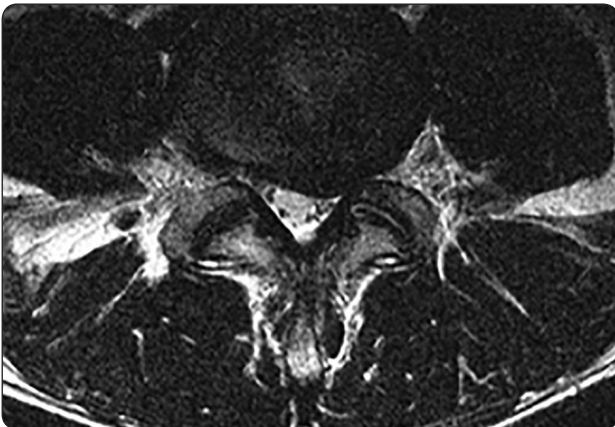
**Figure 4.** Kambin's Triangle (Yeung et al., 2014)<sup>33</sup>



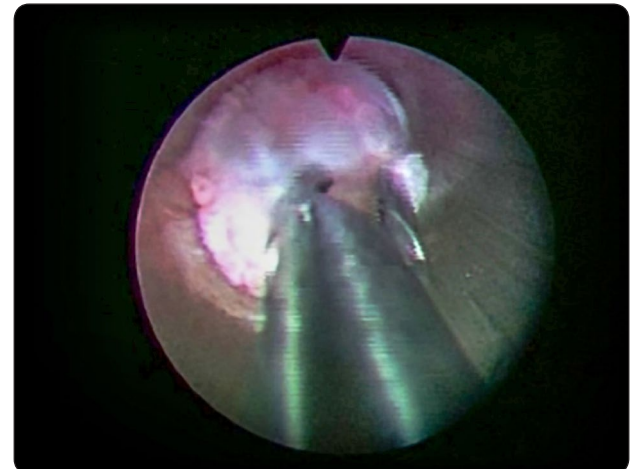
**Figure 5.** Interlaminar Approach



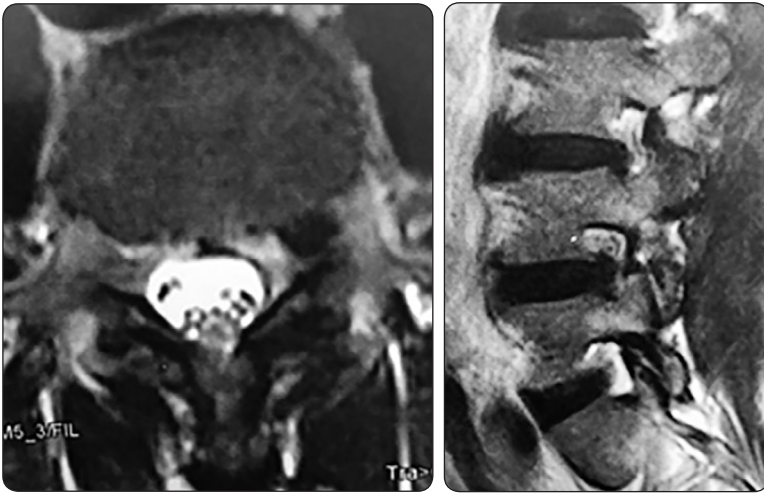
**Figure 6.** Intraoperative C-arm image of the interlaminar operation (a: I5, b: sacrum, arrow: intervention site).



**Figure 7.** Showing example of one of our patient with axial T2 MRI of Left L4/5 disc submitted to interlaminar endoscopic discectomy.



**Figure 8.** Showing Endoscopic view with disc forceps holding the disc fragment.



**Figure 9.** Showing example of another one of our patient with axial and sagittal T2 MRI of Left foraminal L4/5 disc submitted to transforaminal endoscopic discectomy.

## Discussion

First series of endoscopic discectomy are reported from the late 1980s. Kambinet al,<sup>8</sup> reported initial succeeded results in around 88% of patients undergoing percutaneous discectomy. Between the end of the 1980s and the beginning of the 1990s other authors reported similar results<sup>11,14,24</sup> with a variable success rate being variable (65–85% of “good results”). All these series reported a combination of posterolateral or direct lateral approach to the disc through the lateral foramen. This is performed under radiological guidance, with succeeding introduction of cannulated endoscopic system for fragment removal of the disc.<sup>2</sup>

The advantages endoscopic lumbar discectomy includes clear visualization, less injury to the paraspinal muscle, protection of spinal stiffness and dynamic structure better cosmetic effect, and less postoperative symptoms than open surgery-related complications with subsequent earlier return to work.<sup>15,26-29</sup> Several authors started to raise criticisms related to the lateral percutaneous approach. The main problem was failure of improvement of the radicular symptoms, which may need another re-exploration surgery in up to 11% of cases.<sup>25,30</sup>

Moreover, Kim et al,<sup>9</sup> in their comparative review documented that the percutaneous discectomy through a direct lateral approach might be restricted by anatomical factors, such as the iliac crest, L5 transverse process or the presence of a large facet joint. To correct these problems, endoscopic interlaminar approach was developed and received progressive population by several authors.<sup>3,19,20</sup> This is performed by a posterior approach to the disc space from the standard route used in microdiscectomy, through a window obtained by positioning of the cannula into the interlaminar space and removing the disc fragment after opening of the ligamentum flavum, which clearly supported from our study via strict indications in each group.

Regarding our inclusion criteria, we preferred to make more wise selection for our cases, because we were starting a new approach, and hoping to advance our skill, which also recommended by many reporters.<sup>11,18,22</sup> Most symptomatic lumbar disc herniations, such as partial intraspinal canals and lateral disc herniations, can be successfully treated with the transforaminal procedure, which was the first approach described by Yeung in 1999.<sup>30,32</sup> However, the transforaminal approach has some disadvantages: the factors of the high-riding



iliac crest (mainly at L4/5 and L5/S1 levels) and the hyperplastic facet joints may block the low lumbar segments. Also, there may be limitations in neural manipulation, the limited foraminal space and exposure to high radiation both for the surgeons and the patients. So, the technique of transforaminal approach is now limited to removing protrusions of all intervertebral discs that located in traforaminal, extreme lateral/far lateral/extra-canalicular disc herniations, lateral disc herniations in selected cases, and confidence in the technique, and this is explain the small number of patients that is belongs to the transforaminal group in our study.

Contraindications are L5-S1 segment (iliac crest and/or L5 transverse process are obstacles for surgical route), anatomical variations, large median and paramedian disc herniations/cauda equina syndrome (decompression not achievable through this route), caudally or cranially migrated fragments, and elderly patients with stenosis-like picture (even if only on the recess)<sup>2</sup>, which also approved in our study.

The interlaminar technique which was described by Choi et al,<sup>4</sup> and Ruetten et al,<sup>16</sup> who stated that a full-endoscopic technique through interlaminar approach could treat LDH at the L5S1 level. Indications include prolapsed median or paramedian disc herniations, recess/lateral canal.

This technique is contraindicated in intraforaminal, extraforaminal disc herniation, lumbar stenosis, and spinal instability at the same segment. Best access to disc space, especially the at the L5-S1 level (compared to transforaminal approach), limited muscle manipulation and damage, less postoperative back pain, reduced postoperative muscle and periradicular fibrosis and limited bone decompression prevent risk of postoperative

instability due to excessive removal of facet joint. It is still not ideal technique for spinal stenosis, it needs high experienced to standard microdiscectomy, and higher recurrence rate<sup>2</sup>.

Our study included the two techniques, and showed that; although both groups gave excellent results, the need to convert to microscopic discectomy was much higher (29.4%) among transforaminal approach patients compared to only (4%) among interlaminar approach patients.

Regarding our operative notes, we didn't fell a big difference from other reviewers in the operative time, which seems to be (TF 14–37, and IL 13–46 minutes) or the mean of intra- and postoperative blood loss was (45 mml)<sup>22</sup> while in our study is slightly higher regarding time, and the blood loss

The rate of the success in previously planned transforaminal approach ranged from (79%-93%) in multi center experience, while in interlaminar approach was ranged from 86 to 97%.<sup>22,27,29,31</sup> In our study (70.6%) had been followed on the planned operative procedure in the transforaminal approach, and (96%) had been followed on the planned operative procedure in the interlaminar approach. Generally that can be explained by the fact that the initial cases were at our learning curve and yet the surgeons were still building experience.

As regards Perioperative Complications, our results runs parallel to previous studies<sup>22,24,31</sup> as there were no serious complications in both group, other than simple complication such as dysesthesia or hyperthesia, which also explained by wise, and meticulous case selection, and lengthy approaches. Regarding VAS score, we found a highly significant reduction of VAS from the first day postoperative and also after 2 weeks of postoperative follow up, compared to the preoperative values. This was agreed by

the study done by Kong et al.,<sup>10</sup> Moreover, our results showed better figures than compared to Kong et al,<sup>10</sup> and Sebastian et al,<sup>22</sup> as regards Mac Nab's score, as we reported an "excellent" results in 79%, a "good" results in 11%, and 10% unsatisfactory outcome of our cases which mostly due to new surgeons experience, and irrelevant patients' expectancy , compared to "excellent" results in 78.3%;and 82% , a"good" results in 13.3%, and 14% r and unsatisfactory results in 8.5% , and 6.3% respectively.

No difference in our study from other reviewers<sup>5,8,22</sup> regarding hospital stay, and recovery of normal daily activities. Although attractive, results of this technique are still under revision, mostly due to learning curve for surgeons, and limited advances of instrumentations not assured with the endoscopic kit in a spinal environment.<sup>5,26</sup>

The recurrence rate of symptoms and/or radiological finding, especially with percutaneous transforaminal (20-40%) which is still higher than the standard microdiscectomy<sup>3</sup> and lack of reliable evidence comparing outcomes of endoscopic and microscopic discectomy. Endoscopic discectomy has a steep learning curve which requires many years of training and experience, patients who were treated at the beginning of the learning curve have bad experience of pain and outcome was worst.<sup>26,27,30</sup> Achievement of surgical training including didactic lectures, hands on cadaveric training, and surgical observation should all be enrolled of surgical education and instruction to address best surgical outcomes.

## Conclusion

Pure endoscopic discectomy is an effective surgical method for treatment of lumbar disc prolapse. This study assessed the technique and effectiveness of both percutaneous

transforaminal, and interlaminar endoscopic discectomy for the treatment of symptomatic Lumbar Disc Herniation. An understanding of the history, development, technical specifications, surgical functional anatomy, indications and limitations, techniques, and potential complications is necessary to achieve optimal surgical outcomes.

## Reference

1. Abe M, Takata Y, Higashino K, Sakai T, Matsuura T, Suzue N, et al: Foraminoplasty transforaminal percutaneous endoscopic discectomy at the lumbosacral junction under local anesthesia in an elite rugby player, *The journal of medical investigation: JMI* 62(3-4), 238-41, 2015
2. Anichini G, Landi A, Caporlingua F, Beer-Furlan A, Brogna C, Delfini R, et al: Lumbar Endoscopic Microdiscectomy: Where Are We Now? An Updated Literature Review Focused on Clinical Outcome, Complications, and Rate of Recurrence. *Bio Med research international* 417801, 2015
3. Choi G, Lee SH, Raiturker PP, Lee S, Chae YS: Percutaneous endoscopic interlaminar discectomy for intracanalicular disc herniations at L5-S1 using a rigid working channel endoscope, *Neurosurgery* 58(1 Suppl), ONS59-68; discussion ONS59-68, 2006
4. Choi G, Lee SH, Bhanot A, Raiturker PP, Chae YS: Percutaneous endoscopic discectomy for extraforaminal lumbar disc herniations: extraforaminal targeted fragmentectomy technique using working channel endoscope. *Spine* 32(2), E93-9, 2007
5. Jiang W, Sun B, Sheng Q, Song X, Zheng Y, Wang L: Feasibility and efficacy of percutaneous lateral lumbar discectomy in

- the treatment of patients with lumbar disc herniation: a preliminary experience. *Bio Med research international* 378612, 2015
6. Hoogland T, Schubert M, Miklitz B, Ramirez A: Transforaminal posterolateral endoscopic discectomy with or without the combination of a low-dose chymopapain: a prospective randomized study in 280 consecutive cases. *Spine* 31(24), E890-7, 2006
  7. Jha SC, Higashino K, Sakai T, Takata Y, Abe M, Nagamachi A, et al: Percutaneous Endoscopic Discectomy via Transforaminal Route for Discal Cyst, Case reports in orthopedics 273151, 2015
  8. Kambin P, Schaffer JL: Percutaneous lumbar discectomy. Review of 100 patients and current practice. *Clinical orthopaedics and related research* 238:24-34, 1989
  9. Kim HS, Park JY: Comparative assessment of different percutaneous endoscopic interlaminar lumbar discectomy (PEID) techniques. *Pain physician* 16(4):359-67, 2013
  10. Kong W, Liao W, Ao J, Cao G, Qin J, Cai Y: The Strategy and Early Clinical Outcome of Percutaneous Full-Endoscopic Interlaminar or Extraforaminal Approach for Treatment of Lumbar Disc Herniation. *Bio Med research international* 4702946, 2016
  11. Kovac D: Automated endoscopic percutaneous discectomy in the treatment of lumbar disk hernia. *Lijecnicki vjesnik* 113(5-6):158-61, 1991
  12. Li J, Ma C, Li Y, Liu G, Wang D, Dai W, et al: A comparison of results between percutaneous transforaminal endoscopic discectomy and fenestration discectomy for lumbar disc herniation in the adolescents. *Zhonghua yi xue za zhi* 95(47):3852-5, 2015
  13. Lee S, Kim SK, Lee SH, Kim WJ, Choi WC, Choi G, et al: Percutaneous endoscopic lumbar discectomy for migrated disc herniation: classification of disc migration and surgical approaches, *European spine journal* 16(3):431-7, 2007
  14. Leu HJ, Schreiber A: 10 years of percutaneous disk surgery: results and developments. *Schweizerische Rundschau fur Medizin Praxis = Revue suisse de medecine Praxis* 78(51):1434-9, 1989
  15. Liu T, Zhou Y, Wang J, Chu TW, Li CQ, Zhang ZF, et al: Clinical efficacy of three different minimally invasive procedures for far lateral lumbar disc herniation, *Chinese medical journal* 125(6):1082-8, 2012
  16. Ruetten S, Komp M, Godolias G: An extreme lateral access for the surgery of lumbar disc herniations inside the spinal canal using the full-endoscopic uniportal transforaminal approach-technique and prospective results of 463 patients. *Spine* 30 (22):2570-8, 2005
  17. Ruetten S, Komp M, Godolias G: A New full-endoscopic technique for the interlaminar operation of lumbar disc herniations using 6-mm endoscopes: prospective 2-year results of 331 patients, *Minimally invasive neurosurgery* 14(2): 80-7, 2006
  18. Ruetten S, Komp M, Merk H, Godolias G: Full-endoscopic anterior decompression versus conventional anterior decompression and fusion in cervical disc herniations, *International orthopaedics* 33(6):1677-82, 2009
  19. Ruetten S, Komp M, Merk H, Godolias G: Full-endoscopic cervical posterior foraminotomy for the operation of lateral disc herniations using 5.9-mm endoscopes: a prospective, randomized, controlled study. *Spine* 33(9):940-8, 2008

20. Ruetten S, Komp M, Merk H, Godolias G: Full-endoscopic interlaminar and transforaminal lumbar discectomy versus conventional microsurgical technique: a prospective, randomized, controlled study. *Spine* 33(9):931-9, 2008
21. Sanusi T, Davis J, Nicassio N, Malik I: Endoscopic lumbar discectomy under local anesthesia may be an alternative to microdiscectomy: A single centre's experience using the far lateral approach. *Clinical neurology and neurosurgery* 139:324-7, 2015
22. Sebastian R, Martin K, Harry M, Georgios G: full-endoscopic interlaminar and transforaminal lumbar discectomy versus conventional microsurgical techniquea prospective, randomized, controlled study. *Spine* 33(9):931–939, 2008
23. Sinkemani A, Hong X, Gao ZX, Zhuang SY, Jiang ZL, Zhang SD, et al: Outcomes of microendoscopic discectomy and percutaneous transforaminal endoscopic discectomy for the treatment of lumbar disc herniation: A comparative retrospective study. *Asian Spine Journal* 9(6):833-40, 2015
24. Suezawa Y, Schreiber A: Percutaneous nucleotomy with discoscopy. 7 years' experience and results. *Zeitschrift fur Orthopadie und ihre Grenzgebiete* 126(1):1-7, 1988
25. Tsou PM, Yeung AT: Transforaminal endoscopic decompression for radiculopathy secondary to intracanal noncontained lumbar disc herniations: outcome and technique. *The spine Journal* 2(1):41-8, 2002
26. Wang K, Hong X, Zhou BY, Bao JP, Xie XH, Wang F, et al: Evaluation of transforaminal endoscopic lumbar discectomy in the treatment of lumbar disc herniation. *International orthopaedics* 39(8):1599-604, 2015
27. Wang L, Liu C, Li GQ, Tian JW: Transforaminal lumbar interbody fusion in the treatment of lumbar intervertebral disc herniation with lumbar instability. *Zhonghua yi xue za zhi* 92(39):2781-4, 2012
28. Wang B, Lu G, Liu W, Cheng I, Patel AA: Full-endoscopic interlaminar approach for the surgical treatment of lumbar disc herniation: the causes and prophylaxis of conversion to open. *Archives of orthopaedic and trauma surgery* 132(11):1531-8, 2012
29. Wang SQ, Yu J, Feng MS, Luo J, Yang KX, Zhao GD: Opinious of lumbar intervertebral disc herniation. *Zhongguo gu shang, China journal of orthopaedics and traumatology* 25(1):55-7, 2012
30. Weil AG, Westwick H, Wang S, Alotaibi NM, Elkaim L, Ibrahim GM, et al: Efficacy and safety of endoscopic third ventriculostomy and choroid plexus cauterization for infantile hydrocephalus: a systematic review and meta-analysis. *Child's nervous system* 32(11):2119-31, 2016
31. Yeung AT, Tsou PM: Posterolateral endoscopic excision for lumbar disc herniation: Surgical technique, outcome, and complications in 307 consecutive cases. *Spine* 27(7):722-31, 2002
32. Yeung AT: Minimally Invasive Disc Surgery with the Yeung Endoscopic Spine System (YESS). *Surgical technology international* 8:267-77, 1999
33. Yeung A, Gore S: Endoscopic foraminal decompression for failed back surgery syndrome under local anesthesia. *Int J Spine Surg* 8:22-29, 2014



## الملخص العربي

### استخدام المنظار الجراحي الدقيق في استئصال الانزلاق الغضروفي القطني للمقارنة ما بين الصفيحة الفقرية أو من خلال القناة العصبية الجذرية القطنية

**البيانات الخلفية:** يعتبر استئصال الانزلاق الغضروفي القطني بواسطة الطرق الجراحية التقليدية هو الأساس في علاج هذا النوع من الانزلاقات الغضروفية، إلا أن استخدام الطرق الحديثة مثل المنظار الجراحي الدقيق يوفر عدة مميزات، منها الرؤية الواضحة، وتقليل إصابة العضلات القطنية، والوقاية من تشوهات العمود الفقري والمحافظة على الهيكل الديناميكي للفقرات، ومضاعفاته أقل من العملية الجراحية التقليدية مع العودة للعمل سريعاً.

**الغرض:** أجريت هذه الدراسة لتقييم فعالية المنظار في استئصال الانزلاق الغضروفي القطني من خلال الصفيحة الفقرية أو من خلال القناة العصبية الجذرية القطنية.

**تصميم الدراسة:** دراسة وصفية مستقبلية لدراسة سلسلة من الحالات المحتملة.

**المرضى والطرق:** أجريت هذه الدراسة على ٤٢ مريض الذين لديهم انزلاق غضروفي القطني لم ينجح معهم العلاج الطبي المستمر لمدة ٦ أشهر من المرضى الذين يحضرون إلى أقسام جراحات المخ الأعصاب في مستشفيات جامعة الإسكندرية وجامعة المنوفية وجامعة سوهاج في الفترة من يناير ٢٠١٢ إلى فبراير ٢٠١٦. جميع المرضى خضعوا لاستئصال الانزلاق الغضروفي القطني إما من خلال الجراحة بالمنظار خلال الصفيحة الفقرية أو من خلال القناة العصبية الجذرية القطنية.

**النتائج:** كان لجميع المرضى تحسناً ملحوظاً في درجة الألم، وفقاً للمعايير فقد أعطى ٧٩٪ من المرضى نتائج ممتازة وأعطى ١١٪ نتائج جيدة. مما يعطي نتائج مرضية لحوالي ٩٠٪. من بين ٢٥ مريضاً خضعوا للجراحة بالمنظار خلال الصفيحة الفقرية، ٢٤ مريض بنسبة ٩٦٪ قد اتبعت معهم الخطوات الجراحية المخطط لها. من الناحية الأخرى، من أصل ١٧ مريض قد خضعوا للجراحة بالمنظار من خلال القناة العصبية الجذرية القطنية فإن ١٢ مريض فقط وبنسبة ٧٠,٦٪ خضعوا للخطوات الجراحية المخطط لها.

**الاستنتاج:** استئصال الانزلاق بالمنظار هو طريقة جراحية فعالة لعلاج الانزلاق الغضروفي القطني.