

Recurrent Lumbar Disc Herniation: Conventional Re-discectomy Versus TLIF with Unilateral Fixation

Tariq Elemam Awad MD., Salem Salman Faisal MD.

Department of Neurosurgery, Faculty of Medicine, Suez Canal University, Ismailia, Egypt.

Abstract

Background Data: Recurrent lumbar disc herniation is reported from 5 to 11%. Optimal surgical approach for recurrent disc prolapse is controversial. Some authors believe that repeat discectomy is the treatment of choice, with similar clinical results compared to the primary procedure. Some spine surgeons believe that fusion is necessary for treating disc reherniation.

Purpose: Our aim is to compare the clinical outcome in patients with recurrent lumbar disc herniation operated by conventional rediscetomy versus those operated by TLIF with unilateral pedicle screw fixation.

Study Design: A descriptive controlled, non-randomized, retrospective, clinical study.

Patients and Methods: Forty patients underwent surgery for recurrent lumbar disc herniation. They were divided into two groups; re-discectomy group and TLIF with unilateral fixation group. Each group included 20 patients. They were operated between 2008 and 2016. Participants were evaluated pre-operatively and post-operatively every three months. Operative time, hospital stay and complications were assessed. Pain was scored by a VAS for both lower limbs and back pain. The clinical outcomes were compared using the Prolo economic and functional rating scale. In addition fusion was looked for radiologically.

Received at:

June 21st, 2016

Accepted at:

August 2nd, 2016

Results: The two groups of patients were fairly homogeneous and comparable. TLIF group showed better clinical outcome parameters including better VAS for low back pain and better Prolo economic, functional rating scale. In comparison the re-discectomy group showed significantly higher complications and reoperation during the follow up period.

Conclusion: Patients with recurrent lumbar disc herniation operated by TLIF with unilateral spinal fixation reported less pain & lower disability scores all over the follow up period. This technique is preferable to conventional re-discectomy because it avoids the possibility of recurrence and has less postoperative complications. (2016ESJ124)

Keywords: Recurrent Lumbar disc herniation, Discectomy, Unilateral pedicle screws, Transforaminal lumbar interbody fusion

Introduction

Recurrent lumbar disc herniation is reported from 5 to 11%, with an increased incidence as the follow-up period is extended.^{3,6,12} Optimal surgical approach for recurrent disc prolapse is controversial. Dealing with recurrent true lumbar disc prolapse represents a challenge for the spine surgeon. On one hand, the previous laminotomy disturbed the normal anatomic landmarks and the postoperative perineurial adhesions surrounded the nerve root and the thecal sac. This renders the surgical approach more difficult. In addition, the lumbar disc with true recurrent disc herniation had sustained repetitive degeneration cascade render its components nonfunctional in the proper way. Thus the disc cannot act as a shock absorber and may be a source of discogenic low back pain.³

Transforaminal lumbar interbody fusion (TLIF) may have some merits in dealing with true recurrent lumbar disc prolapse. TLIF approach the herniated lumbar disc away from the spinal canal. It is away from the compressed inferior nerve root and away from perineurial adhesions. In addition the interbody curettage and fusion inhibits any chance of further recurrence.

Some authors believe that repeat discectomy is the treatment of choice, with similar clinical results compared to the primary procedure.^{4,10}

Others² believe that fusion is necessary for treating disc reherniation.

Patients and Methods

This study was designed as a controlled, non-randomized, retrospective, clinical study. Between February 2008 and July 2016, at Suez Canal area Hospitals (Ismailia, Egypt) a total of forty consecutive patients were included. The patients were categorized into two groups (non-randomized):

Group 1 (re-discectomy): included 20 patients operated by repeat conventional discectomy.

Group 2 (TLIF): included 20 patients operated by TLIF with unilateral lumbar fixation.

Inclusion criteria required all patients to have (1) Previous history of laminectomy or discectomy at the same level of recurrence either the same side or contralateral side. (2) Predominantly radicular symptoms e.g. intolerable sciatica, or had severe neurological loss (motor loss or symptoms or signs of cauda equina syndrome) (3) A preoperative magnetic resonance imaging study confirming a recurrent disc herniation. (4) Patients should have been unresponsive to conservative management for a minimum of 6 weeks and should qualify for surgery for a single-level disc reherniation between L2-S1.

Exclusion criteria ruled out patients (1) with general diseases that preclude surgical

management (severe osteoporosis, osteopenia, immune suppression, malignancy and active local and/or systemic infection), (2) with morbid obesity as measured by body mass index > 40, (3) those with spondylolisthesis or any form of segmental instability.

Preoperative assessment included patient history, physical examination and neurological examination. Imaging included antero-posterior, lateral and dynamic lateral X-rays and CT and MRI of the lumbo-sacral spine. Preoperative economic (activity) and functional (pain) statuses were assessed and the clinical outcome was evaluated using the Prolo economic and functional rating scale.¹¹ Additionally, the entire quantity of pain was evaluated using visual analog scale (VAS) for both leg and axial low back pain.

All patients were operated using midline posterior skin incision and subperiosteal retraction of the para-spinal muscles to expose the affected segment. In patients who received conventional re-discectomy, we started at the medial edge of the previous laminectomy and we performed medial facetectomy toward the affected nerve root. Exploration was then started and we cleared adhesions with dissector to look for annular defect or any free fragments. An oblique 45° incision was made with a number-15 blade in the annulus and the slit was explored. The disc space was curetted or debrided deep to the annulus to remove disc fragments. In patients who received TLIF with unilateral spinal fixation, Unilateral resection of the inferior articular facet of the superior vertebra and the upper part of the superior articular facet of the inferior vertebra were accomplished exposing unilaterally the intervertebral foramen. Then we exposed the posterolateral portion of the ipsilateral disc space in the topography of the vertebral foramen. Coagulation (with bipolar) of

the small epidural vessels, and visualization and protection of the dura medially was followed. Unilateral pedicle screws were placed in the standard fashion followed by removal of the disc through the vertebral foramen, and also of the end plates. Harvested local bone was then packed in the disc space. Final rods of desired length were contoured to the appropriate lordotic curve and were applied over the pedicle screws in compression. (Figure 1) In both groups of patients, duration of surgery, blood loss, and the duration of inpatient treatment were recorded. Intraoperative and perioperative major and minor complications were assessed.

Patients were followed 3 weeks, 3, 6, 9 and 12 months after surgery. During follow up visit the following data were collected: location of pain; intensity of leg and back pain according to the VAS; neurological symptoms; medication, complications, recurrence of symptoms and subsequent spinal surgery. Assessment of the patients' clinical outcome was evaluated using the Prolo economic and functional rating scale, in which there is a maximum score of 10 points. (Poor: 2–4, fair: 5–6, good: 7–8, and excellent: 9–10 points). Good and excellent results were considered a clinical success.¹¹ Finally patients were asked to rate their condition has improved, unchanged, or worsened; they were also questioned as to whether they would undergo the same procedure again under the same circumstances.

Radiological interbody fusion in the TLIF group was assessed at individual levels as observed on plain radiographs that were obtained postoperatively every three months. We used the criteria approved by the FDA for evaluation of lumbar intervertebral fusions. Fusion was defined as a continuous bone bridge between the vertebrae seen in lateral X-ray.^{2,13}

Results

The demographic data of the two study groups are presented in (Table 1), and showed that the two groups of patients were fairly homogeneous and comparable. The mean age in the re-discectomy group was 32.4 years in comparison to 35.3 years in the TLIF group. The average BMI was 27.9 in the re-discectomy group in comparison to 28.9 in the TLIF group. A positive smoking history was recorded in sixteen patients of the study group (26.5%) and secondary gain issue was present in 15% of the study group. There is no statistical significant difference between the two groups for these parameters.

On average, patients had preoperative symptoms duration for 1.5 years (range 0.2–2.9 years). Patients in the re-discectomy group had mean preoperative symptoms duration for 1.3 ± 0.9 years in comparison to 1.6 ± 0.8 years in patients in the TLIF group.

Figure 2 shows distribution of the operative level within the two study groups. About 70% of surgeries were done at L4-5 level.

In regard to the perioperative findings in the 2 groups, the re-discectomy group showed less intraoperative blood loss, shorter operative time and hospital stay in comparison to the TLIF group and this was statistically significant. (Table 2)

We used many parameters to assess and compare the clinical outcomes in the 2 groups of patients. The 100 visual analogue scale for back pain showed statistically significant improvement in the low back pain in TLIF group all over the follow up period. (Figure 3) Also the 100 visual analogue scale for lower limb pain showed better outcome in the TLIF group (figure 4).

When the outcome was evaluated by more practical means, such as the Prolo economic and functional scale, the TLIF group showed statistically significant improvement in the clinical outcomes. (Figure 5) In 12 months follow up visit, when the patients were asked if, under the same circumstances, they would undergo the procedure again, 80% of the patients (32 patients) answered affirmatively and this is reflects their satisfaction with the results of their surgeries. This satisfaction in the TLIF group was in 19 patients (95%) and in the re-discectomy group was in 13 patients (65%).

Complications in both groups are summarized in table 3 and can be divided into:

Intraoperative complications: Seven dural tears were recorded in whole series. There were all in the re-discectomy group.

Early postoperative complications: Seven neurological complications were recorded in whole series. Four were in the re-discectomy group and three were in the TLIF group. Five of these were radicular pain and dyesthesia that had resolved within 1-2 month interval in all the five patients. Two patients suffered increasing motor deficit after surgery. This was in the form of added weakness of the extensor Hallucis longus tendon that improved over the follow up with no added deficits to the patients. There were four superficial wound infections in whole series that required culture and treatment with intravenous antibiotics. One case of deep wound infection in the TLIF group was treated by daily dressing and intravenous antibiotics according to culture and sensitivity results.

Late postoperative complications: Recurrent lumbar disc prolapse occurred in three patients of the re-discectomy group. Two patients underwent reoperative interventions with Fixation and fusion of the index level.

Table 1: Preoperative Data of the Study Groups

Parameters		Re-discectomy	Fusion	Total
Patients / Sex:		20 male	20 male	40 male
Age, yr		32.4	35.3	33.9
Age group	20-	6	4	10
	30-	8	9	17
	40-	4	6	10
	50-	2	1	3
Body mass index*		27.9	28.9	28.4
Smokers		5(25 %)	6(30 %)	11(26.5 %)
Secondary gain issue		3(15%)	3(15 %)	6(15 %)

* Obesity is defined as BMI that is higher than 30 of the body mass index.

Table 2. Peri-Operative Data of the Study Groups

Parameters	Re-discectomy group	TLIF Group
Blood Loss (ml)	240±60 (170-460)	342±80 (250-750)
Surgical Time (min)	85±20 (60- 95)	130±50 (100-180)
Days in hospital	1.7±2.8 (1-11)	2.4±1.5 (2–10)

Table 3. Comparison Between the Two Groups As Regard to the Complications Recorded.

Parameters		Re-discectomy group	TLIF Group	Total
Intraoperative	Dural tear	7	0	7
Early post-operative	Radicular pain and dysthesia	3	2	5
	Increased Motor weakness	1	1	2
	Superficial wound infection	2	2	4
	Deep wound infection	0	1	1
Late post-operative	Recurrence	3	0	3
	Reoperation	2	0	2

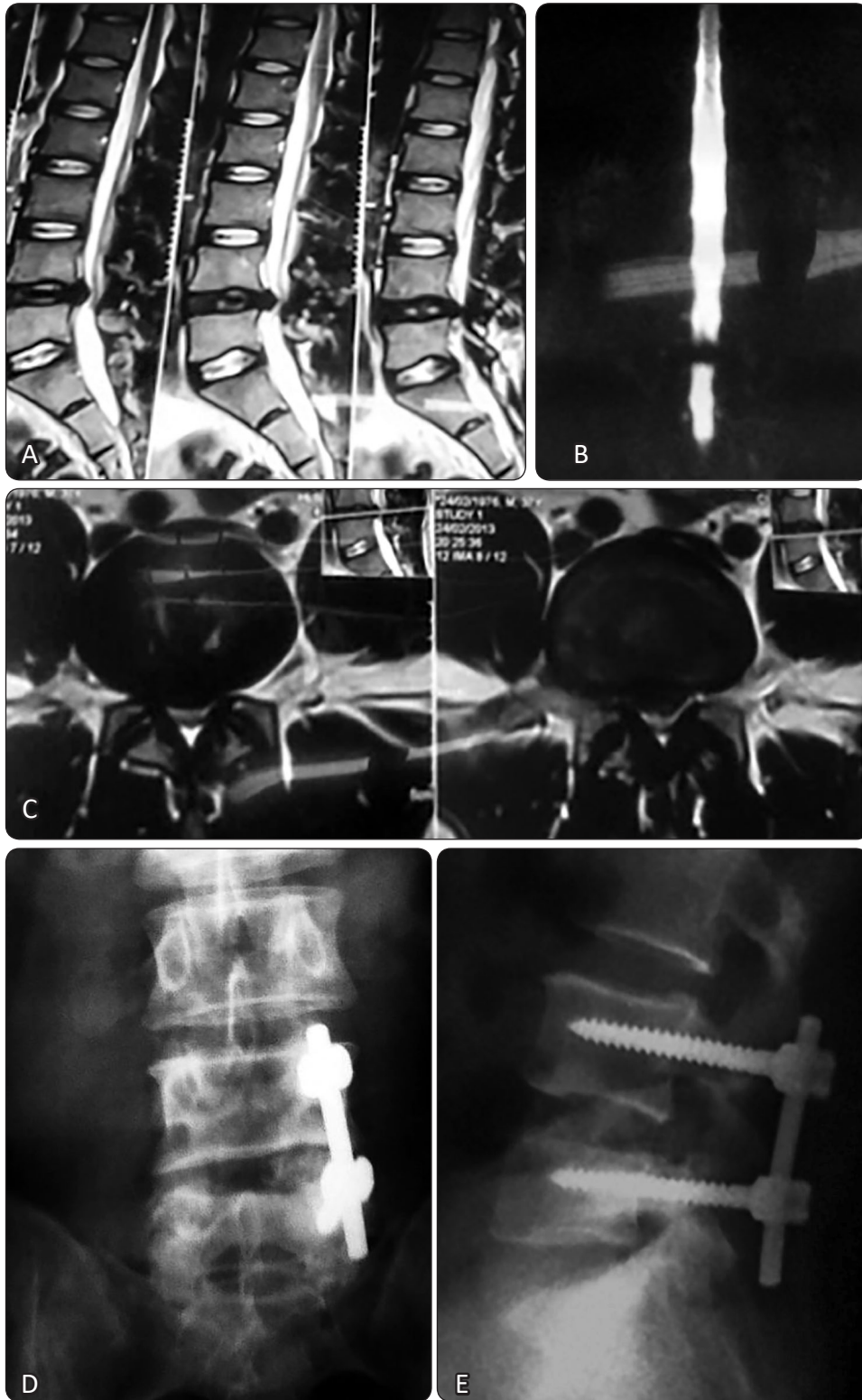


Figure 1. Images of 37 years old male. Preoperative MRI lumbosacral spine, (A) sagittal T2-weighted image (B) MRI Myelogram and (C) axial T2WI showing recurrent LDP of L4-5 level, Postoperative 12 months follow up plain x-ray lumbosacral spine AP view (D), and lateral view (E) with unilateral transpedicular screw fixation and fusion of L4-5.

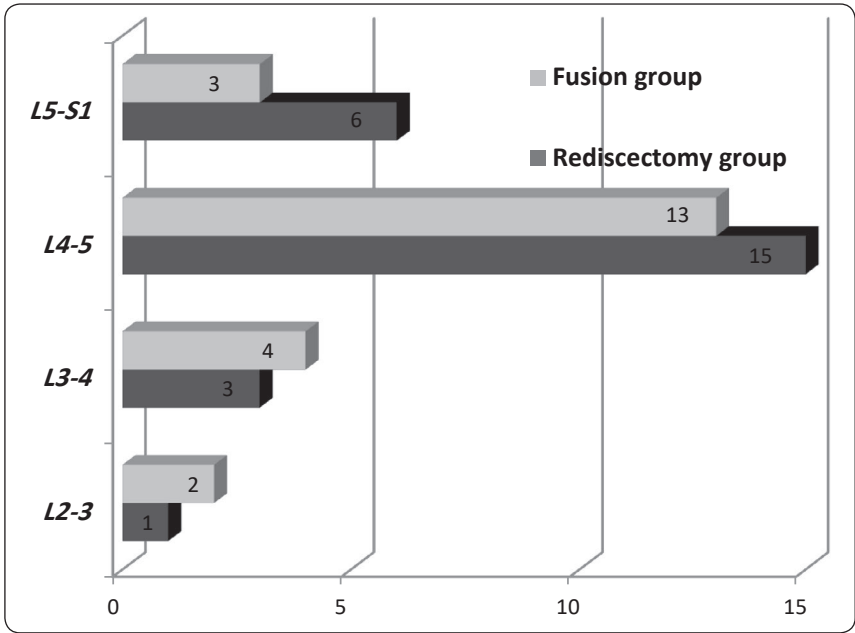


Figure 2. Distribution of level of surgery in the two groups of patients

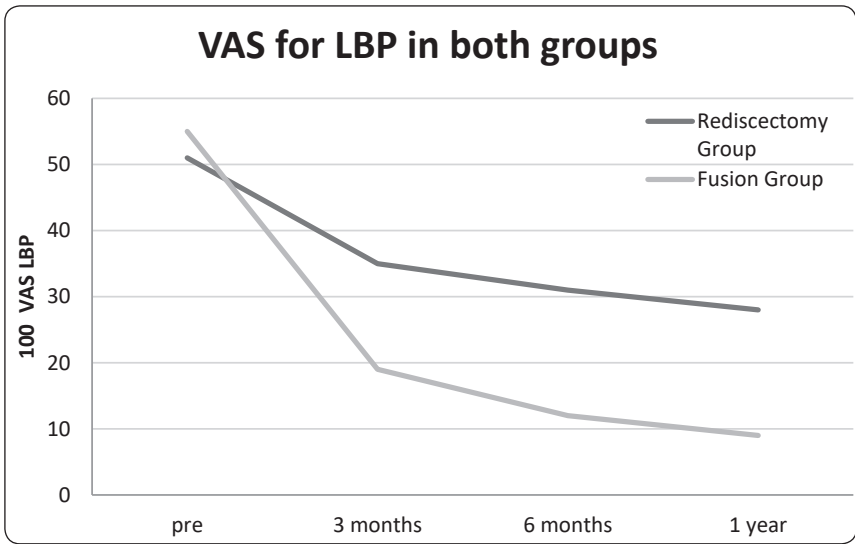


Figure 3. A significant reduction in VAS of back pain in TLIF group in comparison to Discectomy group

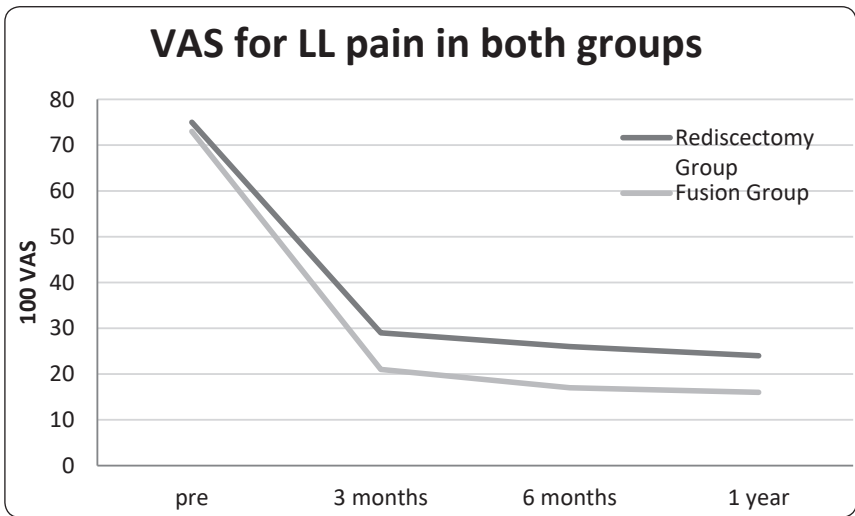


Figure 4. A significant reduction in VAS of lower limb pain throughout the observation period in the 2 study groups.

Clinical Outcome according to Prolo Scale

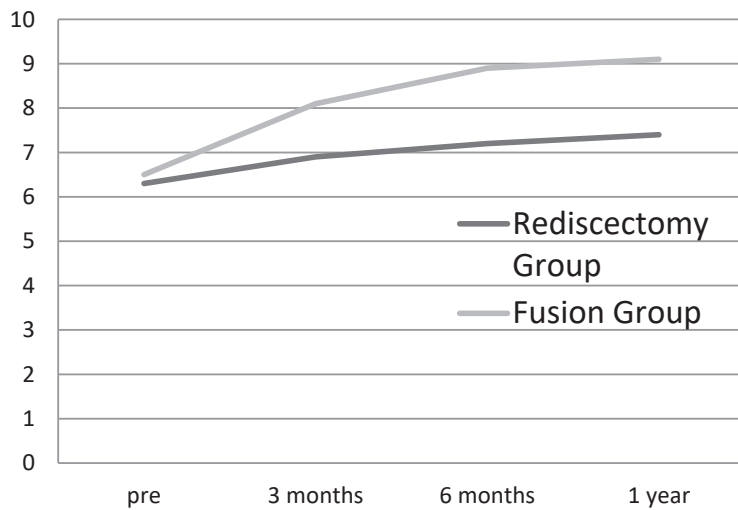


Figure 5. The clinical outcome in TLIF group is significantly better according to Prolo economic and functional scale.

Discussion

The optimal surgical approach for recurrent disc herniation remains a subject of controversy. Discectomy with fusion has several theoretical advantages. Specifically, interbody fusion reduces or eliminates segmental motion, immobilizes the spine, reduces mechanical stresses across the degenerated disc space¹ and eliminates additional herniation at the affected disc space.¹⁴ Lehmann and La Rocca⁹ treated 36 patients following previous lumbar surgery by spinal canal exploration and spinal fusion. Solid fusion correlated closely with satisfactory outcomes, and the patients in the TLIF group tended to have better outcomes than those with disc excision alone.

Revision spinal surgery is more challenging than primary surgery, owing to the indistinct anatomical planes and perineural scarring. Ebeling et al,⁵ reported a complication rate of 13% after repeated discectomy, and dural tears and infections were the most common problems. However, TLIF provides an approach through facetectomy to enter unscarred virgin tissue. Therefore, the surgeon can approach the target site safely without demanding dissection

of the fibrotic scar tissues, and excessive retraction of scarred nerve root and dura, the potential risk of dural tear and nerve injury may also be decreased.^{8,9} Seven (35%) cases experienced dural tear during re-discectomy surgery in our series, in comparison to no dural tear in TLIF group.

Postoperative degenerative changes after the conventional discectomy can arise with time. Gradual disc space subsidence and impingement of the superior facet could result in foraminal stenosis. Because the foraminal portion can be exposed in the course of the TLIF approach, adequate foraminal decompression can be easily accomplished.^{3,4,10,14}

Based on these clinical outcomes, as well as the theoretical advantages of TLIF, we found the TLIF technique to be an effective procedure with satisfactory clinical results for the treatment of recurrent lumbar disc herniation. It can restore the stability and lordosis of the lumbar spine, and has low complication rates.

In a meta-analysis to more accurately estimate the effectiveness of unilateral versus bilateral pedicle screw fixation in lumbar spinal fusion. A total of nine studies involving 567 patients were included. Unilateral pedicle screw

fixation was performed in 287 patients and bilateral pedicle screw fixation in 280 patients. The results indicated that in comparison with bilateral fixation, unilateral fixation can shorten the operation time, reduce the amount of bleeding, and reduce medical expenses. There were similar effects with regard to hospitalization days, fusion rate, complication rate, and excellent and good rates. This is true for one or two segmental lumbar spinal fusion.⁷

Conclusion

Patients with recurrent lumbar disc herniation operated by TLIF with unilateral pedicle screw fixation reported less pain & lower disability scores all over the follow up period. This technique is preferable to conventional re-discectomy because it avoids the possibility of recurrence and has less postoperative complications.

References

1. Barrick WT, Schofferman JA, Reynolds JB: Anterior lumbar fusion improves discogenic pain at levels of prior posterolateral fusion. *Spine* 25:853–857, 2000
2. Brantigan JW: Carbon fiber I/F Cage system for interbody vertebral Fusion. In Haid RW, Mclaughlin MR, Fessler RG: Lumbar Interbody Fusion Techniques. Cages, Dowels, and Grafts. Quality Medical publishing, Inc. ST. Louis, Missouri. Ch 19, pp 247-271, 2003
3. Cinotti G, Roysam GS, Eisenstein SM: Ipsilateral recurrent lumbar disc herniation. A prospective, controlled study. *J Bone Joint Surg Br* 80:825–832, 1998
4. Cinotti G, Gumina S, Giannicola G: Contralateral recurrent lumbar disc herniation. Results of discectomy compared with those in primary herniation. *Spine* 24:800–806, 1999
5. Ebeling U, Kalbarczyk H, Reulen HJ: Microsurgical reoperation following lumbar disc surgery. Timing, surgical findings, and outcome in 92 patients. *J Neurosurg* 70:397–404, 1989
6. Fandiño J, Botana C, Viladrich A: Reoperation after lumbar disc surgery: results in 130 cases. *Acta Neurochir (Wien)* 122:102–104, 1993
7. Hu XQ, Wu XL, Xu C, Zheng XH, Jin YL, Wu LJ, Wang XY, Xu HZ, Tian NF: A systematic review and meta-analysis of unilateral versus bilateral pedicle screw fixation in transforaminal lumbar interbody fusion. *PLOS One* 9(1):2014 e87501
8. Kim SS, Michelsen CB: Revision surgery for failed back surgery syndrome. *Spine* 17:957–960, 1992
9. Lehmann TR, LaRocca HS: Repeat lumbar surgery. A review of patients with failure from previous lumbar surgery treated by spinal canal exploration and lumbar spinal fusion. *Spine* 6:615–619, 1981
10. Papadopoulos EC, Girardi FP, Sandhu HS: Outcome of revision discectomies following recurrent lumbar disc herniation. *Spine* 31:1473–1476, 2006
11. Prolo DJ, Oklund SA, Butcher M: Toward uniformity in evaluating results of lumbar spine operations. A paradigm applied to posterior lumbar interbody fusions. *Spine* 11:601-606, 1986
12. Reith C, Lausberg G: Risk factors of recurrent disc herniation. *Neurosurg Rev* 12:147–150, 1989
13. Tullberg T, Brandt B, Rydberg J: Fusion rate after posterior lumbar interbody fusion with carbon fiber implant: 1-year follow-up of 51 patients. *Eur Spine J* 5:178-182, 1996
14. Vishteh AG, Dickman CA: Anterior lumbar microdiscectomy and interbody fusion for the treatment of recurrent disc herniation. *Neurosurgery* 48:334–337, 2001

Address reprint
request to:

Tariq Elemam Awad, MD.

Department of Neurological Surgery, School of Medicine, Suez Canal University
Hospital, Ismailia, Egypt. - Email: Tariqelemam@yahoo.com

الملخص العربي

الانزلاق الغضروفي القطني المرتجع: اعادة الاستئصال الغضروفي التقليدي مقابل اللحام مع التثبيت من جانب واحد

المقدمة : الاستئصال التقليدي للغضروف القطني هو طريقة جراحية لعلاج الانزلاق الغضروفي القطني. قد تختلف الحالة في العمال اليدويين ذو المهام الثقيلة الذين قد يكون لديهم امراض العمود الفقري التنكسية أكثر وضوحا، وفتق القرص الغضروفي على نطاق واسع، ومن المتوقع أن يتعرض هؤلاء العمال بعد العمل الجراحي لنفس الإجهاد اليدوي قبل الجراحة.

الهدف: توضيح النتائج الجراحية و المقارنه بين اعاده الاستئصال الغضروفي التقليدي مقابل اللحام مع التثبيت من جانب فى حالات الغضروف المرتجع

تصميم الدراسة: دراسته لحالات اكلينيكيه على ٤٠ مريض يعانون من الانزلاق الغضروفي القطني المرتجع

المرضى والطرق: تم اجراء الجراحات من ٢٠٠٨ الى ٢٠١٦ . تم متابعه الاعراض و العلامات و ملاحظه النتائج الاكلينيكيه. تم تقسيم المرضى الى مجموعتين. المجموعه الاولى تم اجراء اعاده استئصال تقليدى للغضروف المرتجع و المجموعه الثانيه تم اجراء لحام بين اجسام الفقرات القطنيه مع التثبيت من جانب واحد

النتائج: اوضحت النتائج تقارب المجموعتين من المرضى من حيث الخصائص الديموجرافيه و الاعراض و خصائص الاشعات . اظهر المرضى فى مجموعه اللحام العظمى تحسنا اكثر فى مقاييس اللام و عدم ارتجاع الغضروف

الاستنتاج: يتضح من هذه الدرسته ان النتائج السريره للاحام العظمى بين اجسام الفقرات يحمل نسبه تحسن اكثر فى مقاييس اللام و تحسن حاله الاكلينيكيه و مضاعفات اقل من اعاده استئصال الغضروف.