

## Ligamentum Flavum Cyst in the Lumbar Spine: A Case Report

Tarek AA Abotakia MD,<sup>1</sup> Ahmad FA Allam MD, MRCS,<sup>1</sup> Wael Koptan MD<sup>2</sup>

*Orthopedic Department, Minia University, Minia<sup>1</sup>, Orthopedic Department, Cairo University, Cairo<sup>2</sup> Egypt.*

### Abstract

**Background Data:** Ligamentum flavum cysts have rarely been reported, it is believed to be a result of degenerative process. Complete excision of the cyst leads to excellent results. Ligamentum flavum cysts have rarely been reported worldwide and never published as an Egyptian case.

**Purpose:** To report a case of ligamentum flavum cysts in the lumbar spine.

**Study Design:** Case Report.

**Patients and Methods:** We reported a case of ligamentum flavum cyst at the level of L4-5 in a 45 year old Egyptian woman, meticulous complete excision of the cyst without any durotomy or CSF leakage. Histopathological examination reported myxoid degeneration of the ligamentum flavum with no synovial cells.

**Results:** the patient was satisfied and all her symptoms were completely resolved with 1 year follow up.

**Conclusion:** ligamentum flavum cyst should be put in mind when reading the MRI. Complete surgical excision should be carried meticulously. (2016ESJ123)

**Keywords:** Ligamentum flavum, cyst, Lumbar spine

Received at:

June 29<sup>th</sup>, 2016

Accepted at:

September 1<sup>st</sup>, 2016

## Introduction

Lumbar spinal stenosis is commonly caused by degenerative conditions, such as herniated nucleus pulposus, diseased facet joint or hypertrophied ligamentum flavum. Less common etiologies include intraspinal extradural masses, synovial cysts, ganglion cysts, pseudocysts, haematoma and metastatic tumour. Cysts originated from ligamentum flavum are even more uncommon.<sup>13</sup>

Ligamentum flavum cysts have rarely been reported. Usually this type of cyst located in the lower lumbar region in elderly patients as a result of degenerative process. Because of rarity of ligamentum flavum cysts and nonspecific clinical and radiologic findings, the preoperative diagnosis is not easy. Complete excision of the cyst leads to excellent results.<sup>11</sup>

### Case Presentation

A 45 year old farmer woman sought for orthopaedic consultation because of rapidly progressing bilateral lower limb pain, weakness and numbness for 2 years. Walking tolerance was limited to less than 10 minutes that progressed to less than 2 minutes in the last month. Bilateral leg pain increased with cough, sneezing and straining. No history of sphincteric dysfunction.

Physical examination showed tenderness over the lower lumbar vertebrae, positive straight leg raising test at 60 degrees on the left side & at 40 degrees on the right side with tension sign, grade 4/5 motor weakness of extensor hallucis longus muscle at both sides with decrease in light touch sensation over L5 dermatomes bilaterally. Lower limb reflexes were intact. All the features were compatible with bilateral sciatica of L5 radiculopathy.

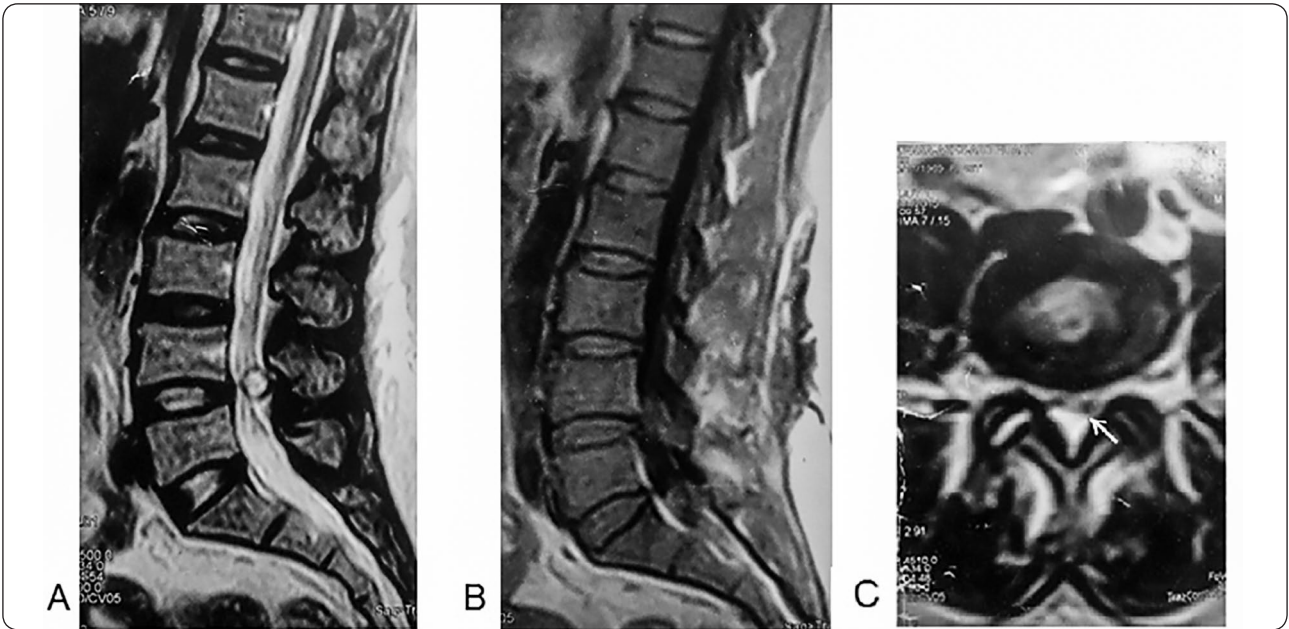
Radiograph of the lumbosacral spine demonstrated decreased L4/5 intervertebral disc height. MRI of the same region showed L4/5 disc bulging and a well circumscribed cystic lesion

dorsal to the thecal sac showing high-intensity signal in T2-weighted images and hypointense in T1-weighted images. The cyst was separable from the thecal sac and severely compromising it causing severe spinal canal stenosis (Figure 1).

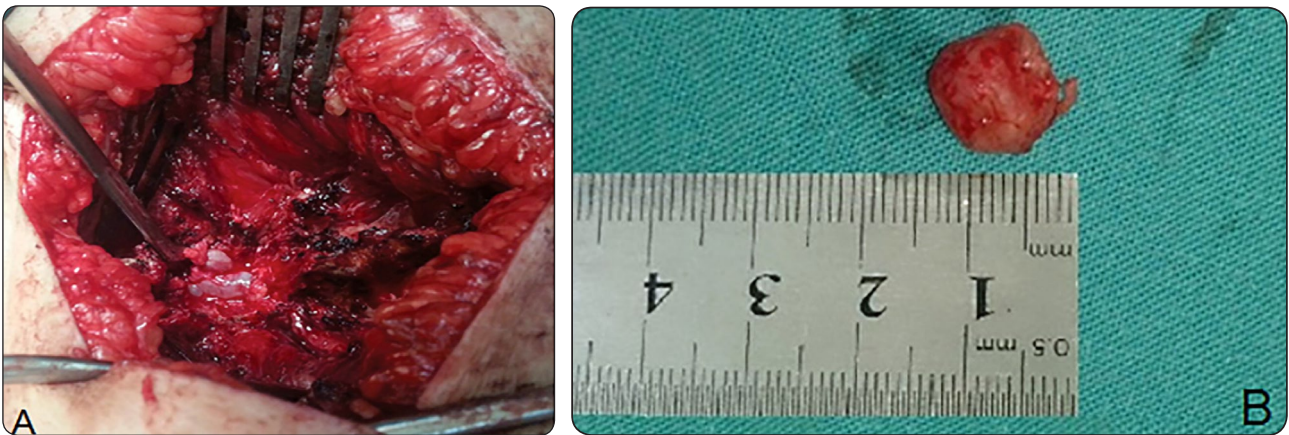
The patient was treated conservatively with a short course of nonsteroidal anti-inflammatory drugs, lumbar support, and physiotherapy. This regimen failed to alleviate the patient's symptoms so a surgical decompression and excisional biopsy was planned after informed consent. The patient was placed under general anesthesia in the prone position. A longitudinal midline incision with exposure of the L4-5 junction was made. As we carried out laminectomy on the L4 lamina, we found moderate thickened ligamentum flavum. The mass was originated from ligamentum flavum compressing the thecal sac centrally and more at the left side and it was tightly adherent to the dura without any communication to the facet joint (Figure 2A). Meticulous blunt dissection was carried out till complete excision of the cyst without any durotomy or CSF leakage and showed no communication with the subarachnoid space. The cyst was globular in shape measuring about 13x15x16 mm (Figure 2B). The compressed anteriorly pushed thecal sac was then seen completely released after removal of cyst. Histopathological examination reported myxoid degeneration of the ligamentum flavum in the form of homogenous mucoid tissue infiltrated by chronic inflammatory cells with no synovial cells (Figure 3).

## Results

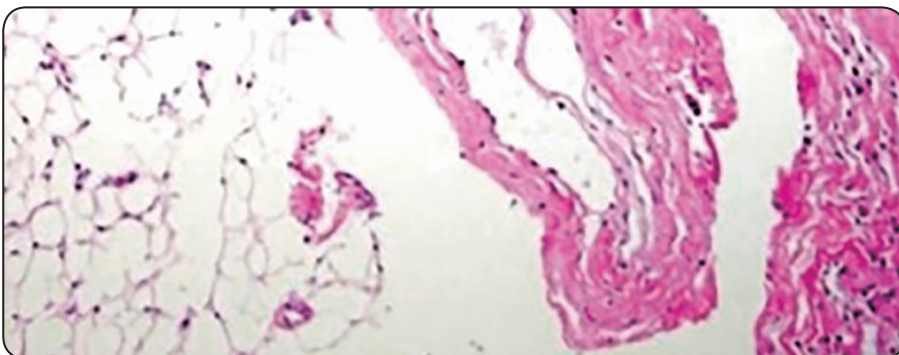
Our patient had a smooth operative and postoperative intrahospital course. She was satisfied and showed complete postoperative resolution of her symptoms. She is neurologically intact and symptoms free with 1 year follow up.



**Figure 1.** Magnetic resonance images showing well circumscribed cystic lesion dorsal to the thecal sac at the level of L4/5 high-intensity signal in T2-weighted images (A,C) and hypointense in T1- weighted images (B). The cyst was separable from the thecal sac with a line of cleavage in-between (arrow).



**Figure 2.** (A) intraoperative photo of the cyst. (B) The cyst after excision measured about 13x15x16 mm.



**Figure 3.** Histopathology specimen showing: fibrotic connective tissue wall infiltrated by chronic inflammatory cells with no synovial cells. The ground substance consists of homogenous mucoid tissue.

## Discussion

Ligamentum flavum cysts in the lumbar spine occur commonly at L4-5 level because this level is the most mobile segment. In the cervical spine, only a few cases have been reported. The frequency at lumbar spine of ligamentum flavum cyst was as follows: L4-5 (56%), L5-S1 (23%), L3-4 (20%), L2-3 (1%) level.<sup>14</sup>

Minor chronic trauma as in spondylolysis, spondylolisthesis and degenerative disc disease can cause continuous stress to the ligamentum flavum and may predispose for cyst formation.<sup>4</sup> The aging process of the ligamentum flavum causes thickening and loss of elasticity.<sup>7,14</sup> Change in proteoglycans, loss of elastic fibers, and increase in collagen tissue and chondroid metaplasia due to mechanical stress have been described. Also and closely related to aging, amyloid can accumulate within the ligamentum flavum. This amyloid deposition has been reported in only a few cases to be associated with systemic amyloidosis.<sup>12,15</sup>

There are no specific clinical symptoms for ligamentum flavum cyst. Cysts in the spinal canal can compress neural structures and lead to neurologic symptoms. The majority of symptomatic cysts usually presents with radiculopathy, such as sciatica in the case of lumbar cysts, and can mimic symptoms related to intervertebral disc herniation<sup>9</sup>.

Wildi et al,<sup>19</sup> studied pseudocystic degeneration of the lumbar ligamentum flavum and reported that 97% patients complained of radicular pain, 39% showed motor deficits, 55% had sensory changes, 18% had abnormal reflexes, and 33% showed a positive Lasègue sign.

Our patient presented with low back pain, gradually developing bilateral radicular pain involving mostly the L5 distribution with bilateral leg claudication and no motor deficit.

Radiological differentiation of ligamentum flavum cysts is difficult. Plain X-rays mostly show only degenerative changes. Because the radiologic features are nonspecific, differentiation from other intraspinal cysts is very difficult.<sup>3</sup> Magnetic resonance imaging is the recommended imaging modality; on T1-weighted images, the ligamentum flavum cysts have a hypo intense signal, and on T2-weighted images, the cysts have a high-intensity signal with no communication with the facet joint. Differential diagnosis between ligamentum flavum cysts and synovial cysts is useful to the surgeon as the latter require exploration of the facet joint for complete excision.<sup>8,10,15,18</sup>

The best diagnostic clue for the synovial cysts is the presence of posterolateral extradural cystic mass communicating with facet joint that shows varying degrees of arthropathy.<sup>1</sup> In our patient, the ligamentum flavum cyst was hyper intense in T2-weighted MRI images and hypointense in T1-weighted MRI images, and there was no communication with the adjacent facet joint.

Conservative treatment usually shows no success and mostly prescribed as a temporary measure. Surgical excision of the cyst and ligamentum flavum is the first-choice therapy aiming for spinal decompression and excisional biopsy of the cyst and affected ligamentum flavum.<sup>9,10</sup> Complete excision of the ligamentum flavum till its insertion of the cyst assures a minimal rate of recurrence.<sup>5,16</sup> Wildi et al,<sup>19</sup> reported recurrence of the cyst in the remaining ligamentum in two patients within 1 year. While nearly 95% of all operated cysts can be entirely removed, dural adhesions are the major cause of incomplete operative excision.<sup>6</sup> Complete removal of pseudocystic lesions generally has excellent results.<sup>2,5,6,8,16,17,18,19</sup> Our patient showed complete postoperative resolution



of symptoms. She is neurologically intact and symptoms free with 1 year follow up.

## Conclusion

Ligamentum flavum cyst should be put in mind when reading the MRI. Complete surgical excision should be carried meticulously.

## References

1. Apostolaki E, Davies AM, Evans N, Cassar-Pullicino VN: MR imaging of lumbar facet joint synovial cysts. *Eur Radiol* 10 (4):615-623,2000
2. Asamoto S, Jimbo H, Funkui Y, Doi H, Sakgawa H, Ida M, Takahashi M, Shiraishi N: Cyst of the ligamentum flavum—case report. *Neurol Med Chir (Tokyo)* 45(12):653–656,2005
3. Baum JA, Hanley EN: JR Intraspinial synovial cyst simulating spinal stenosis: A case report. *Spine* 11:487,1986
4. Chan L, Lui C, Cheng M, Lin J: Ganglion cyst in the ligamentum flavum of the cervicothoracic junction. *J Formos Med Assoc* 95:490–492,1996
5. Desai AA, Trivedi A, Chandraker BL, Kadam R: Report of a rare case: ligamentum flavum cyst. *MGM J Med Sci* 2(4):208-212, 2015
6. DiMario S, Marmor E, Albrecht S, Mohr G: Ligamentum flavum cysts causing incapacitating lumbar spinal stenosis. *Can J Neurol Sci* 32:237–242,2005
7. Fukuyama S, Nakamura T, Ikeda T, Takagi K: The effect of mechanical stress on hypertrophy of the lumbar ligamentum flavum. *J Spinal Disord* 8:126–130,1995
8. Gazzeri R, Galarza M, Gorgoglione L, Bisceglia M, D’Angelo V: Cervical cyst of the ligamentum flavum and C7-T1 subluxation: case report. *Eur Spine J* 14:807–809,2005
9. Haase J: Extradural cyst of the ligamentum flavum L4: a case. *Acta Orthop Scand* 43:32–38,1972
10. Mahallati H, Wallace K, Hunter M, Bilbao J, Clark A: MR imaging of a hemorrhagic and granulomatous cyst of the ligamentum flavum with pathologic correlation. *AJNR* 20:1166–1168,1999
11. Ogawa Y, Kumano K, Hirabayashi S, Aota Y: A ganglion cyst in the lumbar spinal canal: a case report. *Spine* 17 (11): 1429-1431,1992
12. Okada A, Harata S, Takeda Y, Nakamura T, Takagaki K, Endo M: Age-related change in proteoglycans of human ligamentum flavum. *Spine* 18:2261–2266,1993
13. Onofrio BM, Mih AD: Synovial cysts of the spine. *Neurosurgery* 22(4): 642-647, 1988
14. Roche PH, Figarella-Branger D, Malca S, Bouvier C, Soumare O, Pellet W: Lumbar canal stenosis caused by amyloidosis of the yellow ligament. *Neurochirurgi* 45:91–97,1999
15. Savitz MH, Sachdev VP: Cyst of the ligamentum flavum: report of six cases. *Neurosurgery* 30:461–462,1992
16. Seo DH, Park HR, Oh JS, Doh JW: Ligamentum Flavum Cyst of Lumbar Spine: A Case Report and Literature Review. *Korean J Spine* 11(1):18-21, 2014
17. Takano Y, Homma T, Okumura H, Takahashi HE: Ganglion cyst occurring in the ligamentum flavum of the cervical spine. A case report. *Spine* 17:1532–1533,1992
18. Terada H, Yokoyama Y, Kamata N, Hozumi T, Kondo T: Cyst of the ligamentum flavum. *Neuroradiology* 43:49–51, 2001
19. Wildi LM, Kurrer MO, Benini A, Weishaupt D, Michel BA, Brühlmann P: Pseudocystic degeneration of the lumbar ligamentum flavum. A little known entity. *J Spinal Disord Tech* 17:395–400,2004

Address reprint  
request to:

Tarek A A Abotakia, MD  
Orthopaedic Department, Faculty of Medicine, Minia University, Egypt  
E-mail: tarekabdallaahmed@gmail.com

## الملخص العربي

### تكيس الاربطة الصفراء بالفقرات القطنية: تقرير حالة

**البيانات الخلفية:** تكيس الاربطة الصفراء بالفقرات نادر الحدوث، ويعتقد ان تكون نتيجة لعملية الانحلال بالفقرات، وازالة التكيس بالكامل يؤدي الى نتائج ممتازة.

**الغرض:** على مستوى العالم تم تسجيل حالات قليلة و لم تسجل اى حالة بالمرضى المصريين من قبل.

### تصميم الدراسة: تقرير حالة

**المرضى والطرق:** وقد سجلنا حدوث حالة تكيس بالاربطة الصفراء ما بين الفقرتين الرابعة والخامسة القطنية بامرأة مصرية تبلغ من العمر ٤٥ عاما وتم ازالة التكيس بالكامل وبدقة ودون حدوث تمزق سحائي او تسرب للسائل الدماغي. وبعمل فحص الانسجة تبين وجود انحلال مخاطى بالاربطة الصفراء وعدم وجود خلايا زلائية.

**النتائج:** تحسنت المريضة وزالت كل الاعراض بالكامل مع متابعة لمدة عام

**الاستنتاج:** ينبغي وضع تكيس الاربطة الصفراء فى الحسبان عند قراءة اشعة الرنين المغناطيسي، والازالة الجراحية الكاملة ينبغي ان تكون بدقة .