

# Saving Ligamentum Flavum in One Day Care Microscopic Lumbar Disc Surgery

Mohamed F Khattab,<sup>\*</sup>Ayman E Galhom,<sup>\*\*</sup>Ahmed Elsawaf.<sup>\*\*\*</sup>

*Orthopedic Department,<sup>\*</sup> Ain shams Medical school, Ain Shams University, Cairo, Neurosurgery Departments, Faculty of Medicine, Port Said University,<sup>\*\*</sup> Port Said, Suez canal University,<sup>\*\*\*</sup> Ismailia, Egypt.*

## Abstract

**Background Data** Decompression discectomy is a common procedure for treatment of sciatica caused by lumbar disc herniation. Conventional discectomy may damage many important motion segment structures. Microscopic lumbar disc surgery can offer better visualization, magnification and illumination that lead to less invasive disc surgery. Shorter hospital stay, rapid recovery, and decrease the surgical cost is a trend to broaden the types of procedures that can be safely performed as one day care procedure.

**Purpose:** To assess the safety and efficacy of microscopic lumbar discectomy with partial ligamentum flavum preservation in treating L5-S1 lumbar disc herniation as outpatient procedure in one day care hospital.

**Study design:** Prospective clinical case study.

**Patients and Methods:** Between the period of 2012 and 2015 seventy cases were treated for prolapsed L5-S1 disc after failure of conservative treatment. All patients were operated by microscopic lumbar discectomy with partial preservation of the ligamentum flavum as outpatient one day surgery. Visual analogue scale (VAS), Oswestry Disability Index (ODI), and patient satisfaction questionnaire were used to assess the safety and efficacy of our procedure. Preoperative and postoperative MRI was done to confirm ligamentum flavum preservation.

**Results:** At the last follow up, VAS improved from  $7.29 \pm 0.89$  to  $1.8 \pm 0.93$  with P value  $P < 0.002$ . ODI was improved from  $42.01 \pm 6.77$  to  $13.4 \pm 4.72$  with P value  $P < 0.002$ . One cases had pseudomeningocele treated conservatively; three patients suffered paresthesia improved with medical conservative

**Received on:**

January 3<sup>rd</sup>, 2017

**Accepted on:**

November 23<sup>rd</sup>, 2017

treatment. Two patients had limited postoperative superficial infections. Recurrence of lumbar disc herniation was reported in one case 1.5 years after surgery.

**Conclusion:** According to the result, one day microscopic L5-S1 lumbar discectomy with partial ligamentum flavum preservation is possible with favorable clinical outcomes. (2017ESJ132)

**Keywords:** Microscopic, lumbar discectomy, one day care, ligamentum flavum

## Introduction

Persistent sciatic pain caused by lumbar disc prolapse (LDP) with failed conservative treatment is effectively treated surgically. The goal of the surgical procedure is to retrieve the herniated disc fragments and to decompress the nerve root with least surgical morbidity. In 1934 Mixter and Barr report the first disc surgery laminectomy with transdural disc removal was done. Later on, various less invasive techniques have been developed. Yasargil and Caspar used the microscope to refine the original laminectomy into the open microdiscectomy.<sup>4,13,20</sup>

Conventional decompressive discectomy surgery entails soft tissue dissection removing a part from the lamina and ligamentum Flavum excision. Thus, a conventional procedure may carry a risk for postoperative hematoma formation, fibrosis, postoperative pain and increases morbidity.

Since 1977 microscopic lumbar discectomy (MLD) progressed to be the gold standard technique for symptomatic lumbar disc prolapsed (LDP). It is a minimally invasive option with better visualization of normal and pathological tissues and minimizing iatrogenic collateral surgical damage.<sup>4</sup>

Microscopic lumbar discectomy is a common surgical procedure, it is safe and effective, and it can be done in outpatient clinic bases. One daycare surgery has decreased total surgery cost and more accepted by the patient.<sup>11</sup> In 1985 the first outpatient Microscopic lumbar discectomy was done.<sup>21</sup> Many studies prove the

feasibility and safety of outpatient MLD.<sup>9,17,21</sup> Microscopic L5-S1 interlaminar discectomy approach was refined by HM Mayer.<sup>12</sup>

The L5-S1 interlaminar approach requires ligamentum Flavum cutting or splitting. The ligamentum flavum has an important role in preventing postoperative scar tissue formation, decrease adhesions and maintain motion segment stability.<sup>1,14</sup>

The purpose of this study was to introduce the concept of outpatient microscopic L5-S1 Lumbar discectomy in one-day hospital in the Egyptian health care system. It is focusing on the technique safety and efficacy to properly decompress the nerve root at the index level by removing only the pathological compressing disc while keeping the integrity of the ligamentum flavum and paravertebral muscle.

## Patients and Methods

Between the period of 2012 and 2015 seventy patients, 38 males and 32 females with mean age was  $43.49 \pm 13.6$  (Range 16-66). All patients were treated for prolapsed symptomatic L5-S1 disc after a failure of conservative treatment for at least 6 weeks. All patients underwent sequestrectomy or fragmentectomy by the aid of microscope with partial preservation of the ligamentum flavum as an outpatient procedure in one day care hospital.

Inclusion criteria were including; patient with unilateral radiculopathy due to L5-S1 posterolateral disc herniation failed conservative treatment for at least 6 weeks, stable spine in a dynamic plain x-ray, and matching of clinical

examination and magnetic resonance imaging (MRI) results

Our exclusion criteria were including; patient with an infection, tumors, spine instability, history of trauma, patients with spinal canal stenosis, multiple disc herniations, bilateral involvement, calcified lumbar disc, and recurrent disc herniation. Patients with abnormal bleeding profile or comorbidities necessitate intensive care unit or longer hospital admissions were also excluded.

#### **Surgical Technique:**

The surgeries were done under general anesthesia after prone positioning image intensifier was used to L5-S1 level identification (Figure 1-A), microscopic aided L5-S1 discectomy was done from the side of patient complaint. A 2-3cm small midline incision was made. Subperiosteal muscle dissection to expose L5-S1 interlaminar window was done. Casper retractor was fixed then level confirmation by image intensifier before splitting the ligament flavum. (Figure 1-B)

The L5-S1 segment characterized by a wider interlaminar window and horizontally oriented ligamentum flavum. Using a dissector, longitudinal split in the ligamentum flavum was done (Figure 2-A,B) then by 2mm Kerrison rongeur we cut a small part of the ligamentum flavum and widen the opening until S1 nerve root can be identified and safely retracted by microscopic root retractor. Sequestrectomy or fragmentectomy was performed by the aid of disc hook and 2 mm disc punch forceps. (Figure 2-A)

After sequestrectomy of fragmentectomy, we used to irrigate by saline inside the disc to get rid of any loose fragment, then after proper root decompression, the annulus is coagulated by bipolar cautery to decrease the annular fissure size. Subsequently, the Casper retractor

was retrieved. Hemostasis was done by bipolar cautery and irrigation of the field by saline, no suction drain was used and tight wound closure was done.

Postoperatively single dose intravenous antibiotic, antiemetic, proton pump inhibitor and paracetamol vial was given. Before discharge on the same day, the patient needs to be vitally stable, pass urine normally. The patient needs to be examined for better limb sensation and lower limb strength than pre-operatively, patients asked if they have acceptable pain scores, and be able to mobilize freely. Visual analog scale (leg VAS, scored 1–10) and Oswestry disability index (ODI) are the tools to assess the clinical outcome during follow up.

Radiological assessment was done by doing control MRI two weeks after index surgery to assess the decompression and ligamentum flavum preservation. MRI was examined by the spine surgeons. (Figure 3)

Statistical analysis was performed using SPSS version 20.0 (SPSS, Chicago, IL, USA). Parametric data were analyzed using chi-square. Clinical outcome was analyzed using paired sample T-test. P values less than 0.05 were considered statistically significant.

## **Results**

In this clinical study 70 patients met our inclusion criteria. Thirty eight males and thirty two females patients with mean age  $43.49 \pm 13.59$  (Range 16-66) with mean follow-up period  $12 \pm 5$  months (Range 7-26). All patients complained of sciatica, and 32.9% have associated insignificant discogenic back pain. Associated surgical comorbidities, diabetes alone or associated with hypertension was presented in 17.1%. Smoking was presented in 14.3%. All patients complain were improved after surgery and maintained till the last follow up. (Table 1)

Operative time 38±12 minutes, intraoperative blood loss 25±8 CC. Intraoperative surgery was uneventful and the patients had smooth immediate postoperative period was discharged as an outpatient procedure.

Fifty eight years old male patient, 3 weeks post surgery, he complained of wound cystic swelling. Cerebrospinal fluid cystic swelling was diagnosed, This patient treated conservatively by fluids, analgesics and carbonic anhydrase inhibitor and the cyst resolved after 6weeks. Three cases with mild paresthesia and numbness at S1 distribution improved with medical conservative treatment. We have two postoperative superficial wound infections; one patient with poorly controlled diabetic, and the other one was a diabetic and heavy smoker. Recurrence of lumbar disc herniation was reported in one case, 1.5 years after surgery. No patient needs readmission within 24 hours of the index surgery. (Table 1)

Radiologically we compared preoperative MRI and Two weeks postoperative MRI. We had complete fragmentectomy with nerve root decompression in all patients. We were able to preserve most of the ligamentum flavum in all patients. (Figure 3)

VAS (leg) improved from 7.29±0.89 to 2.07±1.02 immediately after surgery then decreased to 1.8±0.93 after one year follow up, P value P<0.001, and P<0.002 respectively. ODI was improved from 42.01±6.77 to 15.2±4.61 immediately after surgery, and after one year follows up, it improved to 13.4±4.72. P value was statistically significant with stationary P value P<0.002, and P<0.002 respectively. (Table 2)

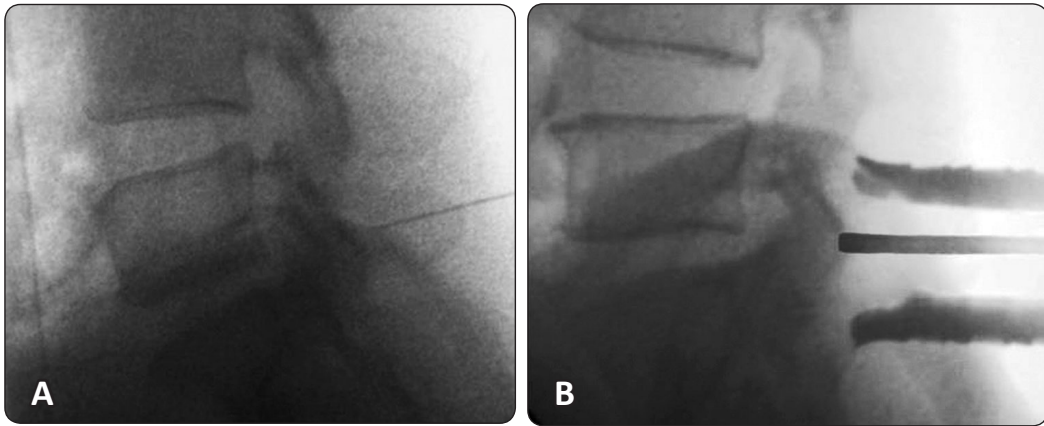
There was no significant correlation between the confounding factors like age, clinical presentation, associated comorbidities, and complication that affected the outcome. However, most complicated cases had associated medical comorbidities.

**Table 1.** Study Demographic Data

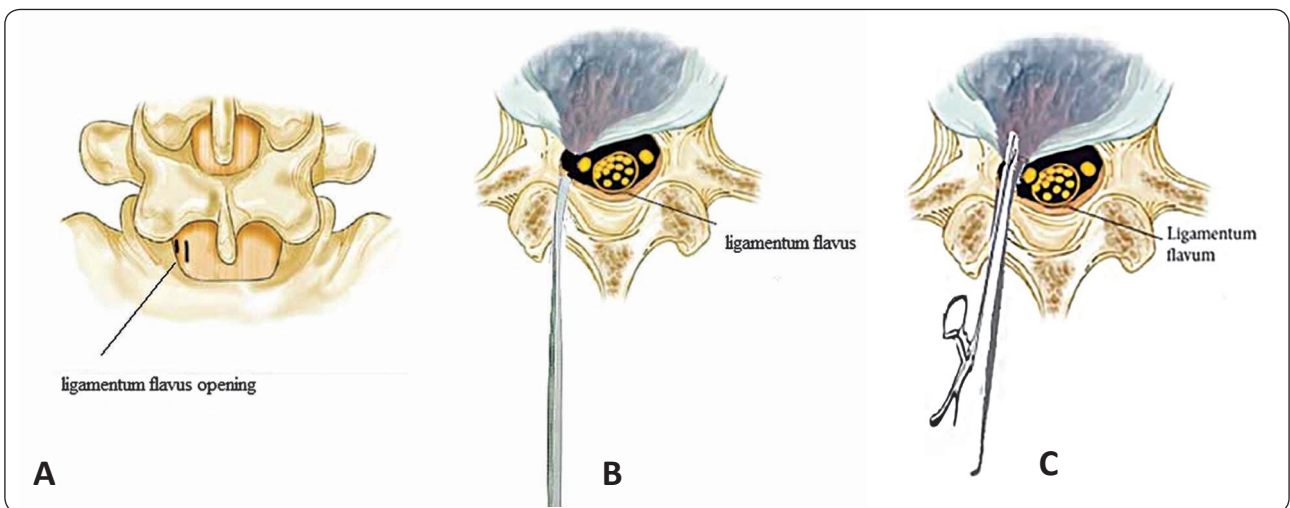
Variables		Frequency	%
Age		43.49±13.6	
Gender	Male	38	47.1
	Female	32	52.9
	Total	70	100
Complaint			
	Sciatica	47	67.1
	Sciatica/ Back pain	23	32.9
	Total	70	100
Comorbidities	Hypertension	6	8.6
	Diabetes	7	10.0
	Both	5	7.1
	Smoking	10	14.3
	Total	28	40.0
Complication	CSF leakage	1	1.4
	Superficial infection	2	2.9
	Recurrent disc	1	1.4
	Paresthesia along S1	3	4.2
	Total	7	10

**Table 2.** Univariate Analysis of Paired Sample t-test for the Surgical Outcome after Microscopic L5-S1 Discectomy

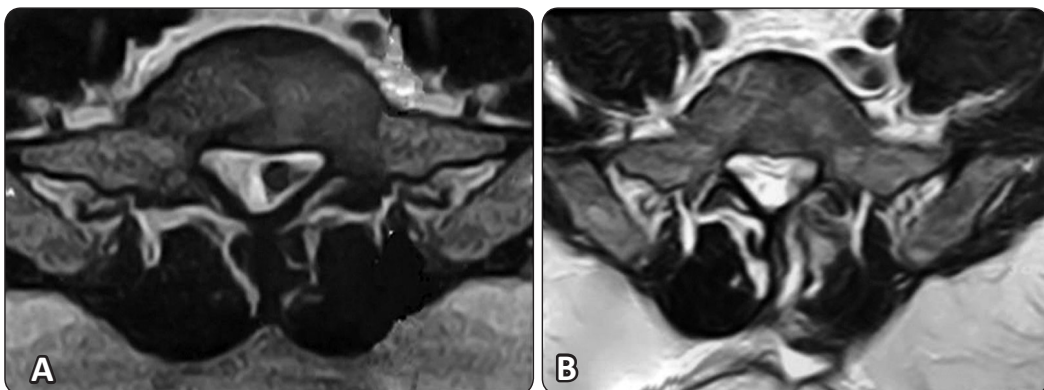
Surgical Outcome	Mean ±SD	P value
VAS Pre-operative	7.29±0.89	
VAS Immediate Postoperative	2.07±1.02	P<0.001
VAS One year after Surgery	1.8±0.93	P<0.002
ODI Pre-operative	42.01±6.77	
ODI Immediate Postoperative	15.2±4.61	P<0.002
ODI One Year after Surgery	13.4±4.72	P<0.002



**Figure 1.** (A) L5-S1 level identification by image intensifier before skin incision done. (B) Level confirmation before splitting the ligamentum flavum and Casper retractor fixed in place.



**Figure 2.** (A) explore the ligament flavum and identification of the part to be excised. (B) Dissection and splitting of the ligament with dissector and removal of the part of the ligament that overly the root. (C) Removal of the disc by rongeur and retraction of the root while preserving the rest of the ligamentum flavum.



**Figure 3.** (A) Preoperative T2 axial MRI cut with the extruded and sequestered disc. (B) Postoperative T2 axial MRI cut shows sequestrectomy and ligamentum flavum preservation.



## Discussion

Conventional open lumbar discectomy is indicated for patients with significant radicular pain after failure of conservative treatment. Minimally invasive procedures are attractive as it reduces the hospital stay with satisfactory clinical outcomes and rapid reintegration in the community. It reduces the collateral iatrogenic damage to paravertebral muscles, ligaments, and facet joint with less scarring, adhesions and iatrogenic postoperative instability.<sup>1,14,19</sup>

Surgeries performed in ambulatory surgery centers can reduce the cost and result in a more satisfactory experience for patients and surgeons. Because of the documented safety for a variety of procedures; there is a trend to broaden the types of procedures that can be safely performed as one-day care procedure. Postoperatively patients will be discharged within 24 hours, it is imperative to evaluate the risk of all potential complications of the proposed surgery, evaluate the resources available at the one day care unit, and take seriously patient comorbidities before scheduling a surgery as outpatient procedure.<sup>11</sup>

The role of one daycare surgery hospitals in health care is important. Patient selection especially associated comorbidities may play a role in a comparison between outpatient cases and inpatient cases. Poor home family care may be a limitation of the outpatient surgical procedure (OPC). Some microscopic lumbar discectomy may be performed as one-day care procedure.<sup>9</sup> Longer hospital stays depending on patient risk factors and presence of intraoperative incident should be an option.<sup>6</sup>

Although safety and efficacy of MLD as a day-case procedure is well established, with no reported differences in clinical outcomes or complications when compared to patients

requiring inpatient admission.<sup>7</sup> Although it is not statistically significant, all the complication reported in the study were related to patient associated co-morbidities rather than the technique. Not all microscopic discectomy patients should be forced to have one day care procedure.

In our clinical case series, we focused on patients with symptomatic L5-S1 disc prolapsed after a failure of conservative management and fulfill our inclusion criteria. We operate them as outpatient (one day) cases that are mean zero night stay in one-day surgery hospital with satisfactory outcomes. Singhal et al,<sup>17</sup> stated that 116 patients completed an outpatient protocol, with six patients needing an admission from the day surgery unit, two with dural tears and four with anesthetic side effects. There were no readmissions following discharge in 95.1% of patients. In this study, we have no readmission. All complications are managed in the outpatient clinic. Recurrent discs needed surgery 1.5 year after surgery.

Fragmentectomy or sequestrectomy was compared with conventional open wide discectomy by many authors. The results were favorable for fragmentectomy or sequestrectomy as it shows less operative time, less intraoperative complication, less postoperative degeneration at the index level with no significant difference in recurrence rate of the pathology.<sup>2,3,6,8,16</sup> One of the important merits of the microscope is its ability to better visualization, illumination, and magnification of tissues so we can differentiate easily between structures.<sup>12</sup>

Flavectomy has been incriminated as a cause of postoperative epidural scarring and pain. For this reason surgeons tried to decrease scar tissue formation by different methods. In open surgery, some surgeons used to apply epidural

fat graft or antiadhesive agents,<sup>5,15</sup> where other shifted to full endoscopic approach.<sup>18</sup>

Different techniques used to manage the ligamentum flavum as removing it totally from proximal to distal attachment and from medial to lateral but this technique carry a risk of more postoperative scarring. Other technique by cutting the ligamentum flavum laminar and facetal attachment by microscopic scalpel like a door after removal of the superficial layer (open door flavectomy).<sup>12</sup>

We believe in the preserving the ligamentum flavum and its splitting by dissector over the epidural space. The nerve root S1 was properly exposed and retracted medially to aid the decompressive discectomy procedure. Splitting and removing of a small segment of the ligamentum flavum help to create enough corridors for root decompression, and maintain the motion segment integrity as possible. This technique decreases the incidence of postoperative scar tissue formation and pain. So it is enough to have safe efficient corridor by our technique for L5-S1 decompressive disc surgery

Recurrence was defined as cases of disc herniation at the same level after a pain-free postoperative interval. In this clinical study, we have one recurrent disc that occurred one and half year later managed by redo discectomy. She was an overweight female. Such confounding factors affect recurrence rate.<sup>3</sup> We believe that, soft tissue dissection technique and in the way of removing any loose fragments by intradiscal saline irrigation help to reduce the rate of lumbar disc recurrence.

It is proposed that sealing of the annular defect by bipolar radiofrequency can be effective in reducing recurrence rates.<sup>10</sup> In this study, we used to coagulate the redundant annulus aiming to stretch it and reduce defect size after complete decompression.

Although this study helps to improve the spine health care and save bed space in hospitals it has some limitations; it is not a randomized control study with no long-term follow up and no cost-effectiveness analysis was done. Not all the risk factors that affect surgery (i.e. overweight, type of work) are studied in details.

## Conclusion

L5-S1 microscopic lumbar discectomy with partial ligamentum flavum preservation can be done safely as outpatient (one day care) procedure with proper patient selection and proper analysis of preoperative investigations. It alleviate operative trauma and facilitate postoperative rapid integration of the patient in the community.

## References

1. Aydin Y, Ziyal IM, Duman H, Türkmen CS, Başak M, Sahin Y: Clinical and radiological results of lumbar microdiscectomy technique with preserving of ligamentum flavum comparing to the standard microdiscectomy technique. *Surg Neurol* 57(1):5-13, 2002
2. Barth M, Diepers M, Weiss C, Thomé C: Two-year outcome after lumbar microdiscectomy versus microscopic sequestrectomy: part 2: radiographic evaluation and correlation with clinical outcome. *Spine* 33(3): 273–279, 2008
3. Barth M, Weiss C, Thomé C: Two-year outcome after lumbar microdiscectomy versus microscopic sequestrectomy: part 1: evaluation of clinical outcome. *Spine (Phila Pa 1976)*33(3):265-72, 2008
4. Caspar W: A new surgical procedure for lumbar disk herniation causing less tissue damage through a microsurgical approach. *Adv Neurosurg* 4:74-77, 1977

5. Cooper RG, Mitchell WS, Illingworth KJ, Forbes WS, Gillespie JE, Jayson MI: The role of epidural fibrosis and defective fibrinolysis in the persistence of postlaminectomy back pain. *Spine (Phila Pa 1976)* 16(9):1044-8, 1991
6. Fakouri B, Patel V, Bayley E, Srinivas S: Lumbar microdiscectomy versus sequestrectomy/ free fragmentectomy: a long-term (>2 y) retrospective study of the clinical outcome. *J Spinal Disord Tech* 24(1):6-10, 2011
7. Gonzalez-Castro A, Shetty A, Nagendar K, Greenough C: Day case conventional discectomy: a randomized controlled trial. *Eur Spine J* 11(1):67-70, 2002
8. Kast E, Oberle J, Richter HP, Börm W: Success of simple sequestrectomy in lumbar spine surgery depends on the competence of the fibrous ring a prospective controlled study of 168 patients. *Spine (Phila Pa 1976)* 33(14):1567-71, 2008
9. Kelly A, Griffith H, Jamjoom A: Results of day-case surgery for lumbar disc prolapse. *Br J Neurosurg* 8(1):47-9, 1994
10. Kim HS, Park JY: Comparative assessment of different percutaneous endoscopic interlaminar lumbar discectomy (PEID) techniques. *Pain Physician* 16(4):359-67, 2013
11. Kurd MF, Schroeder GD, Vaccaro AR: Spine surgery in an ambulatory setting: what can be done safely? *J BJS Rev* 19;3(5), 2015
12. Mayer H M: minimally invasive spine surgery 2nd ed., the paramedian interlaminar approach Mayer HM springer Verlag, berlin hydelbergnewyork 2006 page 283-296
13. Mixter WJ, Barr JS: Rupture of the intervertebral disc with involvement of the spinal canal. *N Engl J Med* 211:210-215, 1934
14. Ozer AF, Oktenoglu T, Sasani M, Bozkus H, Canbulat N, Karaarslan E, et al: Preserving the ligamentum flavum in lumbar discectomy: a new technique that prevents scar tissue formation in the first 6 months postsurgery. *Neurosurgery* 59(1 Suppl 1):126-33, 2006
15. Ross JS, Robertson JT, Frederickson RC, Petrie JL, Obuchowski N, Modic MT, et al: Association between peridural scar and recurrent radicular pain after lumbar discectomy: magnetic resonance evaluation. *ADCONL European Study Group. Neurosurgery* 38(4):855-61, 1996
16. Schick U, Elhabony R: Prospective comparative study of lumbar sequestrectomy and microdiscectomy. *Minim Invasive Neurosurgery* 52(4):180-5, 2009
17. Singhal A, Bernstein M: Outpatient lumbar microdiscectomy: a prospective study in 122 patients. *Can J Neurol Sci* 29(3):249-52, 2002
18. Walid K Abouzeid, Tamer Hassan, Hesham AboRahma, Ahmed Azab: Full-endoscopic soft tissue approach for lumbar disc herniation. *Egy Spine J* 18:15-27, 2016
19. Williams RW: Microlumbar discectomy: a 12-year statistical review. *Spine (Phila Pa 1976)* 11(8):851-2, 1986
20. Yasargil MG: Microsurgical operation for herniated disc. *Adv Neurosurg* 81, 1977
21. Zahrawi F: Microlumbar discectomy. Is it safe as an outpatient procedure? *Spine* 19(9):1070-4, 1994

Address reprint  
request to:

**Mohamed F Khattab MD**

Orthopedic Department, Ain shams Medical school, Ain Shams University,  
Cairo, Egypt - Email: mohamedkhattab@gmail.com



## الملخص العربي

### الحفاظ الجزئي على الرباط فلافوم اثناء جراحة اليوم الواحد المجهرية للقرص القطني

**البيانات الخلفية:** تخفيف الضغط على الاعصاب باستئصال الغضروف القطني هو إجراء شائع لعلاج الام العصب الوركي الناجم عن فتق القرص القطني. ونظرا لمشاكل الجراحة التقليدية، فقد استخدم المجهر الجراحي منذ فترة في هذه الجراحة لما يتمتع به من وضوح الرؤيا والتكبير باقل تلف نسيجي جراحي ممكن. وتتميز الجراحة المجهرية بقصر فترة الإقامة بالمستشفى، والانتعاش السريع، وتقليل التكلفة الجراحية مما سمح لهذه التقنية الجراحية المفضلة كإجراء امن للجراحة وبقاء المريض لفترة وجيزة تصل الى يوم واحد بعد الجراحة.

**الغرض:** تقييم سلامة وفعالية الاستئصال المجهرى للقرص القطني مع الحفاظ الجزئي للرباط فلافوم في علاج فتق القرص القطني ما بين الفقرة القطنية الخامسة والعجزة الاولى كإجراء جراحي في مستشفى رعاية اليوم الواحد.

**تصميم الدراسة:** دراسة الحالة السريرية المحتملة.

**المرضي و الطرق:** بين عامي ٢٠١٢ و ٢٠١٥ تم علاج سبعين حالة من فتق القرص القطني ما بين الفقرة القطنية الخامسة والعجزة الاول بعد فشل العلاج التحفظي، عن طريق استئصال القرص القطني بواسطة المجهر الجراحي مع الحفاظ الجزئي على الرباط فلافوم كجراحة بالعيادات الخارجية ذات اليوم واحد. يتم استخدام مقياس التناظرية البصرية (فاس) ومؤشر العجز أوسويستري (أودي)، لاستبيان رضا المرضى ولتقييم سلامة وفعالية الإجراء الجراحي. تم إجراء التصوير بالرنين المغناطيسي قبل الجراحة وبعدها للتأكد على الحفاظ على الرباط فلافوم.

**النتائج:** تم تخفيض مقياس الالم ف ا س (من  $7,29 \pm 0,89$  إلى  $1,8 \pm 0,93$ ) بعد سنة واحدة من الجراحي وكانت قيمة  $p < 0,002$  ذات دلالة احصائية. وتحسن مقياس أو دي لحالة المريض السريرية من  $42,01 \pm 6,77$  إلى  $13,4 \pm 4,72$  وكانت قيمة بايضا ذات دلالة إحصائية  $p < 0,002$ . تم علاج حالة من تسرب للسائل النخاعي وثلاث حالات عولجوا من تنميل على مسار العصب العجزي واحد. كما عانى اثنان من المرضى من حدوث عدوى سطحية محدودة بالجرح بعد الجراحة، وتكرر معاودة فتق القرص القطني في حالة واحدة بعد عام ونصف من الجراحة.

**الاستنتاج:** وفقا للنتيجة، وجد ان استئصال القرص القطني بواسطة المجهر الجراحي مع الحفاظ الجزئي على الرباط فلافوم كجراحة يوم واحد هو ممكن مع نتائج سريرية جيدة وذات دلالة إحصائية.