

Surgical Treatment of Metastatic Lesions at the Cervicothoracic Spinal Junction

Tariq Elemam Awad, MD., Salem Salman Faisal, MD.

Neurosurgery Department, Faculty of Medicine, Suez Canal University, Ismailia, Egypt.

Abstract

Background Data: Metastatic spine disease continues to be an increasing burden. The cervicothoracic junction represents a transition from the semi rigid thoracic spine to the mobile sub axial cervical spine. Pathologic lesions are prone to result in kyphotic deformity as well as to the possibility of neurological deficits.

Purpose: The aim of this study is to review our experience with surgical stabilization of metastatic lesions affecting the cervicothoracic junction (C7-T2).

Study Design: A descriptive analytic cross section retrospective study involving 12 patients.

Patients and Methods: The authors retrospectively reviewed their archive between February 2011 and July 2016, and twelve patients who were operated upon due to cervicothoracic junction metastasis were included. All patients underwent surgical treatment by either anterior corpectomy and fixation or posterior decompression and stabilization utilizing tapered rods. The patients were periodically followed up.

Results: A total of twelve patients were included in this study including six males and six females. They had their primary in the breast in five patients, in the lung in three patients, in the prostate in two patients, and fro adenocarcinoma in two patients. The anterior approach was used in nine patients while the posterior approach was used in three patients. There was clinical improvement in neurological status according to Frankel grades of paraplegia in eleven of the twelve patients. There was no loss of correction in any patient of the study group.

Conclusion: Patients with cervicothoracic metastatic lesions can be treated with either anterior or posterior approaches after considering each individual's potential instability and disease burden. (2017ESJ135)

Keywords: Cervicothoracic spine, instability, metastases

Received on:

June 9th, 2017

Accepted on:

September 20th, 2017

Introduction

It is estimated that among living cancer patients, 10% experience symptomatic secondary metastases. The most common reported sites of distant metastases are liver, lungs, and skeleton. Within the skeleton, the spinal column has the highest incidence of metastasis. On autopsy studies, as many as 90% of cancer patients suffered spinal metastasis.^{4,7}

Metastatic spine disease continues to be an increasing burden on health systems. This is a result of improved oncologic treatments and their associated prolonged life expectancy coupled with the growing expectations that patients have. Metastatic disease to the spine with resultant pain from instability is estimated to affect 10% of individuals with cancer.⁵

A majority of metastatic disease affects the lumbar and thoracic spine where the total volume of bone is greater while the cervical spine is less often affected. The cervicothoracic junction (CTJ), defined as C7-T2 is only occasionally involved but represents an area prone to instability as the spine transitions from the mobile cervical spine to the more rigid thoracic.^{6,9} The significance of a junction lesion in metastatic disease is reflected in the increased allocation of points in spinal instability. Neoplasia Score where junction metastatic lesions are more likely to be recommended for surgical stabilization. Indeed, the spine instability neoplastic score (SINS) details C7-T2 inclusive as the junction cervicothoracic level.⁶

Despite the biomechanical significance of the cervicothoracic junction, little is reported in the literature regarding the treatment and outcome of metastatic disease affecting this area.^{3,10} The aim of this study is to report our experience in the surgical management of metastatic disease affecting the cervicothoracic junction.

Patients and Methods

This is a retrospective study carried out between February 2011 and July 2016, at the Department of Neurosurgery, Suez Canal University Hospitals,

Ismailia, Egypt. A total of twelve consecutive patients were followed clinically and radiologically after surgery.

Inclusion criteria required all patients to have metastasis in the cervicothoracic spine which is the area between 7th cervical vertebra and 2nd thoracic vertebra. The patients underwent a detailed history, clinical examination, and were investigated with plain radiographs, magnetic resonance imaging, and computed tomography (CT) scan of the entire spine. Added to, the work up for metastasis was conducted to find the primary tumor and degree of body metastasis. The patients' neurological functions were classified according to Frankel grades of paraplegia.⁸

Surgical Procedure:

The choice of the surgical approach depends on the 3 Dimensions location of the pathologic process and the resultant deformity encountered. Surgical approaches to the cervicothoracic junction used in this series were either of these two categories: anterior trans-cervical approach (supraclavicular), or posterior approach (laminectomy, transpedicular).

The key point in deciding on surgical approach here was whether or not the vertebral body was sufficiently destructed to warrant corpectomy and stabilization using a cage or whether posterior decompression and instrumentation was needed.

Anterior Trans-cervical Approach (N=9):

Patients were positioned supine with the head turned slightly to the side contralateral to the approach. An incision was made above the clavicle along the sternocleidomastoid extending to the midpoint of the sternal body. This incision may also be modified depending on the patient's specific anatomy and pathology. The platysma muscle was divided and mobilized. The sternocleidomastoid muscle was identified and the carotid pulse was checked. The trachea and the esophagus were retracted medially and the carotid was retracted laterally. The longus colli muscles and midline were identified. Corpectomy was done as required. Anterior cervicothoracic fixation was done with cervical plate fixation.

Posterior Approach (N=3):

The patients were operated using midline posterior skin incision and subperiosteal retraction of para spinal muscles to expose the affected segment. Decompression of the spinal cord was done as required and biopsy was obtained. Cervical lateral mass screws (3.5mm) were inserted. C7 lateral masses or pedicle screws were used according to every patient's anatomical suitability. Transpedicular screws were used in the upper thoracic vertebrae needed. All patients underwent a posterior instrumented fusion. The screws were connected by dual-diameter rods (tapered rods) which taper up from 3.5mm diameter to accommodate the cervical screws to a diameter of 5.5mm for the thoracic screws.

For both approaches, duration of surgery, blood loss, and the duration of inpatient treatment were recorded. Intraoperative and perioperative major and minor complications were assessed.

The patients were periodically followed up at the hospital outpatient clinic for a detailed neurological examination. The patients underwent routine plain radiographic examination at follow-up visits and MRI spine at 6 months interval.

After surgical intervention all patient were followed in the oncology department to complete medical treatment either radiotherapy and and/or chemotherapy according to the primary tumor type.

Results

A total of twelve patients were reported in this study including six males and six females. The detailed data of the study group are presented in (Table 1). The mean age of patients reported in this study was 55±15 years (Range, 32-75 years). According to Frankel grading score; we have 2 patients grade A, 7 patients grade C, 2 patients grade D, and one patients grade E.

Reported mean operative time in this study was 239±49 minutes (Range, 177-295 minutes). Mean

blood loss was 600±420 CC (Range, 500-1400 CC). Mean Hospital stay was 5±3.9 days (Range, 3-11 days).

Over all we reported twelve patients with cervicothoracic metastasis. They had their primary pathology in the breast in five patients, in the lung in three patients and in the prostate in two patients. The other two patients had adenocarcinoma. The anterior approach with corpectomy and anterior plate fixation was used in nine patients. The posterior approach with decompression and stabilization with cervical lateral mass screws and dorsal pedicle screws fixation was used in three patients.

Mean follow up was 12 ± 6 months (Range, 3-24 months). There was a clinical improvement in neurological status according to Frankel grades of paraplegia in eleven of the twelve patients (Table 1). The 12th patient had grade A preoperatively and showed no improvement in the post-operative follow up.

There were no intraoperative morbidity; nevertheless infection was the main postoperative complications reported in our study. Two patients showed superficial wound infection in the anterior group patients which improved by daily dressings and medical treatment. Two patients in the posterior approach patients showed deep wound infections in the form of progressive swelling and pain at site surgery. These patients had exploration of the wound and debridement. Surgical drain was inserted deeply in the wound and left for ten days to drain. Intravenous antibiotic were given according to culture and sensitivity. Both patients respond will to conservative measures without implant removal.

On the basis of the clinical assessment, radiographs, and CT scans, there was no implant failure at final follow up. There was no loss of correction gained operatively in any of our patient.

The 2 lung cancer metastasis patients died 3 and 4 months postoperatively during the follow up period due to hepatorenal failure secondary to wide systemic metastasis.

Table 1. Patient Characteristics and Clinical Findings in the Study Series

Patient No	Age/ Sex	Diagnosis	Surgery	Levels Fixed	Morbidity	PreOp Frankel	PostOp Frankel
1	70/M	C7-T1 spinal epidural prostate Mets	Posterior laminectomy & instrumented fusion	C5-T3	Deep Wound infection + debridement	C	D
2	56/F	T1 lung Mets collapse	Anterior corpectomy & fixation	C7-T2	-	C	E
3	53//F	C7-T1, breast Mets with collapse and compression	Anterior corpectomy & fixation	C5-T2	-	C	E
4	38/F	C7-T1 breast Mets with collapse and compression	Anterior corpectomy & fixation	C5-T2	Superficial wound infection	A	B
5	70/ M	C7 body lesion adenocarcinoma Mets	Anterior corpectomy & fixation	C6-T1	-	D	E
6	45/F	C7-T1 breast Mets	Anterior corpectomy & fixation	C6-T2	-	C	D
7	47/M	C7 lung Mets collapse	Anterior corpectomy & fixation	C6-T1	-	C	B
8	50/F	T1 breast Mets	Anterior corpectomy & fixation	C7-T2	-	E	E
9	59/M	C7 lung Mets collapse	Anterior corpectomy & fixation	C6-T2	Superficial wound infection	C	D
10	62/M	T1 body lesion adenocarcinoma Mets	Anterior corpectomy & fixation	C7-T2	-	D	E
11	75/M	C7-T1 spinal epidural prostate Mets	Posterior laminectomy & instrumented fusion	C4-T3		C	D
12	32/F	T1-T2 breast Mets	Posterior laminectomy & spinal fixation	C6-T4	Deep Wound infection + debridement	A	A

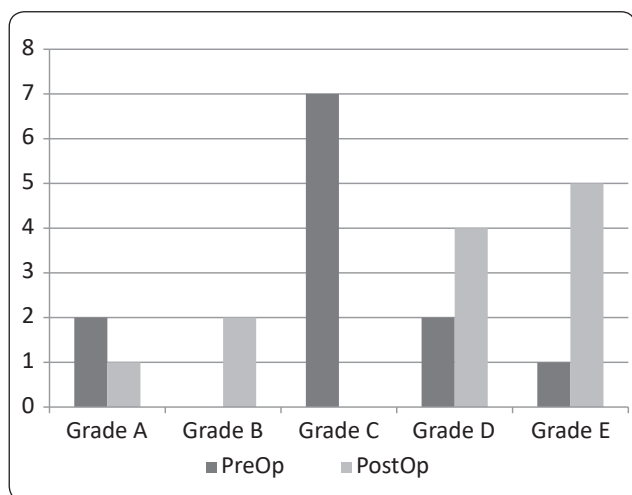


Figure 1. Pre& Post-Operative patients' distribution according to Frankel Grading Score

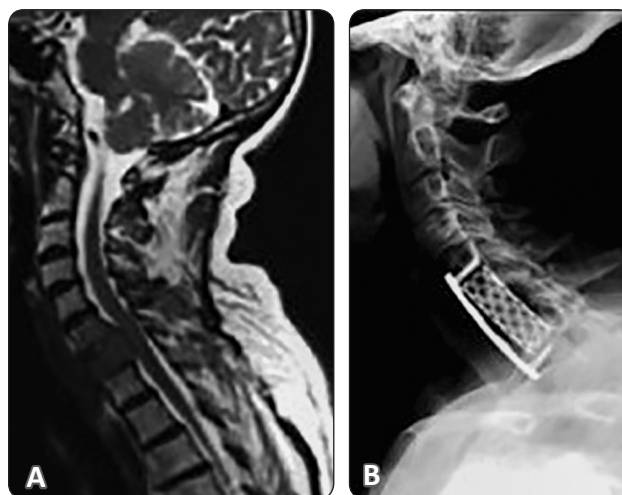


Figure 2. (A) MRI cervicodorsal spine T2 weighted image in a patient with metastatic breast disease and lysis of C7. (B) plain X-ray after reconstruction with titanium mesh and anterior plate fixation of the cervicodorsal spine.

Discussion

We have reviewed our results of surgical stabilization of metastatic lesions affecting the cervicothoracic junction. This junction level is prone to catastrophic failure given its propensity to collapse into kyphosis when instability ensues.¹⁰ Due to these biomechanical peculiarities the cervicothoracic junction attracts interest.⁶ Instability at this level can lead to a kyphotic deformity putting the spinal cord at risk of compression with devastating consequences for patients already hampered physiologically from an oncologic disease burden.^{1,10}

Most of the cohort reviewed presented with incomplete myelopathy with a smaller proportion complaining of significant pain suggesting obvious instability. This is perhaps fortunate as it allowed surgical intervention before further neurologic deterioration. A majority of patients presented with higher Frankel grade and there were no deteriorations in this series as a result of surgery.

Previously, Mazel et al,¹⁰ reported on 32 patients of tumor involving the cervicothoracic junction. Nineteen of the 32 patients underwent anterior stabilization, typically as a result of vertebrectomy, in addition to posterior stabilization using a variety of systems – two plates systems and one-rod system. They found no screw or plate failure but had two construct failures due to too short a posterior segment being stabilized and one anterior column reconstruction being insufficient. In all our patients, top-loading rod systems were used for posterior instrumentation. We found no failure in our series in twelve patients. It has previously been shown that a posterior system provides greater stiffness than an anterior plate only system.

Metcalfe et al,¹¹ have previously reported a series of 50 patients undergoing circumferential decompression and stabilization using a transpedicular approach. In their series, they had three patients, two at T1 and one at T2, in whom this approach was effective. One benefit of this over a strategy of approaching via separate incisions through the front and the back is the avoidance either of a staged procedure or having to reposition. In all anterior approaches in our series a corpectomy

was planned for and supplemental fixation used with a plate rendering the construct stiffer in most patients. Titanium mesh cages with bone cement were used for anterior column reconstruction in this current series. Previous reports on reconstruction for spinal metastases have good results with polymethylmethacrylate cement as a reconstructive option although there are reports including catastrophic dislodgement of the construct.²

Whether to approach from the front, back or both is a decision made on a case-by-case basis both considering the instability, disease process and patient physiology and anatomy.

The survivorship of those patients with lung tumors was very disappointing with a survivorship from the time of surgical intervention no greater than 4 months. This poor survivorship is not surprising and has been noted elsewhere in the literature. Poor survival after spinal surgery for lung metastases previously reported by Weiss and Wedin.^{12,13} Those with breast disease fared significantly better giving a true reflection of the value of the intervention in those with metastatic spinal disease from breast cancer. A relative strength in this study is the selection of true metastatic disease. Other series have included multiple myeloma, a disease some argue is more hematologic in nature and one that has a nature tendency toward greater survivorship. In only two patients was the diagnosis unknown at the time of spine surgery (Patients number 5,10). The decision to operate in this patient was in part influenced by the need for tissue sampling and nature of perceived instability.

In summary, this series of cervicothoracic metastatic lesions treated with surgical decompression and stabilization shows satisfying results. There were no long-term implant failures recorded or neurologic complications as a result of surgery.

Conclusion

Patients with cervicothoracic spinal metastatic lesions can be treated safely and effectively with either anterior or posterior approaches after considering each individual's potential instability and disease burden.

References

1. Abdelbaky A, Eltahawy H: Neurological Outcome Following Surgical Treatment of Spinal Metastases. *Egyptian Spine Journal*; 12:21-26, 2014
2. Akeyson EW, McCutcheon IE: Single-stage posterior vertebrectomy and replacement combined with posterior instrumentation for spinal metastasis. *J Neurosurg* 85:211–20, 1996
3. Amer M: Percutaneous Vertebroplasty for Osteolytic Spinal Lesion: A Pilot Study. *Egyptian Spine Journal* 8:26-33, 2013
4. Balain B, Jaiswal A, Trivedi JM, Eisenstein SM, Kuiper JH, Jaffray DC: The Oswestry risk index: An aid in the treatment of metastatic disease of the spine. *Bone Joint J* 95-B:210–6, 2013
5. DeWald RL, Bridwell KH, Prodromas C, Rodts MF: Reconstructive spinal surgery as palliation for metastatic malignancies of the spine. *Spine (Phila Pa 1976)* 10:21–6, 1985
6. Fisher CG, DiPaola CP, Ryken TC, Bilsky MH, Shaffrey CI, Berven SH, et al: A novel classification system for spinal instability in neoplastic disease: An evidence-based approach and expert consensus from the spine oncology study group. *Spine (Phila Pa 1976)* 35:E1221–9, 2010
7. Fleming C, Baker JF, O'Neill SC, Rowan FE, Byrne DP, Synnott K: The Oswestry spinal risk index (OSRI): An external validation study. *Eur Spine J* 25:252–256, 2016
8. Franel HL, Hancock DO, Hyslop G, Mezlak J, Michaelis L S, Ungar G H, Vernon JD S, Walsh JJ: The value of postural reduction in the initial management of closed injuries of the spine with paraplegia and tetraplegia. I. *Paraplegia* 7:179–192, 1969.
9. Ivanishvili Z, Fourny DR: incorporating the spine instability neoplastic score into a treatment strategy for spinal metastasis: LMNOP. *Global Spine J* 4:129–36, 2014
10. Mazel C, Hoffmann E, Antonietti P, Grunenwald D, Henry M, Williams J: Posterior cervicothoracic instrumentation in spine tumors. *Spine (Phila Pa 1976)* 29:1246–53, 2004
11. Metcalfe S, Gbejuade H, Patel NR: The posterior transpedicular approach for circumferential decompression and instrumented stabilization with titanium cage vertebrectomy reconstruction for spinal tumors: Consecutive case series of 50 patients. *Spine (Phila Pa 1976)* 37:1375–83, 2012
12. Tokuhashi Y, Uei H, Oshima M, Ajiro Y: Scoring system for prediction of metastatic spine tumor prognosis. *World J Orthop* 5:262–71, 2014
13. Weiss RJ, Wedin R: Surgery for skeletal metastases in lung cancer. *Acta Orthop* 82:96–101, 2011

Address reprint
request to:

Tariq Elemam Awad, MD.

Department of Neurological Surgery, School of Medicine, Suez Canal University Hospital, Ismailia, Egypt 15213. - Email: Tariqelemam@yahoo.com

الملخص العربي

العلاج الجراحي في الأورام الثانوية في التقاء الفقرات العنقية الصدرية

البيانات الخلفية: يمثل منطقه التقاء الفقرات العنقية الصدرية منطقه انتقاله من العمود الفقري الصدري الثابت وبين الفقرات العنقية المتحركة. والإصابات في هذه المنطقة من الممكن أن تعرض الفقرات للإصابة بالانحناء والتقوس بالإضافة إلى الإصابات العصبية المحتملة

الغرض: توضيح النتائج الجراحية وإظهار خبرات الباحثين في العلاج الجراحي للأورام الثانوية في منطقة التقاء الفقرات العنقية الصدرية

تصميم الدراسة: دراسة لحالات أكلينيكية على 12 مريض بالغ يعانون من أورام ثانوية في منطقة التقاء الفقرات العنقية الصدرية.

المرضي والطرق: تم إجراء الجراحات من 2011 إلى 2016. تم متابعة الأعراض والعلامات وملاحظة النتائج الأكلينيكية. تم إجراء الجراحات إما عن طريق التوجه الأمامي مع التثبيت بشريحة أو التوجه الخلفي مع التثبيت بالشرائح والمسامير .

النتائج: تم إجراء الجراحات في 12 مريض . تم استخدام التوجه الأمامي في 9 مرضى والتوجه الخلفي في 3 مرضى. كان مصدر الورم الأولي من الثدي في 5 مرضى ومن الرئة في 3 مرضى ومن البروستاتا في مريضين. أظهر 11 مريض تحسن في الوظائف الحركية بعد الجراحة وحافظ جميع المرضى على استقرار العمود الفقري بعد الجراحة

الاستنتاج: العلاج الجراحي في الأورام الثانوية في التقاء الفقرات العنقية الصدرية يمكن أن يتم عن طريق التوجه الأمامي أو الخلفي حسب كل حاله ومدى ثبات وانحناء العمود الفقري.