

The Effect of Cigarette Smoking and Vitamin D Status on Fusion Rates after Posterior Lumbar Interbody Fusion Surgery: Does Sound Radiological Fusion Correlates with Better Clinical Outcomes?

Marwan Ali, MD., Alaa El-Naggar, MD., Amr Elwany, MD., Mohamed Abdel-Bary, MD.

Neurosurgery Department, Faculty of Medicine, Alexandria University, Alexandria, Egypt.

ABSTRACT

Background Data: Lumbar interbody fusion surgeries are the gold standard surgical option in degenerative disc disorders and spondylolisthesis. Achieving solid arthrodesis at the operated segment remains the main goal of surgery. Yet, the correlation of sound radiological fusion with better clinical outcomes is not well established. In recent years, spinal surgeons had much greater awareness of the influence of vitamin D deficiency and cigarette smoking on spinal fusion.

Purpose: To assess the influence of vitamin D deficiency and cigarette smoking on the rate of spinal arthrodesis after posterior lumbar interbody fusion (PLIF) in degenerative disc disorders and whether successful fusion correlates with clinical outcomes.

Study Design: A prospective cohort study.

Patients and Methods: The study was conducted on 67 patients (with a total of 92 levels) who underwent operation for PLIF with pedicle screw fixation. Twenty-six patients had degenerative spondylolisthesis, 20 had herniated discs, and 21 patients showed degenerative disc changes with segmental canal stenosis. In 29 patients, a local bone graft was used as soft PLIF. In the remaining 38 patients, a PEEK interbody cage was utilized. Patients were categorized according to both their serum vitamin D status (39 low; 28 normal) and cigarette smoking habits (18 smokers; 49 non-smokers). The final assessment was done 6 months postoperatively. Clinical outcomes were measured by the Oswestry Disability Index (ODI) and Visual Analogue Scale (VAS) for low back pain. Radiological fusion status was assessed on plain radiographs and graded according to Bridwell's interbody fusion grading system. The relationship between vitamin D status and cigarette smoking and radiological outcomes was also evaluated.

Results: Twenty-two males and 45 females were included in this study. The mean age was 55.8 ± 3.78 years. L4-L5 was the most commonly operated level, followed by L5-S1 and L3-4 (51.1%, 36.95%,

Address correspondence and reprint requests: Marwan Ali, M.D.
Neurosurgery Department, Faculty of Medicine, Alexandria University, Alexandria, Egypt.
Email: marwanali_ma@hotmail.com

Submitted: September 3rd, 2019.
Accepted: September 30th, 2019.
Published: October, 2019.

The article does not contain information about medical device(s)/drug(s).
No funds were received in support of this work.
The authors report no conflict of interest.

and 11.95%, resp.). There were significant improvements in the mean ODI and VAS measures at final assessment regardless of the differences in vitamin D status or smoking habits. The fusion rate in the low vitamin D group was 79.5% versus 96.4% in the normal level group ($P=0.045$). 66.7% of those with poor radiological fusion were smokers versus 20.7% of those with sound fusion ($P=0.004$). There was no significant difference in fusion rates between the PEEK cage group and the bone graft group ($P=0.128$). There was no significant correlation between sound radiological fusion and better clinical outcomes ($P=0.077$ and $P=0.157$ for ODI and VAS, resp.).

Conclusion: Smoking habits and low serum vitamin D seem to have a significant negative effect on the success of radiological spinal fusion. There was no significant relationship between radiological fusion and clinical outcomes. (2019ESJ190)

Keywords: Posterior lumbar interbody fusion, Degenerative disc disease, Vitamin D, Cigarette smoking, Radiological outcomes

INTRODUCTION

It is estimated that about 77% of the population will present with low back pain at least once during their lifetime.²² Intervertebral disc degeneration can be held accountable in most of these cases. A variety of conditions that arise secondary to the process of disc degeneration, collectively called degenerative disc disorders (DDD), can contribute to the patient's complaint. These include the development of lumbar canal stenosis, degenerative spondylolisthesis, facets arthropathies, and the so-called "black disc".^{1,47} Although most patients can be initially managed conservatively, surgical intervention is still indicated in those in which conservative measures fail or those who develop severe or progressive symptoms.

Interbody fusion surgeries remain the most popular surgical option for most of these cases, and their use has dramatically increased worldwide over the last two decades. The rationale behind fusion procedures is to achieve solid arthrodesis at the affected segment, thus eliminating any segmental instability. However, contradicting evidence exists regarding the relationship between sound radiological fusion and better clinical outcomes.¹³ In addition, studies assessing the factors that may influence the success of arthrodesis are still lacking or inconclusive.

Therefore, in our study, we aimed to assess the influence of some factors, theoretically thought

to affect the normal bone metabolism, such as vitamin D status of the individual, and cigarette smoking on spinal fusion after PLIF surgery. In addition, we aimed to demonstrate whether there is a correlation between successful radiological fusion and better clinical outcomes.

MATERIALS & METHODS

We prospectively enrolled 67 patients with symptomatic degenerative disc disorders, admitted to our institute in the period between May 2017 and May 2018. Patients suffering from one or two levels of degenerative spondylolisthesis, degenerative disc disease, or degenerative stenosis and having progressive neurological symptoms, persistent incapacitating pain interfering with normal daily activities and not improving despite at least 3 months of nonoperative treatment were recruited in this study. Patients with high-grade spondylolisthesis, osteoporosis and those with other pathologies (e.g., infection, fractures) were excluded.

Twenty-six patients (38.8%) had degenerative spondylolisthesis, 20 (29.9%) had degenerated herniated discs, and the remaining 21 patients (31.3%) showed degenerative segmental stenosis. All patients underwent operation for posterior lumbar interbody fusion (PLIF) with pedicle screw fixation and were scheduled for a follow-up visit, 6 months postoperatively for final assessment. 38

patients had a PEEK cage inserted between the vertebral bodies, with a total of 52 operated levels (25 with single level, 12 with double levels, and 1 with triple levels). The remaining 29 patients had only local bone graft inserted in the interbody space with a total of 40 operated levels (18 patients with single level and 11 with double level).

The degrees of pain and disability were assessed by the Oswestry Disability Index (ODI: 0%–100%)^{18,20} and a Visual Analogue Scale for low back pain (VAS: 0–10). Both measures were obtained preoperatively as a baseline and once at the final follow-up, 6 months postoperatively.

Preoperative radiological evaluation included MRI of the lumbosacral spine, as well as anteroposterior, lateral neutral, and dynamic plain radiographs. The final postoperative radiological assessment of fusion was done on anteroposterior and lateral plain radiographs. Fusion status was categorized according to Bridwell's classification of interbody fusion.⁷ Bridwell's grades I and II were considered as having sound fusion, while grades III and IV were considered incomplete or no fusion.

Moreover, patients were categorized according to their vitamin D status (39 patients with low serum vitamin D versus 28 with normal levels), represented by the serum level of 25(OH)D obtained at final follow-up. The cut-off value for serum 25(OH)D as set by the American Endocrine Society was 30 ng/mL.²⁶ Levels below that figure were considered low (deficient or insufficient), while levels above that figure were considered to be normal. The demographic data of both groups was comparable (Table 6). The mean age in both groups was similar. 42.9% of patients with normal levels had degenerative spondylolisthesis, 25% had disc herniation, and 32.1% had segmental stenosis, compared to 35.9%, 33.3%, and 30.8%, respectively, in the low-level group. 53.6% of patients with normal vitamin D levels had a PEEK cage inserted versus 59% in those with low levels. Patients were also categorized according to their cigarette smoking habits into smokers, who smoked at least 10 cigarettes (1/2 a pack)

per day, for at least 6 months, and non-smokers (18 smokers versus 49 non-smokers). Again, the patients' demographic data was comparable in both groups (Table 6). 44.4% of the smoker group had degenerative spondylolisthesis, 27.8% had disc herniation, and 27.8% had segmental canal stenosis, compared to 36.7%, 30.6%, and 32.7%, resp., in the non-smoker group. 50% of the smoker group and 59.2% of the non-smoker group had a PEEK cage inserted.

The potential influences of both smoking and vitamin D status on the clinical and radiological outcomes were also assessed at final follow-up using the Chi-Square test of independence.

Surgical Technique

Patients underwent operation through the standard posterior approach with a midline posterior incision and subperiosteal dissection of the paraspinal muscles to expose the affected segment. This was followed by adequate decompression of the spinal canal with removal of the spinous process, interspinous ligament, lamina, hypertrophic ligamentum flavum, and medial parts of the facet joints. Foraminotomy and nerve root decompression were routinely done. Pedicle screws were inserted under fluoroscopy guidance. The intervertebral disc was then entered after securing the thecal sac and nerve root medially and inferiorly using nerve retractors. Radical discectomy with end-plate preparation was done using a combination of standard disc rongeurs, disc shavers, and curettes. In all patients, rods of desired length were contoured to the appropriate lordotic curve and were applied over the pedicle screws. An appropriate degree of distraction was applied across the disc space and a local bone graft obtained from the removed posterior arch elements (i.e., spinous process, lamina, and facets), and a PEEK cage, when used, was placed and impacted into the disc space for interbody fusion. After that, the previously applied distraction was released so that the graft is well impacted in the disc space. A drainage catheter was then inserted after proper hemostasis. Fascial, subcutaneous, and skin layers were then closed in a layer-by-layer fashion.

RESULTS

Our series included 45 females and 22 males, with a mean age of 55.81 ± 3.78 years (range, 46–65). L4-L5 level was by far the most commonly operated level, followed by L5-S1 and L3-4 levels (51.1%, 36.95%, and 11.95%, resp.). Descriptive data of the studied patients is summarized in Table 1.

There were significant improvements in the clinical outcome measures at final follow-up at 6 months. The mean ODI improved from 54.84 ± 8.07 preoperatively to 22.93 ± 3.99 at final follow-up ($P < 0.001$), while mean VAS scores improved from 7.55 ± 1.02 preoperatively to 2.27 ± 0.89 at the final postoperative follow-up ($P < 0.001$). 58 of our patients (86.6%) were considered to have satisfactory radiological fusion (Bridwell's grades 1 and 2), while only 9 patients (13.4%) had incomplete or no fusion (Bridwell's grades 3 and 4) at final postoperative assessment.

In our study, we found that both smoking and vitamin D status significantly influenced the success of radiological fusion. Cigarette smoking was also found to have a significant negative effect on the fusion process, with 33.33% of the smokers ($N=6$) showing incomplete or no fusion, compared to a nonfusion rate of only 6.12% ($N=3$) among non-smokers ($P=0.004$). Similarly, 20.51% of the patients ($N=8$) with low serum vitamin D had incomplete radiological fusion on final follow-up, compared to only 3.57% ($N=1$) of those who had normal levels. The difference in radiological fusion rates between the 2 groups was found to be statistically significant ($P=0.045$). However, neither vitamin D status nor cigarette smoking habits had a statistically significant effect on clinical outcomes measures (i.e., ODI and VAS). Moreover, we could not find a significant correlation between sound radiological fusion and better clinical outcomes. Patients who achieved sound radiological fusion at final follow-up ($N=58$) had mean ODI and VAS of 25.59 ± 3.89 and 2.18 ± 0.87 , respectively, while those with unsatisfactory radiological fusion ($N=9$) had mean ODI and VAS of 25.11 ± 4.14 and 3.17 ± 0.75 , respectively. No statistically significant relationship could be found between radiological fusion and either measure at final follow-up ($P=0.077$ and 0.157 for ODI and VAS, resp.).

Table 1. Demographic data of the study patients.

Parameters	Number	%	
Age	45-	6	9%
	50-	12	17.9%
	55-	40	59.7%
	60-	9	13.4%
	Mean (range)	55.81 ± 3.78 (46–65)	
Gender	Male	22	38.8%
	Female	45	67.2%
Smoking	Yes	18	26.9%
	No	49	73.1%
Vitamin D	Normal	28	41.8%
	Low	39	58.2%
Interbody graft	Local bone graft only	29	43.3%
	PEEK cage	38	56.7%
Levels operated	L5-S1	34	36.96%
	L4-L5	47	51.09%
	L3-L4	11	11.96%
Pathology	Degenerative spondylolisthesis	26	38.8%
	Degenerative disc herniation	20	29.9%
	Degenerative segmental stenosis	21	31.3%
Fusion status	Fusion (Bridwell's 1&2)	58	86.6%
	No fusion (Bridwell's 3&4)	9	13.4%

Table 2. Clinical outcome measures at different studied periods.

Parameter	Preoperatively	6 months postoperatively
ODI	54.84 ± 8.069	22.93 ± 3.990
<i>P</i> -value	$< 0.001^*$	
VAS (back pain)	7.55 ± 1.019	2.27 ± 0.898
<i>P</i> -value	$< 0.001^*$	

Table 3. Relationship of different studied parameters with the final clinical outcome.

Parameters		Postoperative ODI	Postoperative VAS
Fusion status	Fusion	25.586±3.893	2.180±0.866
	No fusion	25.111±4.137	3.167±0.753
	<i>P-value</i>	0.077	0.157
Interbody graft	Local bone graft	24.207±3.519	2.483±0.986
	PEEK Cage	21.947±4.093	2.105±0.798
	<i>P-value</i>	0.020*	0.101
Vitamin D status	Normal	23.143±4.437	2.429±0.959
	Low	22.769±3.688	2.154±0.844
	<i>P-value</i>	0.708	0.289
Smoking	Smoker	23.889±4.626	2.333±1.085
	Non-smoker	22.571±3.719	2.245±0.830
	<i>P-value</i>	0.234	0.793

Table 4. Relationship between different variables and the radiological outcome.

Variable		Bridwell's grade				Chi-square	P
		Fusion (N=58)		No fusion (N=9)			
		No.	%	No.	%		
Group	Bone chip	23	39.7%	6	66.7%	2.316	0.128
	Cage	35	60.3%	3	33.3%		
Gender	Female	40	67%	5	55.6%	0.635	0.425
	Male	18	33%	4	44.4%		
Smoking	Non-smoker	46	79.3%	3	33.3%	8.382	0.004*
	Smoker	12	20.7%	6	66.7%		
Vitamin D	Low	31	53.4%	8	88.9%	4.023	0.045*
	Normal	27	46.7%	1	11.1%		

Table 5. Relation between clinical outcome and radiological outcome.

Parameters		Final ODI	Final VAS
Fusion Status	Fusion	25.586±3.893	2.180±0.866
	No fusion	25.111±4.137	3.167 ± 0.753
<i>P-value</i>		t (P)=-1.796 (0.077)	z (P)=-1.416 (0.157)

Table 6. Demographic characteristics of vitamin D status and smoker subgroups.

Parameters		Vitamin D status		Smoking habits	
		Low	Smoker	Non-smoker	
Number		28	39	18	49
Age		55.9 (46–65)	56.03 (49–63)	57.1 (49–60)	54.8 (46–63)
Sex (F:M)		17:11	28:11	2:16	43:6
Pathology	Disc herniation	7 (25%)	13 (33.3%)	5 (27.8%)	15 (30.6%)
	Deg. spondylolisthesis	12 (42.9%)	14 (35.9%)	8 (44.4%)	18 (36.7%)
	Deg. disc/segmental stenosis	9 (32.1%)	12 (30.8%)	5 (27.8%)	16 (32.7%)
Levels operated (N=92)	L3-L4	4 (10.3%)	7 (13.2%)	1 (3.7%)	10 (15.4%)
	L4-L5	19 (48.7%)	28 (52.8%)	14 (51.9%)	33 (50.8%)
	L5-S1	16 (41%)	18 (34%)	12 (44.4%)	22 (33.8%)
Interbody graft	Artificial cage	15 (53.6%)	23 (59%)	9 (50%)	29 (59.2%)
	Bone graft	13 (46.4%)	16 (41%)	9 (50%)	20 (40.8%)

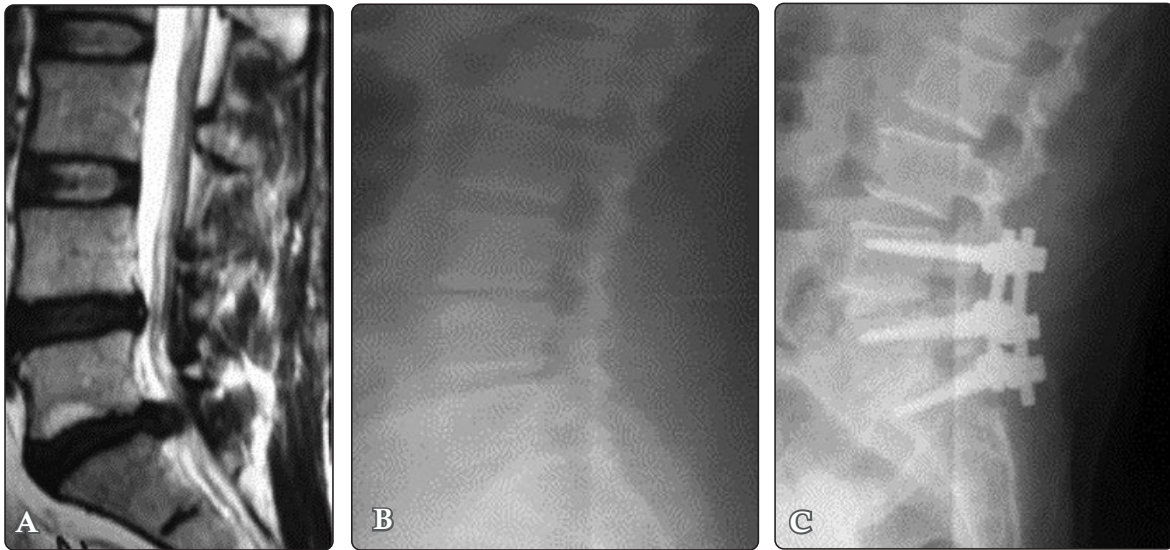


Figure 1. (A) T2WI sagittal MRI of a 57-year-old male patient showing degenerative changes in both L4/L5 and L5/S1 discs together with posterolateral L5-S1 disc herniation. ODI= 56; VAS= 8; smoking: yes; vitamin D status: low. (B) Lateral radiograph showing the L4/L5 and L5/S1 degenerative changes. (C) Six-month postoperative plain radiograph only local bone graft was used for both levels. Bone graft is seen bridging the disc space with lucency noted below the bone graft, indicating incomplete fusion (Bridwell's grade 3). ODI=24; VAS=3.

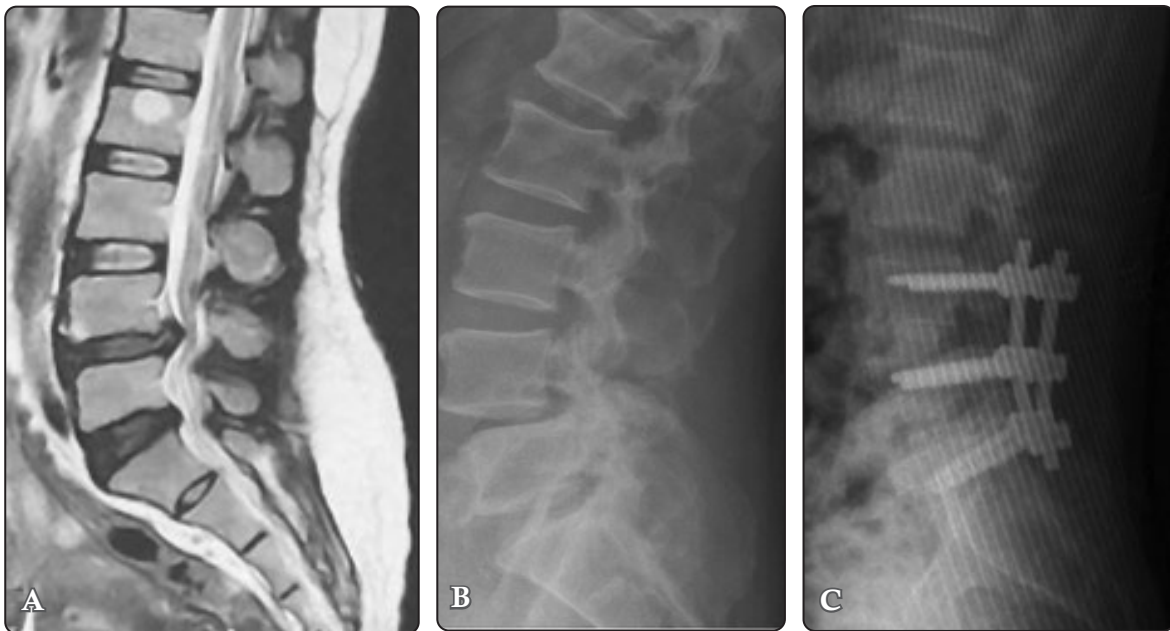

Figure 2. (A) T2WI sagittal MRI of a 50-year-old female with L4/L5 grade I degenerative spondylolisthesis and degenerative disc changes in L5-S1 disc. ODI= 52; VAS= 7; smoking: no; vitamin D status: normal. (B) Lateral radiograph showing the L4/L5 slip. (C) Six-month postoperative plain radiograph showing the bone graft well integrated and completely traversing the disc space with no lucencies (Bridwell's grade 1). ODI= 20; VAS= 2.

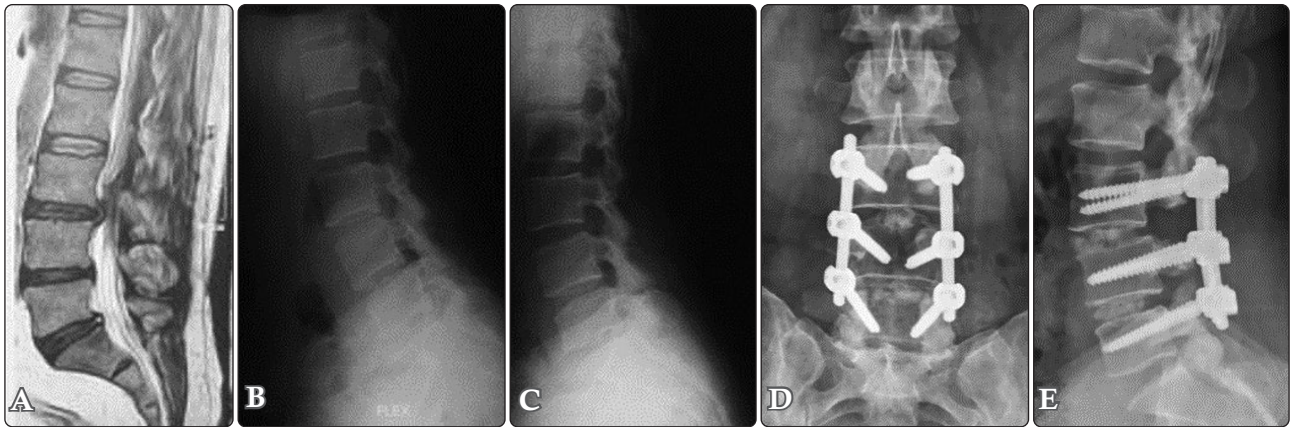


Figure 3. Images of a 47-year-old female patient, non-smoker, low vitamin D, ODI= 54, VAS= 6. (A) Sagittal T2 MRI showing degenerative disc changes at L3-L4, L4-L5 levels, and, to a lesser extent, L5-S1, with annular disc bulge and segmental canal stenosis at L3-L4 level. (B,C) Dynamic study showing minimal slip at L4/L5 segment. (D,E) Anteroposterior and lateral plain radiographs 6 months postoperatively, showing sound radiological fusion. Bone graft is seen well traversing the interbody space in both operated levels, yet the graft is not fully integrated with the vertebral bodies (Bridwell's grade 2).

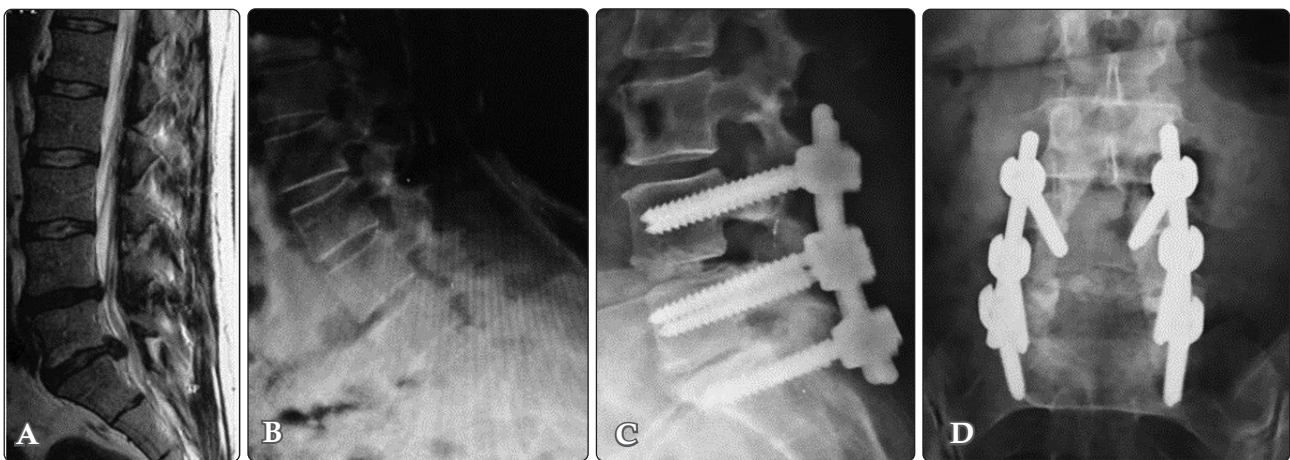


Figure 4. Images of a 52-year-old female patient, non-smoker, low vitamin D, ODI= 48, VAS= 8. (A) Sagittal T2 MRI showing with degenerative disc changes at L4-L5 and L5-S1 levels, with a disc herniation at L5-S1 level. (B) Dynamic study showing no instability. Postoperative plain radiographs 6 months postoperatively, (C) lateral view, and (D) anteroposterior view show bone graft seen in the L4-L5 space; however, lucency could be seen above and below the graft (Bridwell's grade 3); in the L5-S1 level, the bone graft cannot be readily seen, indicating bone graft resorption and complete failure of fusion (Bridwell's grade 4).

DISCUSSION

Lumbar degenerative disc disease is a common cause of low back pain and sciatica in adults.^{2,15,16,36} The process of degeneration starts with dehydration of the nucleus pulposus together with decreased tensile strength of the annulus fibrosus, leading eventually to decreased disc height, facets

hypertrophy and subluxation, and segmental instability of the affected segment.³⁷

In our institute, posterior lumbar interbody fusion (PLIF) procedure remains the most commonly used surgical option for treatment of degenerative disc disorders and spondylolisthesis. They have the advantage of providing immediate restoration of disc height, decompression of the nerve roots, and anterior column reinforcement.^{11,34} We most

commonly use the polyetheretherketone (PEEK) cage to support the bone graft. However, local bone grafts are sometimes used solely depending on the surgical preference of the operating surgeon, as well as the economic status of the patient.

However, our study has some limitations: first, different surgeons operated on the patients and thus some variations in surgical skills and techniques used could exist. Second, the postoperative follow-up period was 6 months, which is a relatively a short follow-up period compared to similar previous studies. Third, the assessment of fusion was not a straightforward task. Blumenthal and Gill⁶ stated that surgical re-exploration is the only reliable method to assess fusion but this was obviously impractical to be used in our study. Although computed tomography (CT) appears to be more accurate to assess fusion status than plain X-rays,⁹ we could not also include it in our study due to the high costs involved. Consequently, we used plain lateral radiographs for assessment of radiological outcomes.

In our study, patients seemed to have an improvement in their back pain despite using an artificial cage or only local bone graft. However, the cage group showed better functional outcomes as reflected by ODI scores. Various studies assessing the outcomes of interbody fusion procedures reported significant improvement in clinical outcomes measures at final follow-up. Hashimoto et al.²³ assessed the outcomes after single-level PLIF surgery using carbon cages and reported on average 83% improvement rate after a mean follow-up period of 31 months. Hioki et al.²⁵ assessed the outcome of double-level PLIF in patients with degenerative disc disorders and similarly reported significant improvement in functional status at final follow-up. In Sears et al.⁴¹ study assessing outcomes of PLIF surgery in degenerative spondylolisthesis, mean VAS improved from 5.3 ± 2.2 to 2.2 ± 2.1 after a mean follow-up period of 21.4 months, and 91% of his patients reported good or excellent results. Kim et al.²⁹ assessed the outcomes of PLIF surgery using a single interbody cage in degenerative lumbar

disorders. The patients reported an improvement in mean ODI score from 68.7 preoperatively to 37.9 and in VAS from 6.5 to 1.8 at final postoperative follow-up (average 31.1 months). In addition, Yu et al.⁵¹ reported that using an artificial cage resulted in better postoperative ODI scores compared to a bone graft alone. Meanwhile, various other studies failed to show a significant advantage in using an artificial cage on clinical outcomes, compared to bone graft alone.^{5,31,32}

Assessment of Fusion

For a solid spinal arthrodesis to be achieved, the graft material used should provide good osteoinductive, osteoblastic, and osteoconductive properties.³⁵ Using iliac bone graft provided excellent fusion rates, but was associated with significant donor site morbidity.⁴³ Posterior elements local bone graft is an alternative source of graft material to be used for interbody fusion. Nevertheless, when used alone, bone grafts may result in collapsed union and failure to maintain the corrected disc height.^{5,51} Therefore, the use of an artificial cage has the theoretical advantage of maintaining corrected disc height and lumbar lordosis and providing immediate anterior column load sharing, while also providing satisfactory radiological fusion rates.⁵¹ On the other hand, artificial cages have the disadvantage of reducing the available contact area for bony fusion³. Thus, we routinely add local bone graft anteriorly prior to cage insertion.

In our study, PLIF surgery resulted in excellent overall sound fusion rates (86.6%) at 6-month postoperative follow-up visit, regardless of whether an artificial cage was used or not. Several previous studies reported similarly excellent fusion rates. Csecsei et al.¹² reported fusion rates of 95.7% after a mean follow-up period of 27.3 months. Kai et al.²⁷ reported 92.9% fusion rates using local facet joint bones after a long-term follow-up of 8.5 years. Kim et al.²⁹ reported a 94.4% solid fusion rates at 6 months postoperatively using a single artificial cage in degenerative lumbar conditions. Zhao et al.⁵³ reported 92.6 % fusion rate using a single diagonal artificial cage at 1-year follow-up,

which increased to 100% 2 years postoperatively. In addition, some authors reported comparable fusion rates using artificial cage or bone graft alone after variable follow-up periods.^{31,32,51}

Correlation between Radiological Fusion and Clinical Outcome

One of the integral goals of spinal fusion surgeries is to achieve solid arthrodesis across the operated segment. It is thus expected that patients with solid fusion would report better functional outcome than those with incomplete fusion or pseudoarthrosis. However, data from previous studies shows contradicting results on whether there is actual correlation between radiological fusion and functional outcome. In our series, there was no significant correlation between sound radiological fusion and better clinical outcomes. Similar results were obtained by Thalgott et al.⁴⁵ in his series of patients undergoing anterior lumbar interbody fusion (ALIF). Penta and Fraser³⁸ also failed to find such correlation between successful fusion and superior functional outcome after a long-term follow-up (10 years). Epstein¹⁷ found no correlation between fusion and clinical outcome in her series of patients who underwent non-instrumented fusion surgeries.

On the other hand, other authors reported better clinical outcomes in patients with sound radiological arthrodesis. Christensen et al.¹⁰ published a prospective study on 148 patients who underwent posterolateral fusion (PLF) either with pedicle screws fixation alone or with anterior lumbar interbody fusion (ALIF) in addition. They found a significant positive relationship between radiological solid fusion and better functional outcome and quality of life. Kim et al.²⁹ randomized his patients to have either PLF alone or PLIF alone or both of them simultaneously. They reported 91% of patients with fusion had superior functional outcome compared with only 41% of those with nonunion. In another study by Wetzel and colleagues,⁴⁹ patients were evaluated for 2 years, and a positive correlation could be found between solid radiological fusion and better clinical outcomes. Zdeblick et al.⁵² similarly found

a positive relationship between fusion status and better clinical outcomes in a prospective study with a follow-up period of 1 year. Djurasovic et al.¹⁴ reported a 65% improvement in ODI in patients with solid fusion compared with 32% in non-fusion patients, and this difference was found to be significant.

Vitamin D Levels

Vitamin D plays an important role in maintaining adequate serum calcium and phosphorus levels by promoting intestinal absorption. It is also important for proper bone mineralization by promoting the process of bone remodeling via action on osteoblasts and osteoclasts.⁴⁴ Recent evidence suggests that vitamin D deficiency may be associated with less favorable surgical outcomes after spinal fusion procedures and increased risk of pseudoarthrosis.³⁹

Epidemiological studies showed a wider prevalence of vitamin D deficiency than initially thought. One study reported about 41.6% of the general American population was found to be vitamin D deficient.¹⁹ Another retrospective study of patients undergoing elective spinal surgeries reported that 27% of them had vitamin D deficiency and about 57% had insufficiency.⁴² These data suggest that vitamin D disorders may represent a modifiable risk factor that may affect the outcomes after spinal fusion surgeries.

As one would expect, vitamin D deficiency would thus affect the physiology of bone fusion after spinal surgeries. This was demonstrated in our series, where data analysis showed significantly better fusion rates in those with normal serum vitamin D levels compared to those with low serum levels. Yet again, variations in vitamin D status among patients were not reflected on their final clinical outcome measures. Such a relationship between vitamin D status and fusion rates was also demonstrated by some previous studies.^{39,50} Other studies also reported an influence of vitamin D status on clinical outcome measures. Ravindra et al.³⁹ found that patients with vitamin D deficiency showed significantly higher rates of nonunion and longer mean time to fusion when compared with

patients with normal levels. Xu et al.⁵⁰ showed that vitamin D supplementation in deficient patients resulted in better fusion rates and functional outcomes compared to the control group. Studies by Kim et al.³⁰ and Waikakul et al.⁴⁸ also reported worse clinical outcomes in patients with vitamin D deficiency after lumbar surgeries. On the other hand, Schofferman et al.⁴⁰ found no significant association between serum vitamin D level and rate of non-fusion after spinal fusion procedures.

Smoking

As for cigarette smoking, it was found to affect the local vasculature and thus the adequacy of blood supply to the fusion bed, as well as expression of genes coding for different cytokines that are important for proper vasculature and healing process in the fusion bed.^{28,47} Based on these findings, we included smoking as a variable that may affect the success of fusion after spinal surgeries. Data analysis showed that the rate of nonfusion among smokers was significantly higher than in non-smokers. Similar findings were reported by Glassman et al.²¹ in patients who underwent instrumented lumbar fusion surgery. In addition, patients who stopped smoking for more than 6 months showed an improvement in their fusion rates. Andersen et al.⁴ found that smoking more than 10 cigarettes per day affected spinal fusion rates negatively. Hermann et al.²⁴ showed a higher rate of reoperations for pseudoarthrosis among smokers as compared to non-smokers. On the other hand, a study by Luszczuk et al.³³ compared fusion rates after anterior cervical discectomy and fusion surgery among smokers and non-smokers and found no significant difference between the 2 groups regarding radiological fusion. Bydon et al.⁸ could only demonstrate a negative effect of smoking on fusion rates among patients undergoing double-level lumbar fusion but failed to show a similar effect in those undergoing single-level fusion surgeries.

CONCLUSION

Smoking habits and low serum vitamin D seem to have a significant negative effect on the success of radiological spinal fusion. There was no significant relationship between radiological fusion and clinical outcomes.

REFERENCES

1. Abbas M, Elwany A, Farag R: Efficacy and safety of using unilateral approach for bilateral neural decompression in lumbar spinal stenosis. *Egypt Spine J* 24:42-49, 2017
2. Abbas M, Elwany A, Mohamed R: Comparing the extent of tissue damage between lumbar Microendoscopic Discectomy (MED) and Microscopic Discectomy (MD) using biochemical markers. *Egypt Spine J* 26:25-33, 2018
3. Abdul Q, Qayum M, Saradhi M, Panigrahi M, Sreedhar V: Clinico-radiological profile of indirect neural decompression using cage or auto graft as interbody construct in posterior lumbar interbody fusion in spondylolisthesis: Which is better? *J Craniovertebr Junction Spine* 2:12, 2011
4. Andersen T, Christensen FB, Laursen M, Høy K, Hansen ES, Bünger C: Smoking as a predictor of negative outcome in lumbar spinal fusion. *Spine (Phila Pa 1976)* 26:2623-2628, 2001
5. Arai Y, Takahashi M, Kurosawa H, Shitoto K: Comparative study of iliac bone graft and carbon cage with local bone graft in posterior lumbar interbody fusion. *J Orthop Surg (Hong Kong)* 10:1-7, 2002
6. Blumenthal SL, Gill K: Can lumbar spine radiographs accurately determine fusion in postoperative patients? Correlation of

- routine radiographs with a second surgical look at lumbar fusions. *Spine (Phila Pa 1976)* 18:1186-1189, 1993
7. Bridwell KH, Lenke LG, McEnery KW, Baldus C, Blanke K: Anterior fresh frozen structural allografts in the thoracic and lumbar spine. Do they work if combined with posterior fusion and instrumentation in adult patients with kyphosis or anterior column defects? *Spine (Phila Pa 1976)* 20:1410-1418, 1995
 8. Bydon M, De la Garza-Ramos R, Abt NB, Gokaslan ZL, Wolinsky J-P, Sciubba DM, et al: Impact of smoking on complication and pseudarthrosis rates after single-and 2-level posterolateral fusion of the lumbar spine. *Spine (Phila Pa 1976)* 39:1765-1770, 2014
 9. Choudhri TF, Mummaneni PV, Dhall SS, Eck JC, Groff MW, Ghogawala Z, et al: Guideline update for the performance of fusion procedures for degenerative disease of the lumbar spine. Part 4: radiographic assessment of fusion status. *J Neurosurg Spine* 21:23-30, 2014
 10. Christensen F, Karlsmose B, Hansen E, Bünger C: Radiological and functional outcome after anterior lumbar interbody spinal fusion. *Eur Spine J* 5:293-298, 1996
 11. Cloward RB: The treatment of ruptured lumbar intervertebral discs by vertebral body fusion. I. Indications, operative technique, after care. *J Neurosurg* 10:154-168, 1953
 12. Csecsei G, Klekner A, Sikula J: Posterior lumbar interbody fusion (PLIF) using the bony elements of the dorsal spinal segment. *Acta Chir Hung* 36:54-56, 1997
 13. Dhall SS, Choudhri TF, Eck JC, Groff MW, Ghogawala Z, Watters WC, 3rd, et al: Guideline update for the performance of fusion procedures for degenerative disease of the lumbar spine. Part 5: correlation between radiographic outcome and function. *J Neurosurg Spine* 21:31-36, 2014
 14. Djurasovic M, Glassman SD, Dimar JR, Howard JM, Bratcher KR, Carreon LY: Does fusion status correlate with patient outcomes in lumbar spinal fusion? *Spine (Phila Pa 1976)* 36:404-409, 2011
 15. Elwany A, Farhoud A, Zidan I, Khedr W: Three-year follow-up results of lumbar Microendoscopic Discectomy (MED): A prospective study in 150 patients. *Egypt Spine J* 24:14-24, 2017
 16. Elwany A, Zidan I, Sultan A: Efficacy of endoscopic surgery in management of patients with lumbar canal stenosis. *Egypt Spine J* 27:29-37, 2018
 17. Epstein NE: An analysis of noninstrumented posterolateral lumbar fusions performed in predominantly geriatric patients using lamina autograft and beta tricalcium phosphate. *Spine J* 8:882-887, 2008
 18. Fairbank JCT, Pynsent PB: The Oswestry Disability Index. *Spine (Phila Pa 1976)* 25:2940-2953, 2000
 19. Forrest KY, Stuhldreher WL: Prevalence and correlates of vitamin D deficiency in US adults. *Nutr Res* 31:48-54, 2011
 20. Ghogawala Z, Resnick DK, Watters WC, 3rd, Mummaneni PV, Dailey AT, Choudhri TF, et al: Guideline update for the performance of fusion procedures for degenerative disease of the lumbar spine. Part 2: assessment of functional outcome following lumbar fusion. *J Neurosurg Spine* 21:7-13, 2014
 21. Glassman SD, Anagnost SC, Parker A, Burke D, Johnson JR, Dimar JR: The effect of cigarette smoking and smoking cessation on spinal fusion. *Spine (Phila Pa 1976)* 25:2608-2615, 2000
 22. Gotfryd A, Avanzi O: A systematic review of randomised clinical trials using posterior discectomy to treat lumbar disc herniations. *Int Orthop* 33:11-17, 2008

23. Hashimoto T, Shigenobu K, Kanayama M, Harada M, Oha F, Ohkoshi Y, et al: Clinical results of single-level posterior lumbar interbody fusion using the Brantigan I/F carbon cage filled with a mixture of local morselized bone and bioactive ceramic granules. *Spine (Phila Pa 1976)* 27:258-262, 2002
24. Hermann PC, Webler M, Bornemann R, Jansen TR, Rommelspacher Y, Sander K, et al: Influence of smoking on spinal fusion after spondylodesis surgery: A comparative clinical study. *Technol Health Care* 24:737-744, 2016
25. Hioki A, Miyamoto K, Kodama H, Hosoe H, Nishimoto H, Sakaeda H, et al: Two-level posterior lumbar interbody fusion for degenerative disc disease: improved clinical outcome with restoration of lumbar lordosis. *Spine J* 5:600-607, 2005
26. Holick MF: Vitamin D deficiency. *N Engl J Med* 357:266-281, 2007
27. Kai Y, Oyama M, Morooka M: Posterior lumbar interbody fusion using local facet joint autograft and pedicle screw fixation. *Spine (Phila Pa 1976)* 29:41-46, 2004
28. Kalfas IH: Principles of bone healing. *Neurosurg Focus* 10:1-4, 2001
29. Kim D-H, Jeong S-T, Lee S-S: Posterior lumbar interbody fusion using a unilateral single cage and a local morselized bone graft in the degenerative lumbar spine. *Clin Orthop Surg* 1:214-221, 2009
30. Kim T-H, Yoon JY, Lee BH, Jung H-S, Park MS, Park J-O, et al: Changes in vitamin D status after surgery in female patients with lumbar spinal stenosis and its clinical significance. *Spine (Phila Pa 1976)* 37:E1326-E1330, 2012
31. Lin B, Yu H, Chen Z, Huang Z, Zhang W: Comparison of the PEEK cage and an autologous cage made from the lumbar spinous process and laminae in posterior lumbar interbody fusion. *BMC Musculoskelet Disord* 17:374, 2016
32. Liu Z, Liu J, Tan Y, He L, Long X, Yang D, et al: A comparative study between local bone graft with a cage and with no cage in single posterior lumbar interbody fusion (PLIF): a multicenter study. *Arch Orthop Trauma Surg* 134:1051-1057, 2014
33. Luszczuk M, Smith JS, Fischgrund JS, Ludwig SC, Sasso RC, Shaffrey CI, et al: Does smoking have an impact on fusion rate in single-level anterior cervical discectomy and fusion with allograft and rigid plate fixation? *J Neurosurg Spine* 19:527-531, 2013
34. Molinari RW, Sloboda J, Johnstone FL: Are 2 cages needed with instrumented PLIF? A comparison of 1 versus 2 interbody cages in a military population. *Am J Orthop (Belle Mead NJ)* 32:337-343; discussion 43, 2003
35. Mummaneni PV, Meyer SA, Wu J-C: Biological approaches to spinal instrumentation and fusion in spinal deformity surgery. *Neurosurgery* 58:110-116, 2011
36. Müslüman AM, Yılmaz A, Cansever T, Çavuşoğlu H, Çolak İ, Genç HA, et al: Posterior lumbar interbody fusion versus posterolateral fusion with instrumentation in the treatment of low-grade isthmic spondylolisthesis: midterm clinical outcomes. *J Neurosurg Spine* 14:488-496, 2011
37. Panjabi MM: The stabilizing system of the spine. Part II. Neutral zone and instability hypothesis. *J Spinal Disord* 5:390-396, 1992
38. Penta M, Fraser RD: Anterior lumbar interbody fusion: a minimum 10-year follow-up. *Spine (Phila Pa 1976)* 22:2429-2434, 1997
39. Ravindra VM, Godzik J, Dailey AT, Schmidt MH, Bisson EF, Hood RS, et al: Vitamin D levels and 1-year fusion outcomes in elective spine surgery. *Spine (Phila Pa 1976)* 40:1536-1541, 2015
40. Schofferman J, Schofferman L, Zucherman J, Hsu K, White A: Metabolic bone disease in lumbar pseudarthrosis. *Spine (Phila Pa 1976)* 15:687-689, 1990

41. Sears W: Posterior lumbar interbody fusion for degenerative spondylolisthesis: restoration of sagittal balance using insert-and-rotate interbody spacers. *Spine J* 5:170-179, 2005
42. Stoker GE, Buchowski JM, Bridwell KH, Lenke LG, Riew KD, Zebala LP: Preoperative vitamin D status of adults undergoing surgical spinal fusion. *Spine (Phila Pa 1976)* 38:507-515, 2013
43. Summers B, Eisenstein S: Donor site pain from the ilium. A complication of lumbar spine fusion. *J Bone Joint Surg Br* 71:677-680, 1989
44. Tangpricha V, Pearce EN, Chen TC, Holick MF: Vitamin D insufficiency among free-living healthy young adults. *Am J Med* 112:659-662, 2002
45. Thalgott JS, Fogarty ME, Giuffre JM, Christenson SD, Epstein AK, Aprill C: A prospective, randomized, blinded, single-site study to evaluate the clinical and radiographic differences between frozen and freeze-dried allograft when used as part of a circumferential anterior lumbar interbody fusion procedure. *Spine (Phila Pa 1976)* 34:1251-1256, 2009
46. Theiss SM, Boden SD, Hair G, Titus L, Morone MA, Ugbo J: The effect of nicotine on gene expression during spine fusion. *Spine (Phila Pa 1976)* 25:2588-2594, 2000
47. Urban JP, Roberts S: Degeneration of the intervertebral disc. *Arthritis Res Ther* 5:120, 2003
48. Waikukul S: Serum 25-hydroxy-calciferol level and failed back surgery syndrome. *J Orthop Surg (Hong Kong)* 20:18-22, 2012
49. Wetzel FT, Brustein M, Phillips FM, Trott S: Hardware failure in an unconstrained lumbar pedicle screw system: a 2-year follow-up study. *Spine (Phila Pa 1976)* 24:1138-1143, 1999
50. Xu Y, Zhou M, Liu H, Zhang Q, Hu Z, Zhang N, et al: Effect of 1, 25-dihydroxyvitamin D3 on posterior transforaminal lumbar interbody fusion in patients with osteoporosis and lumbar disc degenerative disease. *Zhongguo Xiu Fu Chong Jian Wai Ke Za Zhi* 28:969-972, 2014
51. Yu C-H, Wang C-T, Chen P-Q: Instrumented posterior lumbar interbody fusion in adult spondylolisthesis. *Clin Orthop Relat Res* 466:3034-3043, 2008
52. Zdeblick TA: A prospective, randomized study of lumbar fusion. Preliminary results. *Spine (Phila Pa 1976)* 18:983-991, 1993
53. Zhao J, Hou T, Wang X, Ma S: Posterior lumbar interbody fusion using one diagonal fusion cage with transpedicular screw/rod fixation. *Eur Spine J* 12:173-177, 2003

الملخص العربي

تأثير تدخين السجائر ووضع فيتامين د على معدلات الالتحام بعد جراحة الالتحام الخلفي بين أجسام الفقرات القطنية. هل يوجد ارتباط بين الالتحام الناجح على الأشعة وبين النتائج السريرية الأفضل؟

البيانات الخلفية: تعد جراحة الالتحام بين أجسام الفقرات القطنية هي الخيار الجراحي الأمثل لعلاج أمراض الغضروف التنكسية والانزلاق الفقاري. ويظل الهدف الرئيسي للجراحة هو تحقيق التماس قوي بين الفقرات. ومع ذلك ، فإن الارتباط بين الالتحام القوي بين الفقرات كما يظهر بالأشعة والنتائج السريرية الأفضل ليس راسخًا، وكذلك العوامل التي قد تؤثر على نجاح عملية الالتحام.

الغرض: الهدف من الدراسة هو تقييم تأثير نقص فيتامين د وتدخين السجائر على معدلات الالتحام الفقاري الناجح كما يظهر بالأشعة بعد جراحة الالتحام الخلفي بين أجسام الفقرات القطنية لعلاج أمراض الغضروف التنكسية، وكذلك تقييم العلاقة بين الالتحام الفقاري كما يظهر بالأشعة وبين النتائج السريرية.

تصميم الدراسة: دراسة أتراب ارتقائية.

المرضى والطرق: أجريت الدراسة على 67 مريضاً يعانون من أمراض الغضروف التنكسية، والذين خضعوا لجراحة الالتحام الخلفي بين أجسام الفقرات القطنية في مؤسستنا العلاجية. تم تقييم النتائج السريرية (التي تم قياسها من خلال مؤشر أوسفستري للعجز، ODI ، ومقياس التماثل البصري، VAS) ، وتقييم حالة الالتحام الفقاري على الأشعة (وفقاً لنظام Bridwell لتقييم الالتحام بين أجسام الفقرات القطنية) بعد 6 أشهر من إجراء الجراحة. بالإضافة إلى ذلك، تم تقييم التأثير المحتمل لعادات التدخين وحالة فيتامين د (د) في المرضى على معدلات الالتحام.

النتائج: كان المعدل الإجمالي للالتحام الفقاري السليم في المتابعة النهائية 86.6%. كما كان هناك تحسن كبير في متوسط مؤشرات ODI وVAS في التقييم النهائي. لم يتم إثبات وجود علاقة نسبية بين الالتحام الفقاري السليم والنتائج السريرية الأفضل. على الجهة المقابلة، اقترن التدخين وانخفاض معدل فيتامين د (د) في الدم في بعض المرضى بمعدلات أسوأ للالتحام الفقاري.

الاستنتاج: لم تكن هناك علاقة نسبية بين الالتحام الفقاري والنتائج السريرية. ومع ذلك، يبدو أن عادات التدخين وانخفاض فيتامين د (د) في الدم لها تأثير سلبي على نجاح الالتحام الفقاري.