

Comparison of Surgical Outcomes between Cortical Bony Trajectory Screw and Traditional Trajectory Screw in Posterior Lumbar Interbody Fusion: A Systematic Review

Mohamed F Khattab, MD., Mostafa A Kamal, MD., Naser H Zaher, MD.

Department of Orthopedic Surgery, Faculty of Medicine, Ain Shams University, Cairo, Egypt.

ABSTRACT

Background Data: Pedicle screw is the main method for lumbar spine fixation. Pedicle screw fixation allows correction of spinal deformities and avoids nonunion. Cortical bony trajectory screw (CBTS) is a new procedure in which screw follows an inferior to superior pathway in the sagittal plane and a medial to lateral pathway in the transverse plane. CBTS reduces the operative and postoperative complications and has high fixation strength.

Purpose: To compare the clinical and radiological outcomes between CBTS and traditional trajectory screw (TTS) in posterior lumbar interbody fusion.

Study Design: Systematic review of literature.

Materials and Methods: Comprehensive electronic search in PubMed, Cochrane Library databases, Google Scholar, and ResearchGate for articles that were published between 2009 and 2019 using the following keywords: cortical bony trajectory screw, cortical bony trajectory-pedicle screw, pedicle screw, and posterior lumbar interbody fusion.

Results: Eleven articles met our inclusion criteria and were reported. The majority of the published data prove that the CBTS approach has a similar postoperative leg and back pain when compared to TTS although some of them reported less leg and back pain as regards CBTS. Oswestry Disability Index (ODI) and the operative time showed no significant differences between the CBTS and TTS. Radiological outcomes were similar in both procedures regarding fusion rates and vertebral slippage reduction. Blood loss during surgery was significantly less with CBTS compared to TTS.

Conclusion: Both Oswestry Disability Index and operative time showed insignificant differences between the CBTS and TTS. Blood loss was significantly less with CBTS compared to TTS. Radiological outcomes were similar in both procedures. CBTS is a reasonable alternative technique to TTS in short segment posterior lumbar interbody fusion although the current literature did not prove its superiority. (2019ESJ197)

Keywords: Cortical bony trajectory screw, conventional screw trajectory, and posterior lumbar interbody fusion.

Address correspondence and reprint requests: Mostafa Atef Kamal, MD.

Department of Orthopedic Surgery, Faculty of Medicine, Ain Shams University, Cairo, Egypt.

Email: mostafashwita@gmail.com

Submitted: November 13th, 2019.

Accepted: December 24th, 2019.

Published: January 2020.

The article does not contain information about medical device(s)/drug(s).

No funds were received in support of this work.

The authors report no conflict of interest.

INTRODUCTION

Pedicle screw is the main method for lumbar spine fixation. Pedicle screw fixation allows the management of a large number of spine disorders such as management of fractures, tumors, and degenerative spine.¹⁹ The classic pathway for pedicle screw insertion is from lateral to medial with the initial starting point at the junction between the transverse process of vertebrae and lateral wall of the facet. Several complications may occur with traditional trajectory screw fixation such as misplacement and loosening of screw and loss of stability, especially in old patients with osteoporosis.^{19, 13}

The extensive dissection of paraspinal muscles required for pedicle screw insertion and the high risk of neurovascular injury recorded by many reports of misplacement of screws¹⁹ are the main disadvantages. Recently, a huge number of developments in the design of pedicular screw (PS) and techniques of implantation and an alternative pathway for fixation of PS have been developed which aim to increase the PS purchase in the higher bone density regions of vertebrae.

Santoni et al.¹⁹ were the first surgeons to describe the cortical bony trajectory screw (CBTS) in which screw follows an inferior to superior pathway in the sagittal plane and a medial to lateral pathway in the transverse plane. This recently developed trajectory enables the PS to engage the dorsal lamina and the pedicle through the cortical bone, enhances the biomechanical stability, increases the pull-out strength of CBTS, and decreases the screw loosening incidence.¹⁴

The aim of this review is to compare the clinical and radiological outcomes between CBTS and TTS in posterior lumbar interbody fusion.

MATERIALS & METHODS

A comprehensive electronic search in PubMed, Cochrane Library databases, Google Scholar,

and ResearchGate for articles that were published between 2009 and 2019 was carried out using the following keywords: cortical bony trajectory screw, cortical bony trajectory-pedicle screw, pedicle screw, and posterior lumbar interbody fusion. We revised all headings, abstracts, and the complete contents of articles which were acceptable according to the following inclusion and exclusion criteria we identified.

Inclusion Criteria: Studies that compared the clinical and radiological outcomes between CBTS and TTS in posterior lumbar interbody fusion, including randomized control trials studies, retrospective studies, case series studies, and any study published in English language from 2009 to December 2019 were included. The outcomes involved primary outcomes (clinical outcome and radiographic outcome or at least one of them) and secondary outcomes (blood loss and operative time) of adult patients, who received posterior lumbar spinal fusion using cortical bony trajectory screw and traditional trajectory screw technique.

Exclusion Criteria: Animal or cadaveric studies, spinal deformities in adolescents, patients who had trauma, tumor, and rheumatoid arthritis, and patients who had postoperative regimen of pharmaceutical agent that could interfere with fusion process such as chemotherapy and steroids agent were excluded.

Data Extraction: The data extracted included the following items: study characteristics including the name of the first author, country, year of publication, and study design; patients characteristics including number of patients (sample size), mean age, and gender; preoperative diagnosis; details of intervention; follow-up; and the resulting outcomes of comparison.

Points of Comparison: Clinical outcome, radiographic outcome (fusion rate), blood loss, operation time, demographic characteristics of the studies, and the operative details of the reported studies were the main points of comparison.

Statistical Analysis:

Analysis was performed by Statistical Package for Social Science SPSS (version 20, Chicago, Inc.).

Parametric data for each variable was presented in mean±SD. Categorical numeric data were analyzed using chi square test, with a level of significance of $P<0.05$.

RESULTS

From the extensive electronic searching, a total of 287 studies were identified. 46 studies remained after duplicates were omitted. Based on the titles and abstracts, 30 studies were removed. Full texts of 16 studies were reviewed; five of them were excluded because of non-comparison intervention groups, cervical fusion, or non-human studies. Finally, 11 studies were included in the systematic review (Figure 1).

Eleven studies were included in the systematic review (7 from Japan, 2 from USA, 1 from Korea, and 1 from Taiwan). Four were randomized control trials, and 7 were cohort studies. The total number of cases was 834; all have been managed by posterior lumbar interbody fusion. Mean age ranged from 46 to 67 years, and this was extracted from 9 studies. Gender was identified in 9 studies as 396 males and 385 females. Mean age of the patient population was 59.1 years. Follow-up range was 6–37.5 months. The involved studies were tabulated, and the characteristics of the 11 studies were described in Tables 1 and 2.

All studies showed improvement in clinical and functional outcomes of the operated patients. Fusion rates were reported in 4 studies, and it was assessed radiologically by CT-scan. The mean fusion rate in CBTS group was 88%, while in TTS group it was 91.03%. This demonstrates that the fusion rate after surgery in CBTS group was similar to that in the TTS group (Table 3).

Oswestry Disability Index (ODI) is a self-completed questionnaire used in 3 studies to

compare the functional outcomes after the fusion procedure. Patients in both techniques showed improvement. The 3 studies compared mean ODI scores between CBTS and TTS groups. The mean ODI for the CBTS studies was 15.33, and for TTS it was 17.31. The comparison between the study data variables showed no significant difference except Chin et al.⁴ who reported that the disability scores were better in CBTS group than the TTS group (Table 4).

Assessment of pain intensity was carried out by the popular VAS tool (5 studies were VAS back pain and 4 studies were VAS leg pain) between CBTS and TTS groups. These outcome scores were variable between studies with significant results ($P<0.001$) reported by Chen et al.³ and Chin et al.⁴ for VAS back pain and Chin et al.⁴ and Lee et al.⁹ for VAS leg pain. These results showed that the CBTS group had back and leg pain scores better than those for the TTS group (Table 5).

Secondary outcome parameters (operative time and blood loss) were reported in 6 studies. The surgical procedure time and blood loss were less in CBTS surgical procedure than TTS surgical procedure. The mean operative time for all CBTS studies was 162.48 minutes, while for the TTS it was 192.38 minutes. The mean amount of blood loss for all studies was 174.36 ml for CBTS group and 254 ml for TTS group. Three studies reported that blood loss was significantly less for CBTS group (Table 6). The Japanese Orthopedic Association (JOA) scale is a scoring system for assessing the results of treatment for back pain (total JOA score is 29 points). Three studies investigate JOA scores between CBT and TTS groups. Mean scores were similar in the studies without significant difference between the groups indicating that both techniques gave satisfactory clinical and functional outcomes in both groups (Table 7).

Table 1. Demographic characteristics of the included studies.

Authors	Country	Study design	Total patients	Age/years	Sex (%)	
					Male	Female
Kojima et al. ⁸	Japan	RCT	222	66	110	112
Mori et al. ¹³	Japan	RCT	32	-	-	-
Orita et al. ¹⁶	Japan	Cohort	40	63.6	23	17
Kasukawa et al. ⁷	Japan	Cohort	26	67	11	15
Hung et al. ⁶	Taiwan	Cohort	32	62	11	21
Ninomiya et al. ¹⁵	Japan	Cohort	21	61.8	-	-
Chen et al. ³	USA	Cohort	33	56	13	20
Lee et al. ⁹	Korea	RCT	72	51.7	64	8
Chin et al. ⁴	United States	Cohort	60	58	33	27
Sakaura et al. ¹⁸	Japan	Cohort	177	46	82	95
Takenaka et al. ²¹	Japan	RCT	119	-	49	70

RCT: randomized control trial.

Table 2. Techniques of fusions and follow-up of the included studies.

Authors	Comparison	Fusion technique	Follow-up/ months	Outcomes
Kojima et al. ⁸	CBTS vs TTS	PLIF	-	JOA, complications
Mori et al. ¹³	CBTS	PLIF	24	Complications
Orita et al. ¹⁶	CBTS vs TTS	PLIF	6	VAS (leg and back), complications
Kasukawa et al. ⁷	CBTS vs TTS	PLIF	8	Complications
Hung et al. ⁶	CBTS vs TTS	PLIF	18	VAS (leg and back), JOA, ODI
Ninomiya et al. ¹⁵	CBTS vs TTS	PLIF	12	Complications
Chen et al. ³	CBTS vs TTS	PLIF	8	VAS back
Lee et al. ⁹	CBTS vs TTS	PLIF	12	VAS (leg and back), ODI, complications
Chin et al. ⁴	CBTS vs TTS	PLIF	24	VAS (leg and back), ODI, complications
Sakaura et al. ¹⁸	CBTS vs TTS	PLIF	37.5	JOA, complications
Takenaka et al. ²¹	CBTS vs TTS	PLIF	12	Complications

Table 3. Radiographic outcomes (fusion rate).

Study	CBTS	TTS
Kasukawa et al. ⁷	91%	91.5%
Lee et al. ⁹	91.4%	94.5%
Sakaura et al. ¹⁸	88.4%	96.3%
Takenaka et al. ²¹	81%	81.8%

Table 4. Oswestry Disability Index.

Study	CBTS	TTS	P value
Hung et al. ⁶	5.5±1.71	5.84±4.43	0.777
Lee et al. ⁹	11.8±6.2	13.6±4.9	0.157
Chin et al. ⁴	28.7±1.8	32.5±2.1	<0.001*

Table 5. Visual Analogue Scale.

Study	VASB		P value	VASL		P value
	CBTS	TTS		CBTS	TTS	
Hung et al. ⁶	1.25±0.96	1.08±1.11	0.647	0.50±0.55	0.15±0.55	0.082
Chen et al. ³	3.80±0.75	6.14±0.61	<0.001*	-----	-----	-----
Lee et al. ⁹	2.7±0.8	2.9±1.1	0.357	1.3±0.7	1.8±0.6	0.001*
Chin et al. ⁴	2.5±0.7	5.9±0.8	<0.001*	0.2±0.2	1.9±1.1	<0.001*
Takenaka et al. ²¹	5.7±3.1	5.2±2.8	0.379	6.8±2.6	6.3±2.6	0.326

Table 6. Secondary outcomes.

Study	Operative time (minute)		P value	Blood loss (ml.)		P value
	CBTS	TTS		CBTS	TTS	
Orita et al. ¹⁶	147.3±23.3	144±19.2	0.628	164±27.6	205±57.7	0.007*
Kasukawa et al. ⁷	209±49	220.5±51	0.576	188±167	319.5±220	0.119
Hung et al. ⁶	237.6±63	265.8±85.2	0.296	218.18±78.33	272.50±78.04	0.059
Chin et al. ⁴	138±10	254±24	<0.001*	152±28	319±87	<0.001*
Sakaura et al. ¹⁸	123±24	145±33	<0.001*	205±152	204±145	0.965
Takenaka et al. ²¹	120±15	125±25	0.239	119±76	204±117	<0.001*

Table 7. Japanese Orthopedic Association outcome scale.

Study	CBTS	TTS	P value
Hung et al. ⁶	27±2.16	25.77±1.92	0.099
Sakaura et al. ¹⁸	23.3	22.7	
Takenaka et al. ²¹	50	43	

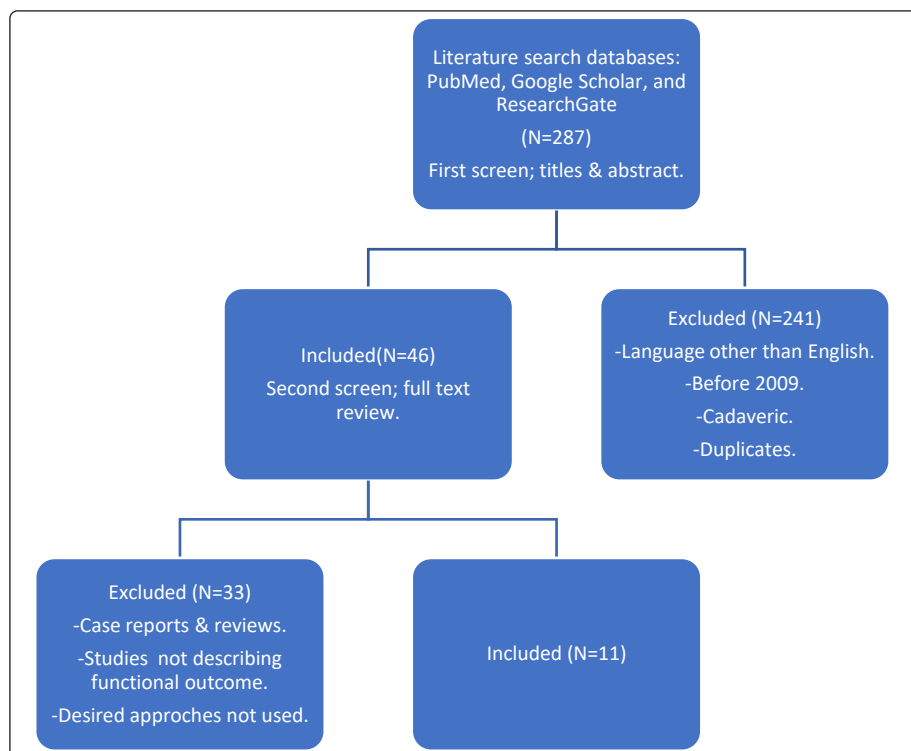


Figure 1. PRISMA chart for search strategy of the present systematic review.

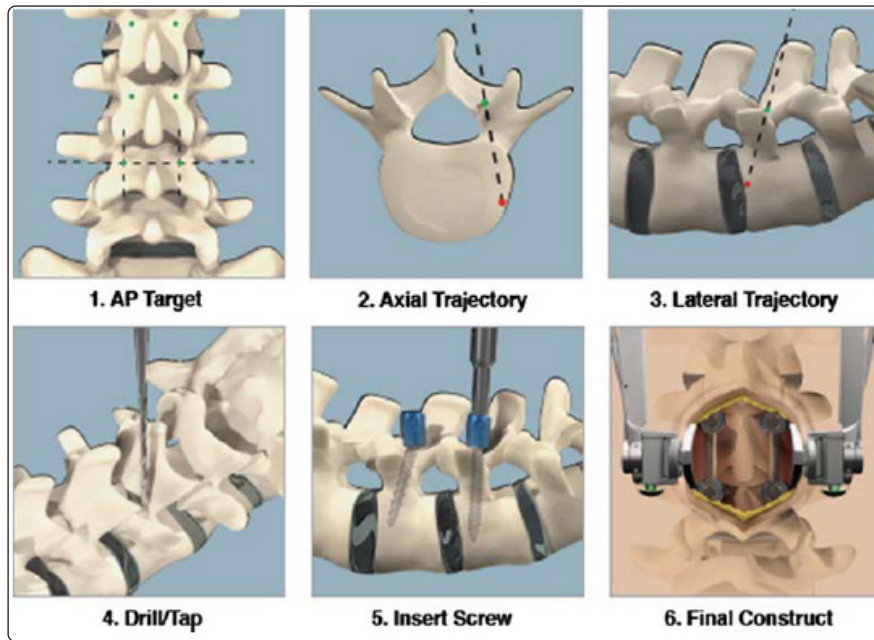


Figure 2.
Demonstration
of the CBTS
procedure and
screw purchase.⁴

DISCUSSION

This systematic review compares the clinical and radiological outcomes of both CBTS and TTS in posterior lumbar interbody fusion. Generally, there is no confirmed agreement regarding comparison of clinical outcomes and drawbacks between the CBTS and TTS approaches. Indications for CBTS and TTS are comparable between most researches in posterior lumbar interbody fusion.

The TTS technique to lumbosacral spine surgery requires massive dissection of paraspinal muscles for placement of PS. On the other hand, the CBTS technique needs less exposure of soft tissue as screw is placed from the medial side at the initial insertional point at the connection between pars interarticularis (laterally) and articular process (superiorly) (Figure 2).

The surgical steps involve surgical exposure of the vertebral laminae by muscle stripping of the spinous process and then decompression of neural elements with total facetectomy. This gives a good exposure of the disc and nerve roots that prevent impingement of roots. Kojima et al.⁸ reported that the initial insertional point for screw in CBTS is the pars interarticularis which is rich in the cortical bone. CBTS is very important during lumbar spine

fusion in osteoporotic individuals. The diameter of PS was 5.5 mm, and the length was 35–40 mm with screw inserted under fluoroscopy guidance.¹⁰ Traditional trajectory technique (TTS) is associated with complications related to the approach which results in iatrogenic damage of the soft tissue. The drawbacks include wide incisions, elongated extensive retraction of muscles, and damage of the posterior ramus (medial branch) of the spinal nerve, which may lead to ischemia and necrosis of paraspinal muscles. Also, persistent back pain is included due to the damage of muscular support and disrupted mobility,⁶ and huge infiltration of fat tissue affects multifidus muscles that also lead to low back pain.

Chen et al.³ and Chin et al.⁴ documented a statistical significance of results in Visual Analogue Scale back pain (VASB) between CBTS and TTS postoperatively ($P < 0.01$). Orita et al.¹⁶, Hung et al.⁶, Lee et al.⁹, and Takenaka et al.²¹ all documented insignificant differences in VAS back pain between their study groups ($P > 0.05$). Chin et al.⁴ and Lee et al.⁹ documented a statistical significance in VAS leg pain (VASL) between CBTS and TTS postoperatively ($P < 0.01$). Orita et al.¹⁶, Hung et al.⁶, and Takenaka et al.²¹ all documented insignificant differences in VASB between their study groups ($P > 0.05$). Generally,

the majority of the published data prove that the CBTS approach has a similar postoperative leg and back pain when compared to TTS.

To evaluate the disability, the Oswestry Disability Index (ODI) score was utilized. Chin et al.⁴ documented a statistically significant reduction in ODI score in CBTS compared to TTS postoperatively ($P < 0.01$). Hung et al.⁶ and Lee et al.⁹ reported insignificant differences in ODI score among the two groups ($P > 0.05$).

Complications were described in Sakaura et al.¹⁸ and Takenaka et al.²¹ series, and both of them reported insignificant differences in screw misplacement, dural tears, hematomas, and wound infections between the two groups.

Increased operative duration resulted in increased blood loss, increased rates of infection, and increased surgical complications. Six studies compared operative duration in lumbar spine fixation using CBTS and TTS techniques. Only Chin et al.⁴ and Sakaura et al.¹⁸ confirmed a statistically significant findings. TTS technique had a longer duration than CBTS ($P < 0.01$). Other studies reported that operative times between the two groups showed no significant difference between the two groups.

Blood loss during operations was a critical factor in comparing surgical procedures because of its effect on the general outcome. Six studies reported blood loss for CBTS and TTS. Five of them showed less blood loss in CBTS than TTS. Orita et al.¹⁶, Chin et al.⁴, and Takenaka et al.²¹ reported that loss of blood was significantly less for CBTS compared to TTS ($P < 0.01$). CBTS probably leads to less blood loss than TTS, which is a critical factor in choosing the surgical procedures for lumbar fixation in individuals with a high risk surgery. Blood loss may be of a great importance in patients with chronic medical diseases such as hemodynamic instability and anemia that may lead to a big problem in case of critical loss of blood.

Japanese Orthopedic Association (JOA) score was designed for back pain assessment that was reported by Hung et al.⁶, Sakaura et al.¹⁸, and Takenaka et

al.²¹ who reported insignificant difference between the two techniques. Radiological analysis of outcomes showed that fusion rates were similar in CBTS and TTS.

Reviewing the previous articles showed that TTS provides a good stability to the unstable lumbar segment in spinal fusion although it has a probability of facet violation, damage of dura, and damage of neural elements during soft tissue dissection and screw placement.¹

Snyder et al.²⁰ demonstrated that 69 (87.3%) of his 79 patients had CBTS procedures utilizing navigation guidance. The first postoperative imaging after placement of PS showed ideal trajectory placement of screw. CBTS is only used in surgeries which require a few levels of fixation, whereas TTS is offered for any length of fusion. Although TTS is the most eligible and famous instrument for spinal fusion, screw loosening is an unresolved problem especially in the osteoporotic cases.¹⁹ CBTS enhances screw purchase because of its different trajectory which provides maximum contact of screw with the regions of higher cortical bone density.² A biomechanical study reported an increase in pull-out strength of CBTS when compared to TTS.¹⁹ Mori et al.¹³ reported that CBTS produced an insertional torque 2-fold higher than TTS. Insertional torque is a good indicator of screw stability and pull-out strength.^{11, 13}

Despite the frequent use of CBTS in lumbar spine fixation, little has been reported regarding the use of CBTS in the sacral spine. Because of the unique anatomy of sacrum that does not have a true pedicle and the bone of sacrum that is mainly cancellous as well as the higher density of bone found only in the superior end plate of scrum, there are many frequent starting points which are used by many surgeons. The anterolateral portion of the upper S1 body is the high-density area of trabecular intersection of sacrum, and the initial insertional point of S1 was the connection between the medial border of pedicle of S1 vertebra and the inferior border of inferior articular process of the L5 vertebra. It is still controversial which area

is the best for providing the maximum contact with dense bone.¹⁷

Matsukawa et al.¹² thought that CBTS would show good fixation strength by purchase of the highly sclerotic surface at the pars defect, but the result was against this view. This is due to the lack of penetration of the cortical bone of the lamina. Regarding the anatomy, the cortical bone is mostly concentrated between the inferior portion of the pedicle and the pars interarticularis. The fixation strength of CBTS depends on getting maximum contact with the lamina. This is an important factor in gaining ideal fixation strength.⁵ The spondylolytic vertebra has no pars and adjacent lamina on which CBTS depends for its stability. In the spondylolytic vertebrae, CBTS showed similar pull-out strength compared to TTS, but the CBTS proved to have a significantly lower fixation strength compared to the TTS in all planes of movement. The cause of this result is the absence of cortical purchase in the posterior lamina and the divergent manner and short lever arm of CBTS. Matsukawa et al.¹² recommended TTS for fixation of spondylolytic vertebrae over CBTS, even with its superior advantages.

Kojima et al.⁸ reported that the initial point for the screw insertion in CBTS is the pars interarticularis which is rich in the cortical bone. CBTS may be used especially in patients with older age and poor bone quality. The satisfactory fixation with PS insertion into the vertebral body using the TTS proves to be difficult because of the absence of anchorage due to osteoporosis. So, the area of bone which the PS penetrates using CBTS is richer in cortical bone compared to the TTS.⁴

The fusion rate may be high in the TTS compared to the CBTS. A biomechanical study in cadaveric lumbar spine reported that TTS is stiffer than CBTS fixation during axial rotation with an intact intervertebral disc.¹¹ The micromotion that results from axial rotation or lateral bending may lead to low fusion rate in the CBTS. To improve spinal fusion in the CBTS, a small connector decreases the micromotion during axial rotation and bending.

Ninomiya et al.¹⁵ documented that CBTS has a shorter pathway than the TTS for spinal fusion. This pathway is effective in case of degenerated vertebrae because the screw is penetrating the high-density cortical bone. In conventional trajectory, the convergent manner of the PS with the midline at an angle of 30° adds another stability for fixation during axial rotation.^{4, 11}

Caudomedial insertion point of CBTS is far from the superior facet joint in comparison with the TTS. So, the CBTS may reduce the superior facet violation.^{13, 6, 15} Also, it may reduce dural damage by reducing facet violation.⁶

From the authors' point of view, the available literature did not address the learning curve, image exposure, cost effectiveness, and system availability in utilizing CBTS. These important points need to be addressed in future research.

CONCLUSION

Both Oswestry Disability Index and operative time showed insignificant differences between the CBTS and TTS. Blood loss is significantly less with CBTS compared to TTS. Radiological outcomes were similar in both procedures. CBTS is a reasonable alternative technique to TTS in short segment posterior lumbar interbody fusion although the current literatures did not prove its superiority.

REFERENCES

1. Athanasakopoulos M, Mavrogenis AF, Triantafyllopoulos G, Koufos S, Pneumaticos SG: Posterior spinal fusion using pedicle screws. *Orthopedics* 36:e951–957, 2013
2. Baluch DA, Patel AA, Lullo B, Havey RM, Voronov LI, Nguyen NL, et al: Effect of physiological loads on cortical and traditional pedicle screw fixation. *Spine* 39:e1297–1302, 2014

3. Chen YR, Deb S, Pham L, Harminder S: Minimally invasive lumbar pedicle screw fixation using cortical bone trajectory: a prospective cohort study on postoperative pain outcomes. *Cureus* 8: e714, 2016
4. Chin KR, Pencle FJ, Coombs AV, Elsharkawy M, Packer CF, Hothem EA, et al: Clinical outcomes with midline cortical bone trajectory pedicle screws versus traditional pedicle screws in moving lumbar fusions from hospitals to outpatient surgery centers. *Clin Spine Surg* 30: e791–797, 2017
5. Hirano T, Hasegawa K, Takahashi HE, Uchiyama S, Hara T, Washio T, et al: Structural characteristics of the pedicle and its role in screw stability. *Spine* 22:e2504–2510, 1997
6. Hung C, Wu MF, Hong RT, Weng MJ, Yu GF, Kao CH: Comparison of multifidus muscle atrophy after posterior lumbar interbody fusion with conventional and cortical bone trajectory. *Clinical Neurology and Neurosurgery* 145:41–45, 2016
7. Kasukawa Y, Miyakoshi N, Hongo M, Ishikawa Y, Kudo D, Shimada Y: Short-term results of transforaminal lumbar interbody fusion using pedicle screw with CBT compared with conventional trajectory. *Asian Spine J* (8) : 9:440–448, 2015
8. Kojima K, Asamoto S, Kobayashi Y, Ishikawa M, Fukui Y: Cortical bone trajectory and traditional trajectory a radiological evaluation of screw-bone contact. *Acta Neurochir* 157:1173–1178, 2015
9. Lee GW, Son JH, Ahn MW, Kim HJ, Yeom JS: The comparison of pedicle screw and cortical screw in posterior lumbar interbody fusion: a prospective randomized noninferiority trial. *Spine J* 15:1519–1526, 2015
10. Matsukawa K, Yato Y, Imabayashi H, Hosogane N, Asazuma T, Nemoto K: Biomechanical evaluation of the fixation strength of lumbar pedicle screws using cortical bone trajectory: a finite element study. *J Neurosurgery Spine* 23:471–478, 2015
11. Matsukawa K, Yato Y, Kato T, Imabayashi H, Asazuma T, Nemoto K: In vivo analysis of insertional torque during pedicle screwing using cortical bone trajectory technique. *Spine* 39:E240–E245, 2014
12. Matsukawa K, Yato Y, Nemoto O, Imabayashi H, Asazuma T, Nemoto K: Morphometric measurement of cortical bone trajectory for lumbar pedicle screw insertion using computed tomography. *J Spinal Disord Tech* 26:E248-E253, 2013
13. Mori K, Nishizawa K, Nakamura A, Shinji I: Short-term clinical result of cortical bone trajectory technique for the treatment of degenerative lumbar spondylolisthesis with more than 1-year follow-up. *Asian Spine J* 10:238–244, 2016
14. Myers BS, Belmont PJ, Richardson WJ, Yu JR, Harper KD, Nightingale RW: The role of imaging and in situ biomechanical testing in assessing pedicle screw pull-out strength. *Spine* 21:1962–1968, 1996
15. Ninomiya K, Iwatsuki K, Ohnishi YI, Yoshimine T: Radiological evaluation of the initial fixation between cortical bone trajectory and conventional pedicle screw technique for lumbar degenerative spondylolisthesis. *Asian Spine J* 10:251–257, 2016
16. Orita S, Inage K, Kubota G, Sainoh T, Sato J, Fujimoto K, et al: One-year prospective evaluation of the technique of percutaneous cortical bone trajectory spondylodesis in comparison with percutaneous pedicle screw fixation: a preliminary report with technical note. *J NeuroSurgery* 77: 531–537, 2016
17. Robertson PA, Plank LD: Pedicle screw placement at the sacrum: anatomical characterization and limitations at S1. *Journal of Spinal Disorders* 12:227–233, 1999
18. Sakaura H, Miwa T, Yamashita T, Kuroda Y, Ohwada T: Posterior lumbar interbody fusion with cortical bone trajectory screw fixation versus posterior lumbar interbody fusion using traditional pedicle screw fixation

- for degenerative lumbar spondylolisthesis: a comparative study. J Neurosurg Spine 25:591–595, 2016
19. Santoni BG, Hynes RA, McGilvray KC, Rodriguez-Canessa G, Lyons AS, Henson MA, et al: Cortical bone trajectory for lumbar pedicle screws. Spine J 9:366–373, 2009
20. Snyder LA, Martinez-Del-Campo E, Neal MT, Zaidi HA, Awad AW, Bina R, et al: Lumbar spinal fixation with cortical bone trajectory pedicle screws in 79 patients with degenerative disease: perioperative outcomes and complications. World Neurosurg 88:205–213, 2016
21. Takenaka S, Mukai Y, Tateishi K, Hosono N, Fuji T, Kaito T: Clinical outcomes after posterior lumbar interbody fusion: comparison of cortical bone trajectory and conventional pedicle screw insertion. Clin Spine Surg 30:E1411–E1418, 2017

الملخص العربي

مراجعة منهجية ومقارنة للنتائج الجراحية بين مسار المسمار القشري والمسار التقليدي للمسار العنق في الانصهار الخلفي بين الفقرات القطنية

البيانات الخلفية: الطريقة التقليدية لتثبيت المسمار العنق للفقرة هي الطريقة الأساسية لتثبيت العمود الفقري القطني. يوفر تثبيت المسمار العنق العديد من المزايا، يتيح تصحيحًا متفوقًا لتشوهات العمود الفقري، ومعدلات منخفضة من عدم الالتئام. مسار المسمار القشري هو تقنية جديدة تتبع فيها المسامير طريق من أسفل إلى أعلى ومسار موجه من الوسط إلى الجانب. مسار المسمار القشري يقلل المضاعفات الجراحية وما بعد الجراحة ولديه قوة تثبيت عالية.

الغرض: مقارنة النتائج الجراحية بين مسار المسمار التقليدي ومسار المسمار القشري في الانصهار الخلفي بين الفقرات القطنية

تصميم الدراسة: مراجعة منهجية

المادة والطرق: بحث إلكتروني شامل في قواعد بيانات مكتبات الكترونية متعددة مثل باميد وميدلاين ومكتبة كوكران وباحث جوجل، بحث للمقالات التي نشرت بين عامي 2009 و2019 باستخدام هذه الكلمات الرئيسية: مسار المسمار القشري، المسمار القشري للعنق، المسمار العنق.

النتائج: تشير غالبية الأبحاث المنشورة إلى أن تقنية المسمار القشري تؤدي إلى ألم في الظهر والساق بعد العملية الجراحية مماثلة أو منخفضة مقارنةً بالطريقة التقليدية. فيما يتعلق باستخدام مؤشر أوسويستري والمدة الفعلية للجراحة لم تظهر أي فروق ذات دلالة إحصائية. نتائج الاشعة بين كلتا الطريقتين لا تظهر أي فرق إحصائي في معدلات الالتئام والانزلاق الفقري، فقدان الدم أثناء العمليات الجراحية أقل بكثير مع مسار المسمار القشري.

الاستنتاج: لا يوجد إجماع مقبول على نطاق واسع فيما يتعلق بمقارنة النتائج الجراحية والمضاعفات بين طريقة المسمار القشري والطريقة التقليدية. بشكل عام، تتشابه النتائج بين معظم الدراسات في الانصهار الخلفي بين الفقرات القطنية.