

## A Consecutive Series of 39 Microendoscopic Discectomies for Recurrent Lumbar Disc Herniation

Mohamed S Kabil, MD.

*Department of Neurosurgery, Ain Shams University Hospital, Cairo, Egypt.*

### Abstract

**Background Data:** Interlaminar microendoscopic discectomy (MED) for treatment of primary lumbar disc herniation is a fairly established technique in clinical practice. However, in recurrent cases, a concern is raised that anatomy has been distorted thus endoscopic intervention may carry greater risks of morbidity.

**Purpose:** In the present study, the authors report their seven years' experience with posterior interlaminar MED in recurrent lumbar disc herniation (RLDH), highlighting the surgical technique, its outcome and feasibility.

**Study Design:** A retrospective clinical case study.

**Patients and Methods:** In the period between May, 2009 and July, 2016, 39 consecutive patients with symptomatic RLDH as confirmed by clinical examination, magnetic resonance imaging (MRI) and computed tomography (CT) scan underwent posterior interlaminar MED. Mean age was 39.7 years, range: (29-56 years). The approach was similar to a standard interlaminar MED. Patients were followed-up for 7 years (mean follow-up was 47.9 months, range: 3 – 83 months). Clinical outcomes were reviewed and evaluated in terms of pain Visual Analogue Scale (VAS) and Modified Macnab criteria (MMC).

**Results:** Mean operative time was 97 minutes (range: 59–155 min.) with a mean blood loss of 57 ml and an approximate hospital stay of 22.5 hours. There were no new postoperative neurological deficits or major complications. At initial follow-up, according to MMC (3months postoperative) 67% of patients were pain free (26/39) and considered their postoperative status as excellent, 24% as good (9/39), and 8% (3/39) as fair, whereas one patient was unsatisfied. Intraoperatively, there were 3 patients of dural tears, mainly toward the beginning of our study, seven patients of accidental medial facetectomies due to excess bony work and two patients had an unintended fracture of the base of the spine. Postoperatively, 2 patients had temporary weakness of involved root that resolved on follow-up and three patients had transient postoperative neuralgia.

**Conclusion:** Recurrent lumbar disc herniation can be treated safely and adequately with posterior interlaminar MED although of partial loss of anatomy. The technique is associated with satisfactory clinical results as well as short hospital stay. It provides adequate visualization and decompression of the involved nerve root. (2017ESJ127)

**Keywords:** minimally invasive spine surgery; endoscopic lumbar disc surgery; endoscopic discectomy; recurrent lumbar disc

**Received on:**

October 18<sup>th</sup>, 2017

**Accepted on:**

December 24<sup>th</sup>, 2017

## Introduction

Recurrence of lumbar disc prolapse is the most common indication of reoperation after primary disc surgery. It is defined as symptomatic disc reherniation at the same operative level of first surgery following a period of unambiguous pain relief after primary surgical intervention.<sup>25</sup> The rate of occurrence of recurrence is between 0.5% and 25%.<sup>4</sup> Reoperation is considered more difficult due to distorted anatomy and adhesions, thus carrying higher risk of intraoperative complications such as dural tears and nerve injuries.<sup>4,22,25</sup> The results of surgery are generally less successful when compared to first time in terms of pain relief and functional outcomes.<sup>11,15,18,26</sup>

The best treatment option for recurrence is still a subject of debate. Several studies have advised discectomy alone for treatment of recurrent lumbar disc herniation (RLDH).<sup>11,27</sup> In its guidelines in 2014, the American Association of Neurological Surgeons (AANS) say that there is poor evidence to support the necessity of fusion for treatment of recurrent disc herniation, and they encourage further study and investigation for better assessments of this topic.<sup>27</sup> On the other hand, fusion has been advised by many other authors especially in presence of degenerative changes, chronic axial low back pain and spinal instability.<sup>18</sup> Overall, there is a significant variation in strategy of surgical management among different surgeons and institutions as depicted by a wide survey in the United States by Mroz et al,<sup>18</sup>

Interlaminar microendoscopic discectomy (MED) for treatment of primary lumbar disc herniation is a fairly established technique in clinical practice. In recurrent patients, a concern may be raised that the anatomy has been distorted thus endoscopic intervention may carry greater risks of morbidity. Some authors further advocated that the use of minimally invasive endoscopic discectomy in treatment of RLDH was associated with favorable results, decreased intraoperative bleeding as well as the need for fusion when compared to conventional open surgery.<sup>22</sup>

## Patients and Methods

In the period between May, 2009 and July, 2016, 39 consecutive patients with symptomatic RLDH as confirmed by clinical examination, magnetic resonance imaging (MRI) and computed tomography (CT) scan, underwent posterior interlaminar MED utilizing the Endospine® system (Karl Storz GmbH & Co., Tuttlingen, Germany). Mean age was 39.7 (Range, 29-56) years.

All surgeries were performed by a single surgeon, the author, at Ain Shams University Hospitals, Department of Neurosurgery, as well as two other hospitals in Cairo, Egypt. The approach was similar to a standard interlaminar MED. Patients were followed-up routinely with mean follow-up of 47.9 (Range, 3–83) months. Clinical outcomes were reviewed and evaluated in terms of pain and functional outcome via the Visual Analogue Scale (VAS) and Modified Macnab criteria (MMC).

Demographic criteria are depicted in Table 1. The indication for endoscopic discectomy for RLDH was the same as for microscopic and conventional surgery, defined according to present-day standards based on radicular pain symptoms and existing neurologic deficits.<sup>3,17</sup> Data on patient demographics, operative time, length of hospitalization, postoperative complications were obtained.

Thirty nine patients (25 men and 14 women) with clinically symptomatic single level RLDH met the inclusion criteria, and underwent endoscopic surgery. The disc levels were L3–4 (1 patient), L5–S1 (15 patients) and L4–5 (23 patients). All patients underwent preoperative lumbar spine plain X-ray (antero-posterior, lateral and oblique views) and MRI. Six patients with severe pain symptoms were operated upon immediately while the remaining 33 patients received conservative treatment for at least for 4 weeks prior to surgery.

The mean duration of symptoms was 11.1 (Range, 1-48) months. Mean operative time was 97 (Range, 58-168) minutes. Thirty four patients experienced substantial relief of their leg pain immediately after the operation. All patients were mobilized early after recovery from anesthesia and 87% (34/39) of patients discharged home within 24 hours of surgery on oral non-steroidal anti-inflammatory

drugs (NSAIDs), myorelaxants and occasionally Gabapentine.

Difficulties with anatomical orientation in the operative field or technical problems at different stages of the procedure have occasionally led to longer operative times. Only in one patient we were obliged to shift to classic microsurgical technique because of technical difficulties to complete the MED.

#### **Follow-up:**

All patients had routine preoperative assessment and neurological examination to be repeated on the second day postoperative and then at follow-up at 3 (39 patients), 6 (36 patients) 12 (26 patients) and 24 (11 patients) months and then annually for the rest of the follow-up period. The Visual Analog Scale (VAS) Score and Modified Macnab criteria (MMC) which focus mainly on subjective symptoms and the patient's functional improvement were used for assessing back and leg pain and to evaluate outcomes.<sup>16,21</sup> Data related to neurological symptoms and complications were collected and followed to demonstrate long-term outcome. Patients, who missed at least the initial 3 months follow-up, were not included in the results of this work.

At each follow-up visit, pain was assessed by the help of VAS score and MMC. For the VAS score patient satisfaction was evaluated by a scale from 0 to 10 (with 0 being poor to 10 being excellent). Patients mark on the line the point that they feel represents their perception of their current pain state. The VAS score is determined by measuring in millimeters from the left hand end of the line to the point that the patient marks. Of note, that there are many other ways in which VAS has been presented, including vertical lines and lines with extra descriptors or color coding. We found it most suitable to use VAS in its simplest scale form.

In addition pain was assessed at each follow-up using the MMC; excellent meaning free of pain, no restriction of mobility, no discomfort and no neurological signs. Good indicating occasional non-radicular pain with relief of presenting symptoms and signs. Fair indicating partial presence of pain, some relief of presenting symptoms and some improved functional capacity, whereas poor meant no decrease (or increase) in pain and continued

objective symptoms and signs of root involvement (Table 2).

#### **Inclusion Criteria:**

Inclusion criteria were patients who had radicular symptoms due to discogenic lumbar nerve root compression and failed conservative therapy or have severe pain with clinically evident recurrent disc prolapse that demand immediate surgery. Patients were included if they met the following criteria: 1) unilateral radiating leg pain that was more predominant than back pain; 2) MRI revealing a single level recurrence of posterior, posterolateral disc herniation at a low lumbar level (L3-S1) that correlates with the clinical findings; and 3) previous interlaminar surgery at the same level of the lumbar spine.

#### **Exclusion Criteria:**

Patients with the following criteria were excluded: 1) recurrent disc herniation following full laminectomy at first procedure; 2) patients with lateral herniation at the intervertebral foramen; 3) cranio-caudal migrated disc beyond half the adjacent vertebral body; 4) spinal instability; 5) double level disc prolapses; and patients that did not appear for at least their three months follow-up visit were excluded.

#### **Instrumentation:**

The Endospine® set working insert has three separate integrated channels; one for a zero-degree, 4 mm Hopkins endoscope, a second for suction, and the third and largest one is an 8 mm working channel for surgical instruments. In addition there is an adjustable nerve retractor in its medial groove. Special elevator/spatula, discectomy spoon forceps, modified bipolar forceps, Kerrison bone punches, as well as other endoscopic surgical instrumentation is provided to be introduced through the working channel during the procedure. The whole tool is designed in such a way that there is an angle of 12° between the working channel and the telescope where they meet, this provides extra safety due to good visualization of the tip of the instrument at all times and also limits hazardous deep insertion of surgical instruments (the system is constructed as to limit the insertion of the instruments or suction device beyond a certain level of depth that is required for surgery).

The telescope, being a zero-degree, is in close contact with the surgical field providing better magnification and normal anatomy visualization. The entire cone-shaped device is movable and the operating tube and working insert are not fixed to the operation table and can remain erect and well-balanced in the operative field during the entire surgery. The operating tube and working insert can be moved and adjusted by surgical instruments and/or suction, resulting in spontaneous movement of surgical vision and field, which is convenient for accessing the decompression field. The joystick principle, medial and lateral, cranial and caudal mobility within the spinal canal, provides a wide range of vision and is used to search for and remove the protruding disc by the controlling optics. There is no need for continuous water irrigation with this system (Figure 1)

#### **Operating Room Setup and Patient Positioning:**

The patient is positioned prone on a lumbar spine four-sided positioning frame same as for classic microdiscectomy, then further flexed at the hips to widen the interlaminar window and both legs are elevated below knee to decrease risk of deep venous thrombosis (DVT). The proximal pad supports the chest just distal to the axilla and the distal pad is against proximal thighs just distal to the iliac crests. The arms are supported at almost 90 degrees of abduction resting on an arm support next to the patient's head; the abdomen should be hanging free (Figure 2, A).

#### **Localization and Portal of Entry:**

The set is equipped with a special localization device for fluoroscopic determination of point of incision; it is designed so that it verifies not only the appropriateness of spinal level but also the correct trajectory of the endoscope in relation to the intervertebral space. Once the patient has been properly positioned the lumbar midline is identified and with the C-arm oriented in the lateral imaging position, the localization device is placed transversely across the center of the target disc and the level of the incision is thus precisely verified under fluoroscopic guidance. Two horizontal lines are then drawn on both sides of the localization device, and the point of entry is marked by a vertical line just paramedian, about 1 cm from the midline in

between both transverse lines where they intersect with the longitudinal midline. The operative field is then prepped and draped (Figure 2, A,B).

#### **Surgical Technique:**

Preoperatively, all patients receive antibiotics intravenously as a prophylaxis against infection. Following general anesthesia a midline cranio-caudal skin incision is marked. TV incision approximately 2 cm in length is made at the marked level. Following blunt mobilization of subcutaneous tissue, the deep lumbar fascia is incised longitudinally just lateral to the spinous processes using a sharp curved dissecting scissors and the paraspinal muscles are dissected and mobilized laterally using a special flat chisel.

The operating tube that acts both as a dilator and a working sheath, is then inserted into the operative field till it stops at the surface of the laminae at the interlaminar area. The tube is conical in shape and looks like a speculum, it has an oval opening at both ends and provides an optimal access for exposure of interlaminar window area creating a space through which work is performed and at the same time keeping away the surrounding muscle and soft tissue preventing them from interfering with the operative field.

At this stage of the operation the surgeon gains insight into the region of planned re-do fenestration. Next, a cupped forceps is used for cleaning off muscle remnants and soft tissue attached to the outer surface of the lamina and yellow ligament and bipolar coagulation is used for hemostasis when required. Muscle pieces are kept in sterile solution till end of operation as it may be required for sealing the dura in case of an unintended durotomy. A special working insert of the Endospine® set is then introduced through the operating tube, locked in place and a 4 mm Hopkins zero-degree endoscope is introduced into its specific channel in the working insert. The remaining two working channels include one for introduction of a suction tube and the other for endoscopic surgical instruments.

Once the endoscope has been introduced, it is important to conduct at first an endoscopic survey of the regional anatomy for orientation, identification and confirmation of adequate exposure of anatomical structures including the

medial spine, ligament flavum, lower border of upper lamina, upper border of lower lamina, facet joint laterally, medial side of intervertebral foramen and to determine the varying relation between all of these structures is each individual patient. Pressing with the elevator, and fluoroscopic verification of the position of the working insert, could be helpful at this stage (Figure 3).

Depending on anatomical conditions, generally a small widening of previous laminotomy with a Kerrison rongeur required to adequately access the disc space. The inferior edge of the superior lamina is identified and fenestration is started beginning with the medial part of the upper lamina at its junction with the spinous process. A little extra bone shaving might be needed, depending on variant individual anatomy and the position of a migrated disc if present. A Partial caudal laminotomy can be carried on and medial portion articular process can be resected depending on anatomic osseous diameter of the inter-lumbar window and the level operated upon.

The bony resection facilitates access to the herniated lumbar disc without excessive retraction of the nerve root. The special endoscopic bipolar forceps and/or a special ball-tip probe for application of bone wax to any bleeders from the bone are used as needed. The intra-spinal canal is thus accessed and the lateral lumbar gutter, dural sheath, and lumbar nerve root are exposed and identified with aid of simple dissection and manipulation.

Once identified, the nerve root is further exposed with gentle epidural dissection. The nerve root is mobilized using an elevator and then it is retracted medially with the nerve root retractor, which is firmly connected to the working insert. Alternatively, two cottonoid patties (2x2 cm) could be used to dissect and push the nerve inferiorly and the dura above in a similar fashion to microsurgery. The surgeon should not attempt to explore the herniated disc before the most lateral aspect of the vertebral canal is exposed. If necessary, the root could also be explored in its axilla with a modified elevator. The discectomy is then performed with a spoon forceps in a standard fashion as in microdiscectomy. After completion of the discectomy, the root and dural sac are explored to check for any residual compression

and/or retained disc fragments and hemostasis is obtained (Figure 4, A,B).

#### **Closure and Postoperative Care:**

Finally, and once adequate disc removal has been completed, hemostasis is obtained and the area is copiously irrigated. A patte cottonoid is placed at the epidural area on top of the removed disc space for additional hemostasis which is withdrawn later on just before skin closure. Finally, the endoscope together with the entire working insert is gradually withdrawn from the operative field and any bleeders from muscle or fascia are noted and cauterized.

The incision is then closed in layers without the use of any drains and a special wound dressing that allows immediate showering of the patient is applied. In case of accidental durotomy, any rootlets that have bulged through the defect are repositioned within the dura and a small piece of muscle is applied over the dural defect and the muscle and fascia closed very tight and the suture line covered with a tight elastic plaster bandage. Following recovery, patients are typically transferred to the surgery ward overnight to be discharged the following day in the majority of patients. Ambulation is encouraged early after complete recovery from anesthesia with no specific restrictions to patient's movement in the following few weeks after discharge provided heavy labor and prolonged sitting are not involved. A mild progressive increase in activity is advised starting the day after the surgery. The patient can typically fully return to usual activities in 10 days to 2 weeks. Non-steroidal anti-inflammatory drugs are prescribed as well as mild analgesics and muscle relaxants as defined by need.

## **Results**

Mean operative time was 97 (Range, 59–155) minutes with a mean blood loss of 57 ml and an approximate hospital stay of 26 hours. There were no new postoperative neurological deficits or major complications. At initial follow-up, according to MMC (3months postoperative) 67% of patients were pain free (26/39) and considered their postoperative status as excellent, 24% as good (9/39), and 8% (3/39) as fair, whereas one patient was unsatisfied. Intraoperatively, there were 3 patients of dural tears, mainly toward the beginning of our study.

Of note also we have seven patients of accidental medial facetectomies due to excess bony work and two patients had an unintended fracture of the base of the spine. These events had been reported in early cases and none of these patients developed instability through our follow-up. Postoperatively, 2 patients had temporary weakness of involved root that resolved on follow-up and three patients had transient postoperative neuralgia.

#### **Clinical Outcome:**

Thirty nine patients were included in follow-up assessments and results of this study, patients that did not meet the criterion of having at least a single follow-up visit at three months postoperatively were excluded. All patients were mobilized very early after recovery from general anesthesia.

There were no serious neurological symptoms such as motor weakness or cauda equina syndrome. Surgical wound pain was generally minimal and well tolerated with mild analgesia. Immediate postoperative outcomes after endoscopic surgery, as defined by MMC, were assessed directly postoperatively and on second postoperative day and were excellent to good in 33 (85%) patients fair in 4 (10%) patients and poor in 2 (5%) who reported no improvement associated with persistent lumbar radicular pain. All latter 6 patients with a fair or poor outcome, of which two patients had accidental dural tears, were treated medically, 4 of which their complaint resolved later on in follow-up suggesting transient lumbar root neuralgia and 2 who still had a fair or poor outcome. Nine patients had transient postoperative dysesthesia, which resolved few days after the operation of which 2 patients had accidental dural tears during the operation. The remaining patient who had a dural tear had a normal uneventful postoperative course.

After 3 months, outcomes were excellent in 26 (67%) patients who noted substantial relief of their leg pain and were discharged home on second postoperative day. The outcome was good in 9 patients (24%) had pain occasionally or the pain was greatly reduced; fair in 3 (8%) who still had occasional pain (Table 2).

After three years and from a total of 24 patients who were followed-up for this period of time, excellent outcomes were achieved in 21/24 patients

(87%) and good in 3/24 patients (13%). Duration of the surgical procedure, which initially reached 2.6 hours in one patient, dropped to a mean of about 97 minutes as it continued to decrease towards the end of the study.

With regards to VAS score, improvement was significant when compared preoperatively to three months follow-up. The mean preoperative VAS score for back pain was 6.3 (Range, 1-10) and for leg pain was 8.3 (Range, 4-10). At 3 months after surgery, the mean VAS for back pain was 1.7 (Range, 1-4), the mean VAS for leg pain was 1.5 (Range, 0-7). Therefore VAS scores for back pain and leg pain revealed statistically significant improvement when they were compared with preoperative values ( $P < 0.05$ ) while there was not much difference of the VAS throughout the follow-up period ( $P > 0.05$ ). Figure 5 shows the preoperative and 1 month, 3 months, 6 months and 2 years postoperative VAS scores. At the last follow-up visit, 35 patients (90%) patients stated that "they would have the surgery again for the same condition, given all things to be considered".

#### **Complications**

There were no serious perioperative complications such as neurological deficit, vascular/visceral injury or cauda equina syndrome in the present series. There was no uncontrolled epidural bleeding or postoperative hematoma. Transient postoperative dysesthesia occurred in 9 patients. One obese patient had delayed wound-healing, in with a seroma that required repeated dressing. One patient had a soft tissue infection, and 2 patients transient urinary retention requiring a post-recovery from general anesthesia single time urinary catheterization. Seven patients had complete medial facetectomies due to excess bony work without significant effect on stability. Only in one of our patients a conversion from endoscopic to standard microscopic open surgical exploration was required.

Intraoperative complications included 3 patients of dural sac tears of which occurred during various stages of initial fenestration and one during root retraction when the surgeon was removing the disc. These were not associated with neural deficits. All tears were repaired endoscopically by overlying small piece of Surgicel® and muscle pieces on the

tear, tight closure and applying postoperative elastic adhesive tight plaster on the suture line. One of these patients did not have any complaints despite injury, the other had mild numbness and hypoesthesia in the distal leg and foot and one had temporary lumbar root neuralgia. These patients were followed-up for around 72 hours of bed rest and had variable symptoms suggestive of intracranial hypotension in first 24 hours postoperatively. No delayed cerebrospinal fluid leaks or pseudomeningoceles developed later on during follow-up. All were completely dry on discharge from hospital.

There was one case of DVT confirmed by clinical symptoms and Duplex ultrasound in a 49 years old female patient that was obese and had lower limb varicosities. The patient was started on anticoagulant therapy (that is, clexane (enoxaparin) and warfarin simultaneously). She took clexane 60mg twice a day subcutaneously until the DVT disappeared and then the clexane was withdrawn. Oral anticoagulant therapy was continued for a period of one month and then 160 mg of aspirin per day for 5 weeks. Additional thromboprophylaxis methods were then used by author in any case with suspicion, risk/history of DVT including elastic pressure stockings,

added elevation of leg below knee and emphasis on short operative time.

There was a single case of second-time recurrent disc prolapse within the follow-up period with recurrence of symptoms at 20 months postoperative. MRI revealed a recurrent disc herniation at the same level with compression of neural structures that subsequently was re-operated upon successfully using the same technique and the patient had relief of radicular symptoms after endoscopic discectomy with no complications and there were no recurrent symptoms afterward during follow-up.

There was one patient that developed postoperative infectious discitis on postoperative day 5. In addition to clinical picture, blood tests showed raised total leukocyte count (TLC), erythrocyte sedimentation rate (ESR) and C-reactive protein CRP. An MRI with contrast was obtained to radiologically confirm and further assess the diagnosis. The patient was treated with intravenous antibiotics bed rest and dorsolumbar belt immobilization for 5 weeks till TLC, ESR and CRP started to decline followed by a further 4 weeks of oral antibiotics. The patient later had occasional back pain but was satisfied with minimal pain after 16 months.

**Table 1.** Demographic Characteristics of 39 Patients

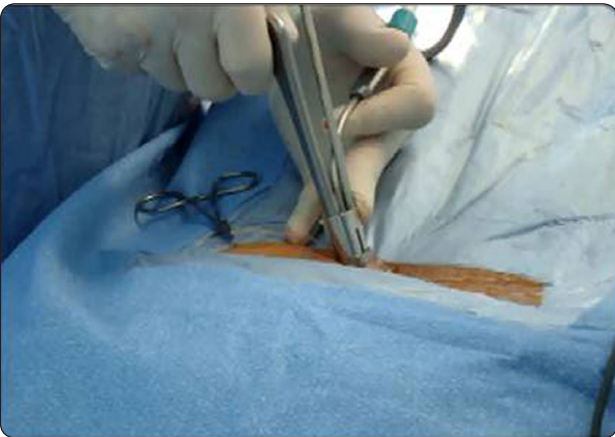Feature	Number
Total number of patients	39
Age (years)	39.7 (29 – 56)
Sex: F:M	1: 1.8
LOS postoperative (days)	1.1 (1 – 3)
Operative time (minutes)	97
Duration of symptoms (months)	11.1 (0.7-48)
Level of Herniation	
L4-5	23 (60%)
L5-S1	15 (38%)
L3-4	1 (2%)
Follow-up period (months)	47.9 (3 – 83)
Disc Side	
Right/left/central	17/19/3
Extruded/Migrated	2

**Table 2.** Clinical Outcomes According to Modified Macnab Criteria at 3 months Postoperative

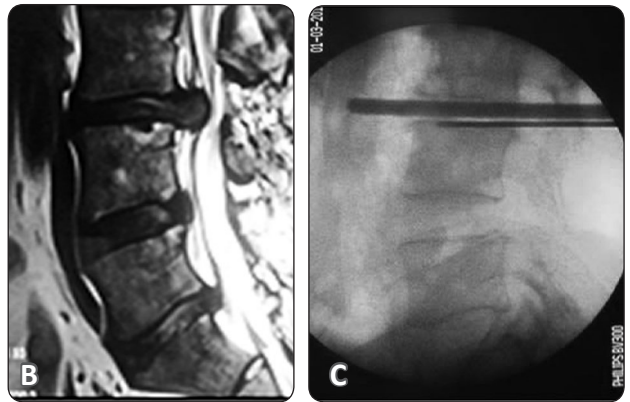
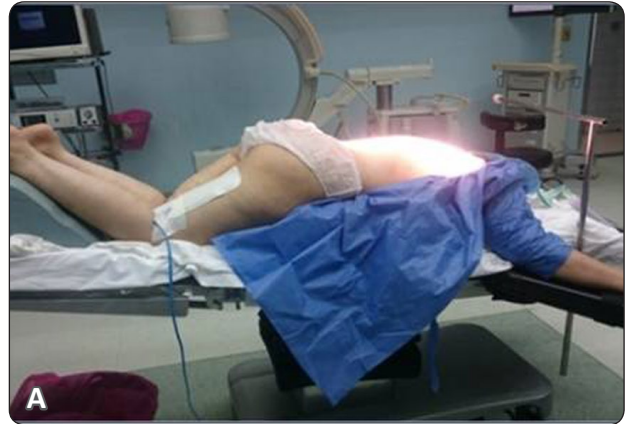Result	Patients No. (%)	Criteria
Excellent	26 (67%)	Free of pain, no restriction of mobility, no discomfort, no neurological signs
Good	9 (24%)	Occasional non-radicular pain, relief of presenting symptoms and signs
Fair	3 (8%)	Partial pain, some relief of presenting symptoms and signs, some improved functional capacity
Poor	1 (<1%)	No pain relief, continued objective symptoms and signs of root involvement



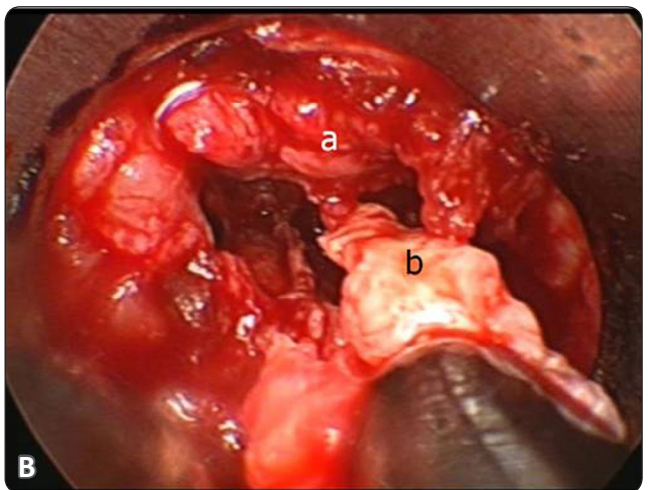
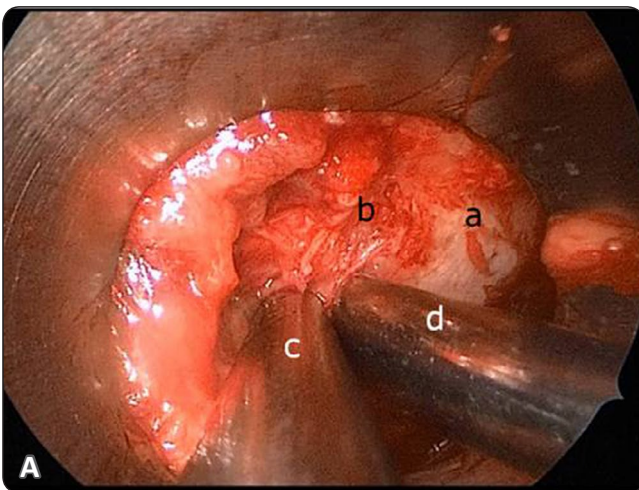
**Figure 1.** Endospine cone-shaped operating tube and working insert showing the three integrated channels with forceps, suction tube and lens in place.



**Figure 3.** Intraoperative photo showing operating tube with the working insert, endoscope, suction tube and a surgical instrument (Kerrison rongeur) in place.

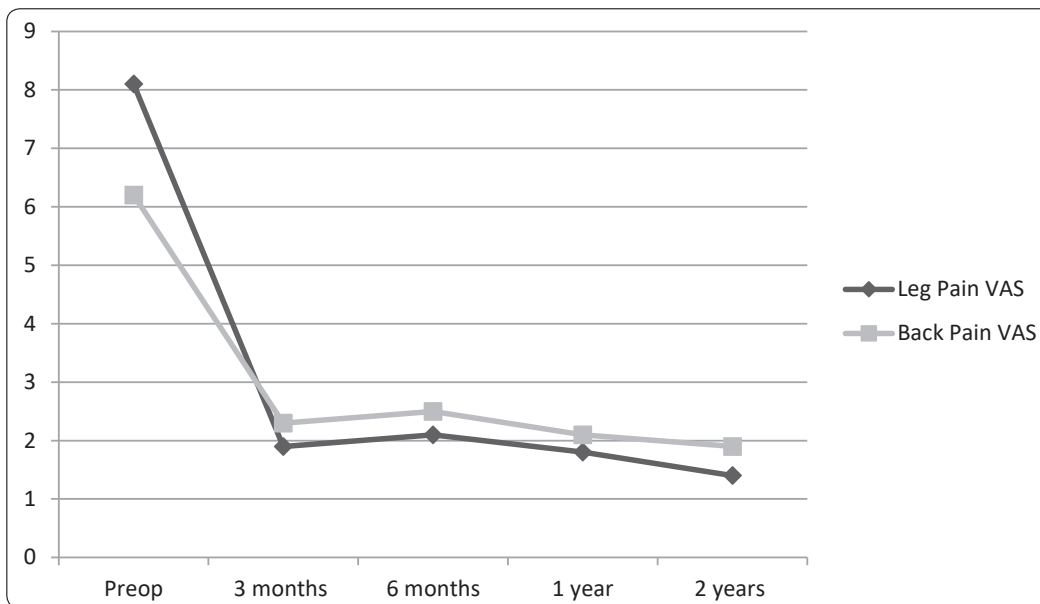


**Figure 2.** Endospine operating tube with forceps, suction tube and lens in place. (A) Patient in prone position for posterior endoscopic discectomy with localizing device in place for an L3-4 discectomy operation (B) MRI imaging showing L3-4 recurrent lumbar disc (C) Lateral fluoroscopic confirmatory image showing the localizing device at the beginning of operation



**Figure 4.** Intraoperative endoscopic view during a right sided recurrent endoscopic lumbar discectomy (A) Endoscopic view showing a. Lamina b. Adhesions c. Suction and d. Dissector (B) Endoscopic view during discectomy showing a. Dural sac b. Recurrence excision.





**Figure 5.**  
Clinical outcome  
by Visual Analogue  
Scale pre and  
postoperatively

## Discussion

Endoscopic techniques are increasingly being used in spine surgery especially after improvements in available endoscopic systems and surgical techniques. It carries the advantages of minimally invasive surgery, reduced tissue traumatic injury and a shortened length of hospital stay. Moreover, other advantages include better illumination, better magnification, better visualization due to close proximity of the telescope to the surgical site, minimal bone resection and epidural fibrosis, better cosmesis, less bleeding and postoperative pain, and early mobilization all leading to a high degree of patient satisfaction.<sup>1,6,7,9,10,12,19,22,26</sup> The Endospine® set, first introduced by Destandau J,<sup>6</sup> in 1999 allows for a relatively high degree of mobility, instruments inserted into the working channel may approach the nerve root at different angles, which considerably increases its application and usefulness. The procedure is an attempt to allow for a standard familiar microsurgical discectomy, which has long been a validated and established, to be performed using similar standard microsurgical techniques via a minimally invasive endoscopic approach that utilizes a zero-degree lens which provides the same perspective at which anatomical structures are viewed in the microsurgical technique.

The steep learning curve especially when first shifting to endoscopic spine surgery is a

consideration and two dimensional vision may cause loss of depth sensation. This is certainly more difficult with recurrent cases due to partial loss of normal anatomy. In order to avoid complications, two published studies (using an endoscope but a different system) advised that 30 patients are needed before the learning curve is passed and basic skills for endoscopic spine surgery acquired.<sup>19,26</sup> It also becomes easier to maintain the optics free of debris, blood or condensation mist which is troublesome at first.

Although the surgical level is first determined before skin incision, the authors particularly at the beginning of the study frequently repeated radiological verification which became a less frequent act with accumulated experience with the procedure. The possibility of rapid, same approach, intraoperative switch to a standard procedure, although was not required in this study, is helpful if problems are encountered. Furthermore, duration of the procedure is increased (especially at the beginning) and there may be difficulties with identification of anatomical structures. These difficulties should resolve with increased numbers of performed procedures.

As reported in numerous studies, microsurgical discectomies for RLDH achieve excellent and good results between 55% and 100%.<sup>1,7,8,12,13,28</sup> Of note, that the large deviation in results can be attributed to the point that, in many of the previous series, patients

with spinal stenosis, epidural scarring, previous full laminectomies, instability, or patients that did not have a pain-free period after primary surgery, were not excluded from the studies. In this study, strict inclusion and exclusion criteria were set to obtain the most focused, technique-related results and outcomes. Nevertheless, in the current study, the clinical results agree with the data in the literature. Initial postoperative good to excellent results were achieved in 85% of patients and was attained in 91% of patients at 3 months postoperative and was maintained through the rest of the follow-up period with no significant difference ( $P>0.05$ ).

On the other side, according to a similar study by Alkoshia et al,<sup>2</sup> for management of patients with RLDH using conventional open discectomy, the early outcome percentage of satisfactory results was 87%, this is also in close proximity to our fore mentioned results. In another study by Fu et al,<sup>11</sup> also using traditional open discectomy for RLDH on 41 patients, clinical outcome was excellent or good in 78.3% of patients. In addition, microsurgical discectomy results were also comparable to those from the current study. Cinotti et al,<sup>5</sup> reported an 85% satisfactory outcome in redo surgeries for RLDH, while Ebeling et al,<sup>8</sup> in a study on 92 patients reported a slightly lower percentage of 81% of patients that were treated successfully. Whereas, Palma et al,<sup>20</sup> in a study on 95 patients had excellent/good outcomes in as high as 89% of their patients.

Results achieved in the present study, in which initial good to excellent outcome was noted in 91% of patients based on MMC are comparable to those reported for in other studies using the same technique of interlaminar MED. In a study on 25 patients excellent and good results were attained in as high as 96% of patients.<sup>12</sup> In a smaller study by Le et al,<sup>14</sup> on 10 patients the outcomes were excellent or good in 90% of patients during a mean follow-up period of 18.5 months. Smith et al,<sup>23</sup> reported a lower percentage of good and excellent outcomes in 80% of their patients. They also reported other measures that improved significantly, including mean VAS for leg pain (8.2 to 2.2,  $P<0.001$ ). This is similar to our study in which the mean preoperative VAS for leg pain was 8.3 (Range, 4-10) and at 3 months after surgery was 1.5 (Range, 0-7).

The number of complications in the current series of patients did not differ significantly from published complication rates for classic microdiscectomy for RLDH. For instance, Palma et al,<sup>20</sup> in their experience in 95 patients, reported 4 patients of dural lacerations; and in the current series of 39 patients there were 3 such complications. In a similar microendoscopic series of 25 patients by Hou et al,<sup>12</sup> they reported 3 minor dural tears and in 2/16 in the series reported by Smith et al,<sup>23</sup> Of note that variable incidences of incorrect level were reported with interlaminar MED for RLDH, in this series four times a mistake regarding incorrect level of the operation was easily corrected during the procedure because of repeated radiological verification.

## Conclusion

Recurrent lumbar disc herniation can be treated safely and adequately with posterior interlaminar MED despite partial loss of anatomy. The technique is associated with satisfactory clinical results as well as short hospital stay. It provides adequate visualization and decompression of the involved nerve root.

## References

1. Albayrak S, Ozturk S, Durdag E, Ayden O: Surgical management of recurrent disc herniations with microdiscectomy and longterm results on life quality: Detailed analysis of 70 cases. *J Neurosci Rural Pract* 7:87-90, 2016
2. Alkoshia HM, Zidan AS: Early Outcome of Sciatica after Redo Surgeries for Recurrent Lumbar Disc Herniation. *Egyptian Spine Journal* 9:19-26, 2014
3. Andersson GB, Brown MD, Dvorak J, Herzog RJ, Kambin P, Malter A, et al: Consensus summary on the diagnosis and treatment of lumbar disc herniation. *Spine* 21:75-78, 1996
4. Berjano P, Pejrona M, Damilano M: Microdiscectomy for recurrent L5-S1 disc herniation. *Eur Spine J* 22:2915-2917, 2013
5. Cinotti G, Roysam GS, Eisenstein SM, Postacchini F: Ipsilateral recurrent lumbar disc herniation, *J Bone Joint Surg (Br)* 80-B:825-32, 1998

6. Destandau J: A special device for endoscopic surgery of lumbar disc herniation. *Neurol Res* 21:39-42, 1999
7. Drazin D, Ugiliweneza B, Al-Khouja L, Yang D, Johnson P, Kim, T, et al: Treatment of Recurrent Disc Herniation: A Systematic Review. *Cureus* 8(5), e622, 2016
8. Ebeling U, Kalbarczyk H, Reulen HJ: Microsurgical reoperation following lumbar disc surgery. Timing, surgical findings, and outcome in 92 patients. *J Neurosurg* 70:397-404, 1989
9. Elwany A, Farhoud A, Zidan I, Khedr W: Three-year Follow-Up Results of Lumbar Microendoscopic Discectomy (MED): A Prospective Study in 150 Patients. *Egyptian Spine Journal* 24:14-24, 2017
10. Foley KT, Smith MM: Microendoscopic discectomy. *Tech Neurosurg* 3:301-307, 1997
11. Fu TS, Lai PL, Tsai TT, Niu CC, Chen LH, Chen WJ: Long-term results of disc excision for recurrent lumbar disc herniation with or without posterolateral fusion. *Spine (Phila Pa 1976)* 30:2830-2834, 2005
12. Hou T, Zhou Q, Dai F, Luo F, He Q, Zhang J, et al: Repeated microendoscopic discectomy for recurrent lumbar disk herniation. *Clinics* 70(2):120-125, 2015
13. Krutko AV, Baykov ES, Sadovoy MA: Reoperation after microdiscectomy of Lumbar herniation: Case report and Treatment Outcomes in 42 Patients. *International Journal of Surgery Case Reports* 24:119-123, 2016
14. Le H, Sandhu FA, Fessler RG: Clinical outcomes after minimal-access surgery for recurrent lumbar disc herniation. *Neurosurg Focus* 15: E12, 2003
15. Lequin MB, Verbaan D, Bouma GJ: Posterior lumbar interbody fusion with stand-alone Trabecular Metal cages for repeatedly RLDH and back pain. *J Neurosurg Spine* 20:617-622, 2014
16. Macnab I: Negative disc exploration. An analysis of the causes of nerve-root involvement in sixty-eight patients. *J Bone Joint Surg Am* 53:891-903, 1971
17. McCulloch JA: Focus issue on lumbar disc herniation: macro and microdiscectomy. *Spine* 21 (24 Suppl):45-56, 1996
18. Mroz TE, Lubelski D, Williams SK, O'Rourke C, Obuchowski NA, Wang JC, et al: Differences in the surgical treatment of RLDH among spine surgeons in the United States. *Spine J* 14:2334-2343, 2014
19. Nowitzke A: Assessment of the learning curve for Lumbar Microendoscopic Discectomy. *Neurosurgery* 56:755-62, 2005
20. Palma L, Carangelo B, Muzii VF, Mariottini A, Zalaffi A, Capitani S: Microsurgery for recurrent lumbar disk herniation at the same level and side: do patients fare worse? Experience with 95 consecutive cases. *Surgical Neurology* 70(6):619-621, 2008
21. Perez-Cruet MJ, Foley KT, Isaacs RE, Rice-Wyllie L, Wellington R, Smith MM et al: Microendoscopic lumbar discectomy: technical note. *Neurosurgery* 51(5 Suppl):S129-36, 2002
22. Shin KH, Chang HG, Rhee NK, Lim KS: Revisional percutaneous full endoscopic disc surgery for recurrent herniation of previous open lumbar discectomy. *Asian Spine J* 5:1-9, 2011
23. Smith JS, Ogden AT, Shafizadeh S, Fessler RG: Clinical outcomes after microendoscopic discectomy for recurrent lumbar disc herniation. *J Spinal Disord Tech* 23(1):30-34, 2010
24. Sonmez E, Coven I, Sahinturk F, Yilmaz C, Caner H: Unilateral percutaneous pedicle screw instrumentation with minimally invasive TLIF for the treatment of recurrent lumbar disk disease: 2 years follow-up. *Turk Neurosurg* 23(3):372-378, 2013
25. Swartz KR, Trost GR: Recurrent lumbar disc herniation. *Neurosurg Focus* 15(3):E10, 2003
26. Wang B, Lu G, Patel AA, Ren P, Cheng I: An evaluation of the learning curve for a complex surgical technique: the full endoscopic interlaminar approach for lumbar disc herniations. *Spine J* 11:122-30, 2011
27. Wang JC, Dailey AT, Mummaneni PV, Ghogawala Z, Resnick DK, Watters WC et al: Guideline update for the performance of fusion procedures for degenerative disease of the lumbar spine. Part 8: lumbar fusion for disc herniation and radiculopathy. *J Neurosurg Spine* 21:48-53, 2014
28. Zhou Y, Wang J, Chu TW, Li CQ, Zhang ZF, Wang WD, et al: Micro-endoscopic strategies and options for recurrent lumbar disc herniation. *Zhonghua Wai Ke Za Zhi* 46:1475-9, 2008

## المخلص العربي

### إستئصال الإنزلاق الغضروفي القطني المرتجع بالمنظار من الخلف: سلسلة من 39 حالة

**البيانات الخلفية:** جراحة العمود الفقري بالمنظار تلقي إهتمام متزايد من قبل جراحي المخ والأعصاب وجراحي العمود الفقري في مناطق كثيرة من العالم بسبب النتائج الإيجابية والحد الأدنى من الغزو لأنسجة الجسم لكونها جراحة محدودة التدخل. في هذه الدراسة الباحث يشارك المقال يشارك خبرته الأولية على مدى سبع سنوات مع هذه التقنية أو الأسلوب الجراحي، والنتائج التي تحققت مع استئصال القرص الغضروفي القطني المرتجع بالمنظار من الخلف.

**الغرض:** الغرض من الدراسة هو تقديم نتائج العمليات الجراحية التي قمنا بها وتقييم هذه النتائج التي توصلنا إليها بالنسبة لإستئصال الإنزلاق الغضروفي المرتجع من بين الصفائح القطنية الخلفية بإستخدام المنظار الجراحي العصبي، بالإضافة إلى مناقشة مزايا وجدوى هذه الجراحات.

**تصميم الدراسة:** دراسة لحالات إكلينيكية بأثر رجعي

**المرضى والطرق:** في الفترة ما بين مايو 2009 ويوليو 2016، خضع 39 مريض على التوالي ممن يعانون من أعراض الإنزلاق الغضروفي القطني المرتجع لعملية إستئصال الغضروف القطني المنزلق بالمنظار، (متوسط عمر المرضى كان 39.7 سنة) وكانت فترة المتابعة الإجمالية للمرضى هي 7 سنوات (متوسط فترة المتابعة: 47.9 أشهر). وتم تقييم نتائج المرضى ومراجعتها وتقييمها من حيث حجم الألم قبل وبعد الجراحة بأستخدام مقياس التماثلية البصرية (VAS) Visual Analogue Scal ومعايير ماكناب المعدلة (MMC) Modified Macnab Criteria.

**النتائج:** كان متوسط الوقت الذي تستغرقه العملية 97 دقيقة. لم يكن هناك حدوث لعجز عصبي جديد أو مضاعفات كبيرة بعد العملية الجراحية خلال هذه الدراسة. في المتابعة الأولية، ووفقا للمقاييس المستخدمة في الدراسة 67% من المرضى (39/26) اعتبروا أو وصفوا حالتهم بعد العملية الجراحية بأنها ممتازة بالنسبة لتحسن الألم ، 24% بأنها جيدة (39/9)، و8% (39/3) بأنها معتدلة/معقولة، في حين أن مريض واحد كان غير راض عن نتيجة العملية. أما عن التعقيدات أثناء العملية فكانت هناك 3 حالات من القطع غير المتعمد للغشاء السحائي، وذلك كان في الأكثر نحو بداية دراستنا وسبع حالات من إزالة غير متعمدة للمفصل الداخلي ما بين الفقرات جراء أعمال عظمية زائدة بالإضافة لبعض المضاعفات المتفرقة الأخرى المذكورة بالدراسة.

**الإستنتاج:** يمكن علاج الإنزلاق الغضروفي القطني المرتجع ما بين الفقرات القطنية عند المستويات القطنية السفلى بشكل جيد وكاف بأستخدام المنظار. ويرتبط هذا الأسلوب الجراحي ذو التدخل المحدود بتحسن ملحوظ في الأعراض كآلام الظهر والأطراف السفلى، بالإضافة إلى قضاء مدة قصيرة في المستشفى وغيرها من الفوائد المرتبطة بالجراحات ذات التدخل المحدود. وعلى الرغم من أن منحنى التعلم يشمل فترة تدريب إنتقالية ضرورية قبل التمكن من هذه التقنية الحديثة نسبيا، كما ان حالات الإنزلاق الغضروفي القطني المرتجع تكون بطبيعة الحال اصعب على الجراح من الجراحة الأولى نظرا للغياب الجزئي للبناء التشريحي الطبيعي للفقرات والأنسجة المحيطة بها، إلا أن المنظار كان في العام وسيلة آمنة وفعالة في إجراء هذه الجراحة وسمح بقدر كافي من الحركة الضرورية داخل جسم المريض في المنطقة المستهدفة جراحيا بالإضافة إلى مستوى الرؤيا العالي الدقة والوضوح.